

Primary Flexor Tendon Repair in Zone II. Update and Surgical Technique

Violeta D. Levy

Hand and Upper Limb Surgery Unit, Orthopedics and Traumatology Service, Hospital Español de Buenos Aires, Argentina

ABSTRACT

Primary flexor tendon repair in zone II has been a challenge since the emergence of hand surgery as a specialty after World War II. From Bunnell to today, the way of operating and rehabilitating these tendons has evolved and changed considerably thanks to anatomical, biological and—above all—mechanical studies. Currently, the surgical technique is based on performing a strong and neat suture, which does not suffer friction within the sheath and which tolerates the load necessary for the active motion of the finger without resistance. Multiple suture configurations with different materials have been described. Under local anesthesia, the intraoperative active flexion-extension test reveals the resistance of the type of suture chosen and has gained importance in defining the rehabilitation protocol. Treatment of flexors in zone II is, so far, an inseparable set of surgical technique and a suitable rehabilitation protocol. Biological strategies to enhance the tendon healing process are currently the main field of research.

Keywords: Flexor tendon; primary repair; zone II.

Reparación primaria de los flexores en la zona II. Actualización y técnica quirúrgica

RESUMEN

La reparación primaria de los tendones flexores en la zona II ha sido un desafío desde el surgimiento de la cirugía de la mano como especialidad luego de la Segunda Guerra Mundial. Desde Bunnell hasta hoy, la forma de operar y rehabilitar estos tendones ha evolucionado y cambiado considerablemente gracias a estudios anatómicos, biológicos y, sobre todo, mecánicos. Actualmente la técnica quirúrgica se basa en realizar una sutura fuerte y prolija, que no sufra fricción dentro de la vaina y que tolere la carga necesaria para la movilidad activa del dígito sin resistencia. Se han descrito múltiples configuraciones de puntos con diferentes materiales. Operando con anestesia local, la prueba de flexo-extensión activa intraoperatoria revela la resistencia del tipo de sutura elegida y ha cobrado importancia para definir el protocolo de rehabilitación. El tratamiento de los flexores en la zona II es, hasta el momento, un conjunto inseparable de técnica quirúrgica y rehabilitación asociada. La manipulación farmacológica del proceso biológico reparador es el principal campo de investigación actual.

Palabras clave: Flexores; reparación primaria; zona II.

INTRODUCTION

Tendon injuries are not common, they have an incidence of 4.8 per 100,000 inhabitants.¹ Nevertheless, their repair is one of the most important topics in Hand Surgery. The objective of this article is to describe and substantiate the surgical technique that I use to treat flexor injuries in zone II, since, in the last 30 years, there have been changes both in the types of repairs and in the treatment of the sheath and associated rehabilitation protocols. On the other hand, the increasing knowledge of tendon biology has promoted new fields of research for future advances that I will briefly describe.

INDICATIONS AND CONTRAINDICATIONS

Primary flexor repair in zone II is indicated whenever possible. This is not an emergency, unless there is devascularization of the affected finger or fingers. It is critical that a specialist is available in the emergency department. Given the amount of technical details and the availability of specific instruments and materials required, it is preferable, if there is no specialist, to clean, suture the skin and refer the patient for a deferred primary suture that is indicated for up to 21 days after the trauma with the same results (Figure 1).

Received on April 20th, 2021. Accepted after evaluation on May 8th, 2021 • Dr. VIOLETA D. LEVY • vdlevy@gmail.com  <https://orcid.org/0000-0003-1822-673X>

How to cite this article: Levy VD. Primary Flexor Tendon Repair in Zone II. Update and Surgical Technique. *Rev Asoc Argent Ortop Traumatol* 2021;86(5):681-695. <https://doi.org/10.15417/issn.1852-7434.2021.86.5.1356>

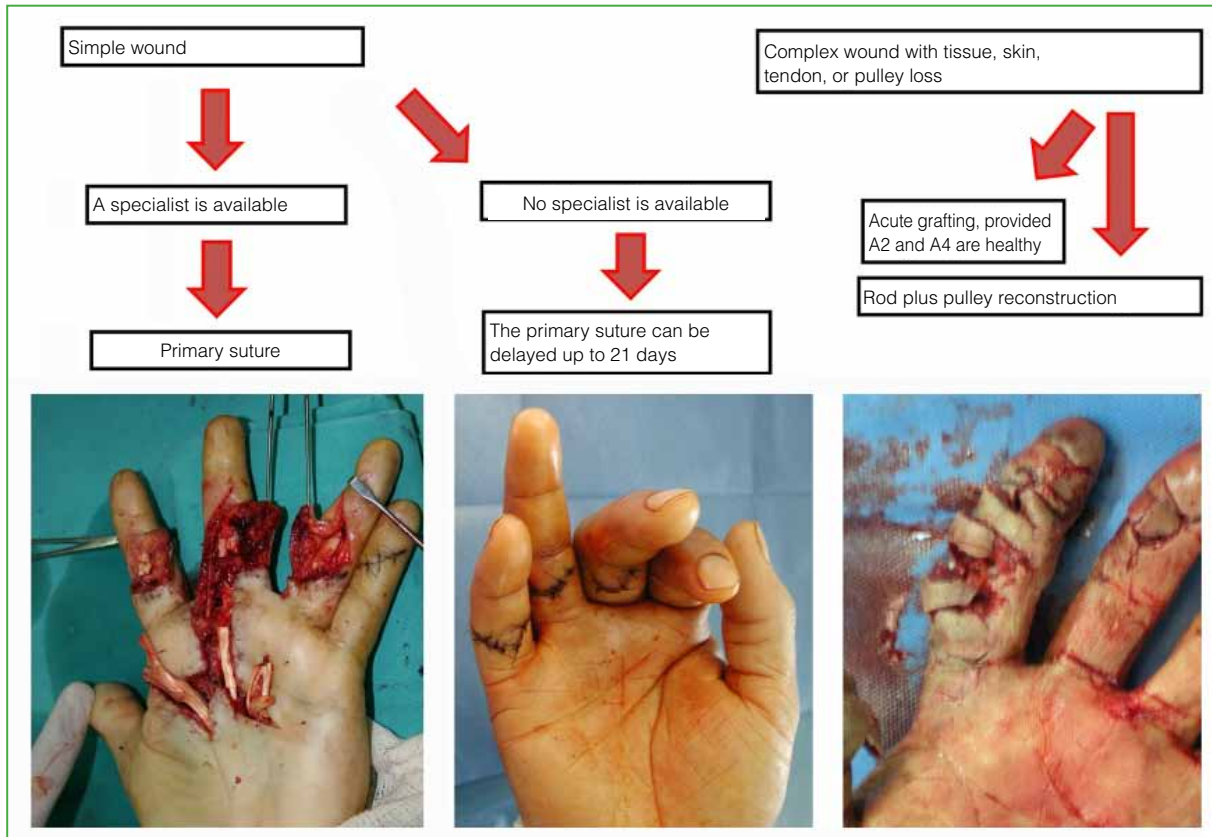


Figure 1. Treatment algorithm.

The wounds can be described as simple (skin, flexors, and even a neurovascular bundle) or complex (loss of tissue, association of severe injury to the skin or to both bundles, extended sheath, or phalangeal fractures). If the wound is complex, the priority is revascularization accompanied by nerve repair. Also, other procedures will have to be carried out in addition to tenorrhaphy, such as bone stabilizations or skin flaps, as appropriate. If the complex injury presents substantial damage to the flexor sheath, it is preferable to place a Silastic rod, reconstruct pulleys, and schedule a second procedure for grafting at 3-6 months (Figure 2). Although it rarely happens, the most important pulleys may be healthy while the flexors lack tissue, in which case a flexor graft could be placed in the first surgery.

Primary flexor repair in complex wounds is not contraindicated but requires firm bone stabilizations, tension-free vascular and nerve sutures, and good skin coverage to enter early rehabilitation protocols. If this is not possible, the patient must be warned about the possibility of future interventions for eventual tenolysis or secondary reconstructions.

SURGICAL ANATOMY

Basic concepts

Verdan's zone II extends from the distal palmar crease almost to the distal interphalangeal crease. It contains the flexor digitorum superficialis (FDS), flexor digitorum profundus (FDP), synovial sheath, pulley system, phalanges, and neurovascular bundles. The FDP, which inserts at the base of the third phalanx, and the FDS, which inserts through two bands on the volar surface of the second phalanx, intersect at Camper's chiasm that begins in the middle of the first phalanx and ends in the middle of the second.²

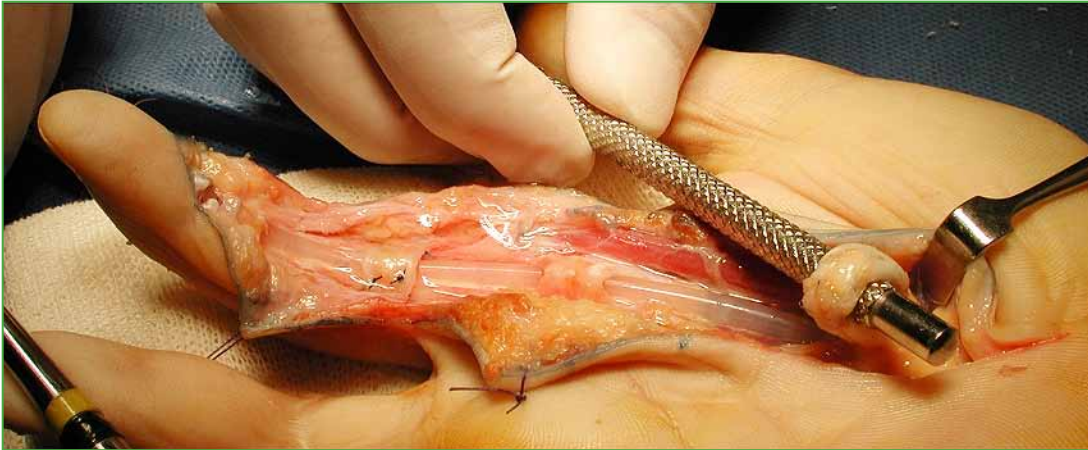

Figure 2. In complex wounds with destruction of the sheath: rod placement and reconstruction of A2 and A4 pulleys. Loop between superficial and deep flexor (Paneva-Holevich).

The sheaths have a parietal and a visceral layer and contain synovial fluid. Those of the second, third, and fourth fingers reach the distal palmar crease and end in a cul-de-sac. The thumb or radial sheath reaches the wrist. The ulnar sheath, also called the common flexor sheath, covers the flexors of the fourth finger and, at the level of the carpal tunnel, also encompasses the flexors of the fifth, third, and second fingers, ending at the level of the wrist.³ The palmar region of the central flexors (zone III) is extrasynovial and is covered by connective tissue called the paratenon. In the finger zone itself, an osteofibrous tunnel is formed, reinforced by pulleys made of thickened dense connective tissue; they are segmentally distributed along the fingers and their function is to maximize the mechanical efficiency of the tendon excursion. There are five annular pulleys and three cruciform pulleys.^{4,5} Pulleys A2 and A4 are the most important from the mechanical point of view (Figure 3).

The flexor tendons are nourished through the musculotendinous junction, the osteotendinous junction, the paratenon in the extrasynovial portion, the vincula, and by diffusion in the intrasynovial portion. The vincula are bands that contain vessels and run from the osseous base of the digital tunnel to the dorsal aspect of the flexors. For each flexor, there is a short (brevis) and long (longus) vinculum (Figure 3).⁶

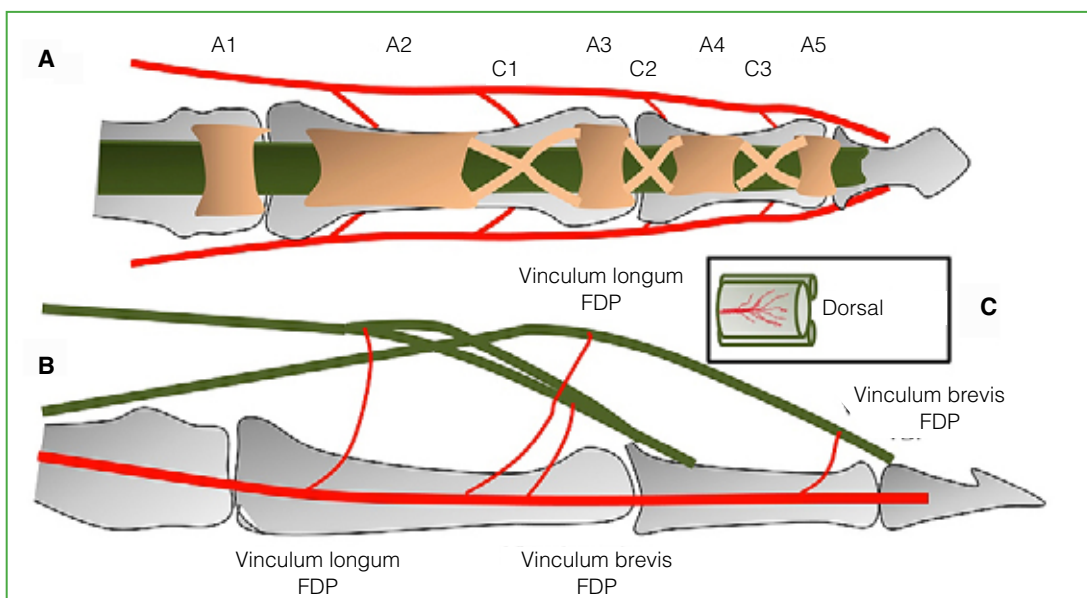


Figure 3. A. Pulley system. B. Vincula. C. Vincula passing through the dorsal aspect of the flexor. FDS = flexor digitorum superficialis, FDP = flexor digitorum profundus

Tendon repair biology

The extracellular matrix is the main component of the tendon and is made up of type I collagen and proteoglycans synthesized by the tenocytes immersed in said matrix.⁷ Undifferentiated cells are found in the epitenon and mature as they become trapped in the matrix, progressively decreasing their metabolism.⁸ There are three phases of tendon repair: the first, inflammatory one that lasts between one and five days, the proliferative one that lasts four weeks, and the remodeling one that lasts about four months.⁹ The undifferentiated cells of the epitenon are responsible for the proliferative phase and are directed towards the interior of the tendon, repairing it, and towards the outside, causing adhesions. The success of the repair depends on the ability to recruit these cells to the site of injury. Said recruitment is favored by the presence of cytokines or growth factors that arrive through the vessels. The pharmacological manipulation of this process is the subject of current research.

Biomechanics

Historically, repairs in zone II failed, which is why Bunnell called it “no man’s land.”¹⁰ It was only in the 1960s, with the studies of Verdan,¹¹ Kleinert et al.,¹² and Kessler and Nissim¹³ that repairs, accompanied by early mobilization protocols, started yielding with good outcomes. The fundamentals of flexor repair were well described by Strickland:¹⁴ easy-to-perform, neat sutures that do not interfere with tendon vascularization, and strong enough to allow early mobilization. Tang et al.¹⁵ described three mechanical factors that influence the outcome of a primary suture in zone II: friction, load, and mobility. Friction is the glide resistance between the repaired tendon and its sheath; it is desirable for it to be minimal (the tendon must glide smoothly) and, if needed, it is preferable to open pulleys to avoid it. The sheath was typically kept closed to preserve a barrier that prevented adhesions, to restore synovial nutrition, to preserve a guide for tendon remodeling, and to prevent bowstringing. However, Tang’s studies show that avoiding friction is more important. If the rest of the sheath is healthy, up to two-thirds of A2 and all of A4 can be left open without bowstring being produced. Friction at the A2 level can also be relieved by resecting one of the flexor digitorum superficialis insertion bands.¹⁶ The load is the minimum force necessary to move the finger joints and overcome friction (work of flexion) that, according to experimental studies, is 35 N. Therefore, the type of suture chosen must withstand around 40 N to perform the work of flexion from the beginning. Mobility is essential, as it prevents adhesions and helps to regain tensile strength.

The result of the suture performed should be tested with the patient awake to observe if there is friction or separation of the ends (gapping) during active flexion-extension on the operating table (digital extension-flexion test, DEFT).¹⁷ The method described by Lalonde of local anesthesia with epinephrine and without hemostatic tourniquet (Wide Awake Local Anesthesia no Tourniquet, WALANT) is the ideal one to carry out this test.¹⁸

Suture types and materials

During the first 10 days after tenorrhaphy, the entire resistance of the repair depends exclusively on the material and type of suture; for this reason, they have been extensively studied. The general consensus is to make a central stitch and a running peripheral suture, both can have different configurations. The central stitch can be conventional (2 threads) or multiple (4, 6, or 8 threads) (Figure 4), the grasping can be unlocked or locked (Figure 5). The running peripheral suture can be simple or locking. In terms of materials, the vast majority use nylon or Prolene® 3 or 4-0. During the last decade, the use of FiberWire® 4-0, which is a more resistant multifilament polyethylene, but which glides with greater difficulty, began to be used.¹⁹ Currently, both nylon and FiberWire® sutures are marketed, including looped double strands (with a single needle incorporated). When using them, two strands are left with each pass, simplifying the procedure and avoiding excessive manipulation of the tendon strands (Figure 4).²⁰ Other devices are being tested, such as the Teno Fix®, which is a stainless steel wire with harpoons at the ends, more resistant, but more rigid, and the barbed sutures that, according to some articles, would present the same resistance as a four-strand suture.^{21,22} The main criticism of these systems, especially the Teno Fix®, is that they produce some bulge in the tendon that could increase friction. The ideal suture is one that does not cause friction (little bulging) and resists, at least, 40 N of force to be able to carry out early active mobility. The factors that help to improve resistance can be observed in Table 1.

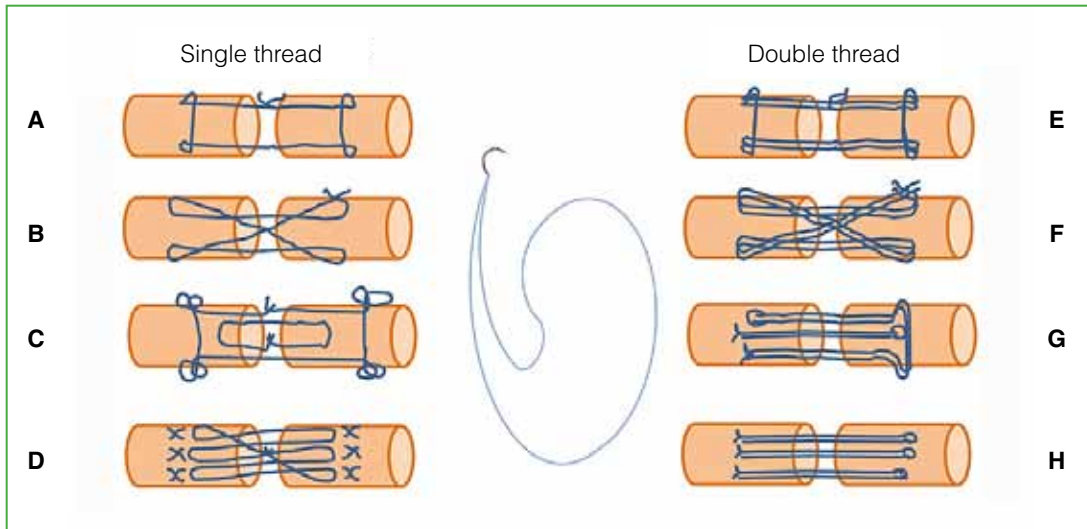


Figure 4. Central stitch disposition. With a single thread: **A.** Modified Kessler (2 strands). **B.** Adelaide cross repair (4 strands). **C.** Strickland (4 strands). **D.** Savage (6 strands). With double thread: **E.** Modified Kessler (4 strands). **F.** Cross repair (8 strands). **G.** M Tang (6 strands). **H.** Triple running suture (6 strands).

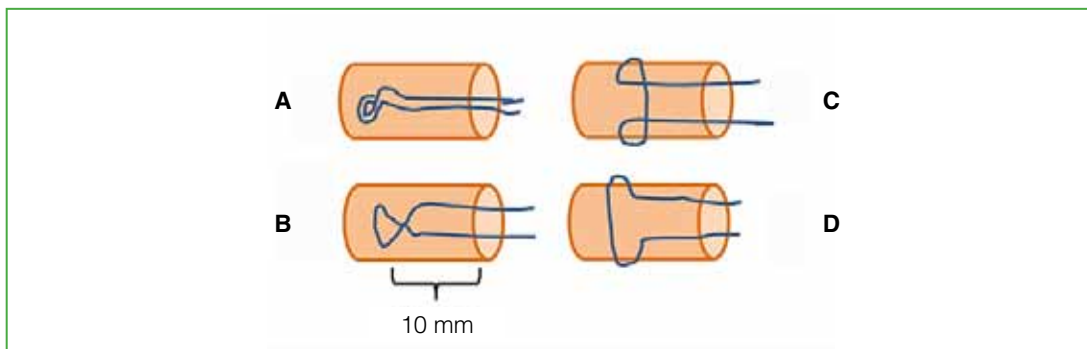


Figure 5. Types of grasps. **A.** Loop. **B.** Crossed. **C.** Pennington. **D.** Unlocked. The optimal distance between the grasp and the edge of the end is 10 mm.

Table 1. Factors that improve suture strength

Factors that improve central stitch resistance	Factors that improve running suture resistance
4 or more threads, 1 cm long, between the grasp and the end	6 to 8 stitches
At least 4 locked grasps.	Running locking suture
Tension that brings the ends closer together without bulging them (shorten it by 10%)	Taking 1 or 2 mm of tendon
Nylon or Prolene® 3 or 4-0 FiberWire® 4-0	Nylon 5 or 6-0

Postoperative and rehabilitation protocols

Treatment of flexors in zone II is, so far, an inseparable set of surgical technique and associated rehabilitation. Mobility produces a rapid recovery of tensile strength, fewer adhesions and better tendon excursion. Passive flexion and active extension can be performed (Duran,²³ and Kleinert et al.¹²), this produces a certain curl of the tendon within the sheath,²⁴ as well as the movement called place and hold (Silversköld²⁵ and Strickland²⁶). Finally, non-resisted active flexion can be carried out from the fourth day, adapting the load to the stage of repair. During the first two weeks, it is not desirable for active flexion to be $>50^\circ$ at the proximal interphalangeal joint (Figure 6).²⁷ In all cases, at the end of surgery, a protective dorsal slab should be placed with the wrist in neutral position or slightly flexed, the metacarpophalangeal joints at 45° , and the interphalangeal joints free. When passive elastic band flexion is indicated, a bar or pulley can be added in the palm to optimize the excursion of the FDP.²⁸

It is important to highlight that the choice of the rehabilitation protocol is determined by the type of suture performed and the type of patient. If the running suture is not reliable (does not have 4 strands of at least 3 or 4-0 nylon with 4 grasps), or if the DEFT is not tested, or the patient does not duly comply with the indications, it is not advisable to perform early active mobility (Figure 7).

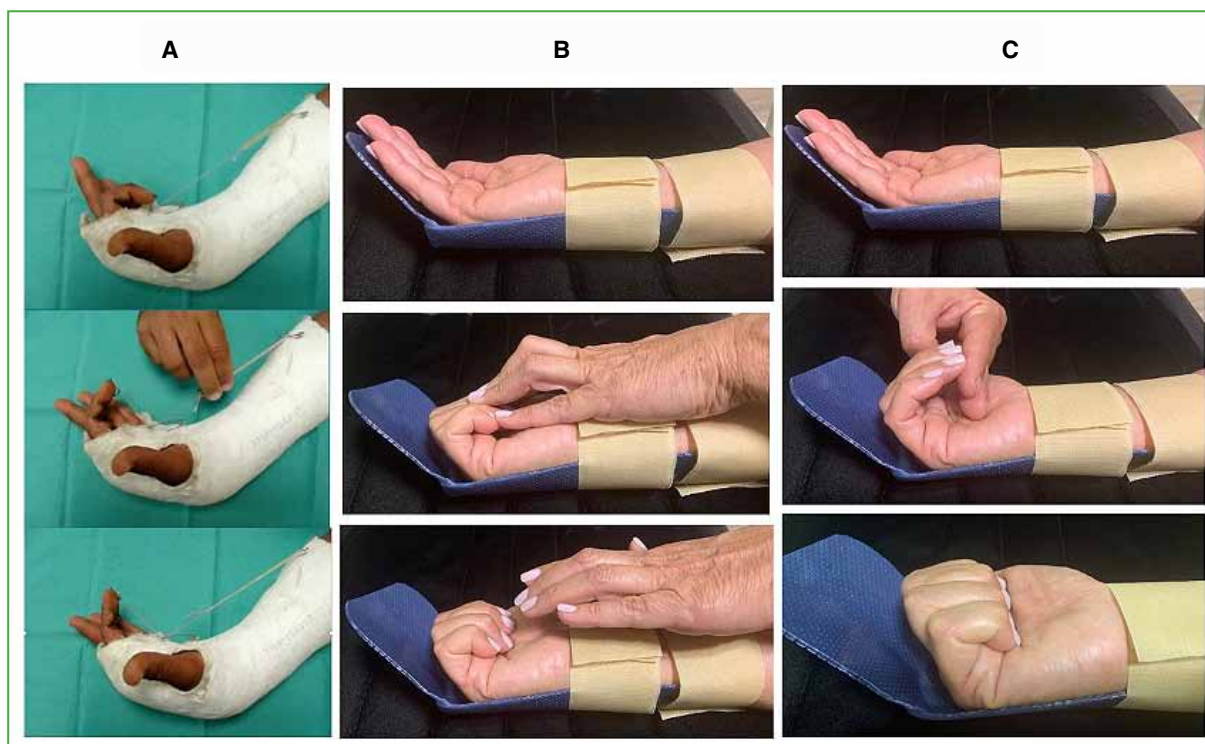


Figure 6. Rehabilitation protocols. **A.** Kleinert: active extension, passive flexion with elastic band. **B.** Strickland: active extension, passive flexion with the healthy hand (Duran) plus active isometric flexion (place and hold). **C.** Tang: controlled non-resisted active flexion. The first 15 days, 2 fingers of the contralateral hand are placed to avoid full flexion.

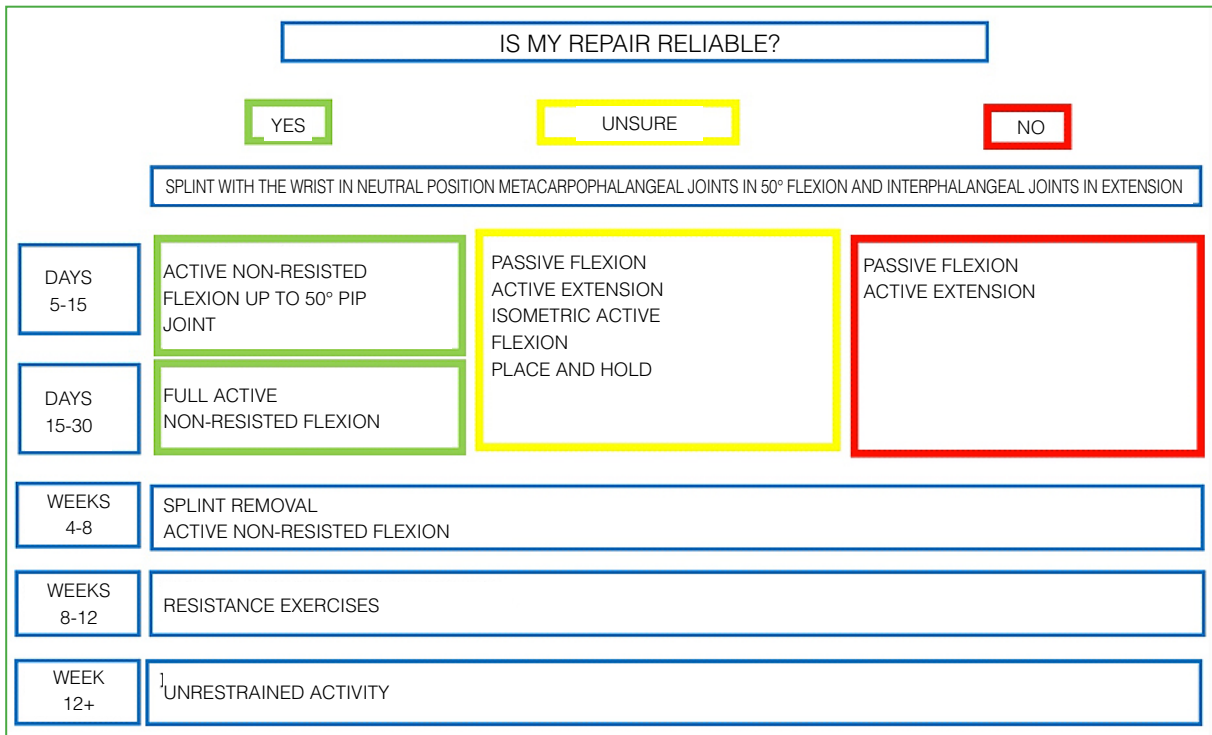


Figure 7. Rehabilitation protocol adjusted to the type of repair.

SURGICAL TECHNIQUE. MY PREFERENCES

For complex wounds, I work with plexus anesthesia and a hemostatic tourniquet. If there is loss of tissue in the flexors without harm in at least A2 and A4, I use the FDS as a graft for the acute reconstruction of the FDP. If the pulley system is badly damaged, I place a rod to reconstruct at least A2 and A4, and I make a loop between the proximal ends of both flexors as described by Paneva-Holevich (Figure 2).²⁹ It is advisable to have rods available in the operating room when treating complex wounds. I rarely do a pulley reconstruction along with the tenorraphy; In these cases, there are usually pulley remnants to suture a graft as a bridge. If possible, I use one of the FDS bands, keeping its distal insertion, to reconstruct A4 and palmaris brevis or FDS as grafts for A2 (Figure 8). If the wound is accompanied by phalangeal fractures, the osteosynthesis should ideally be stable enough to move the finger and not interfere with tendon gliding.

As described in previous paragraphs, during the last 30 years, there have been significant changes in the way of treating flexors; changes that I am currently trying to apply (Table 2).

If the wound is simple, I prefer to operate under local anesthesia with epinephrine and without a cuff, as described by Lalonde. If I understand that the procedure will be easy, I use local anesthesia without epinephrine and hemostatic cuff for 30 min, which gives me time to suture the tendon. Then I release the tourniquet to test the DEFT.

In general, these are transverse or oblique cut wounds; I like to extend them with Bruner or bayonet incisions. It is good practice to lift the flaps with cellular tissue so as not to devascularize them, if the bundles are healthy they are included in them and if any of them is injured I repair it, but I try to dissect them without traumatizing the skin (Figure 9).

Skin flap damage or necrosis is, in my opinion, the worst complication in primary flexor repair, since, in milder cases, it forces us to suspend any rehabilitation protocol with the consequent formation of adhesions and, in severe cases, it can result in necrosis of the repaired tendon, requiring cover flaps and secondary tendon reconstruction in one or two stages.

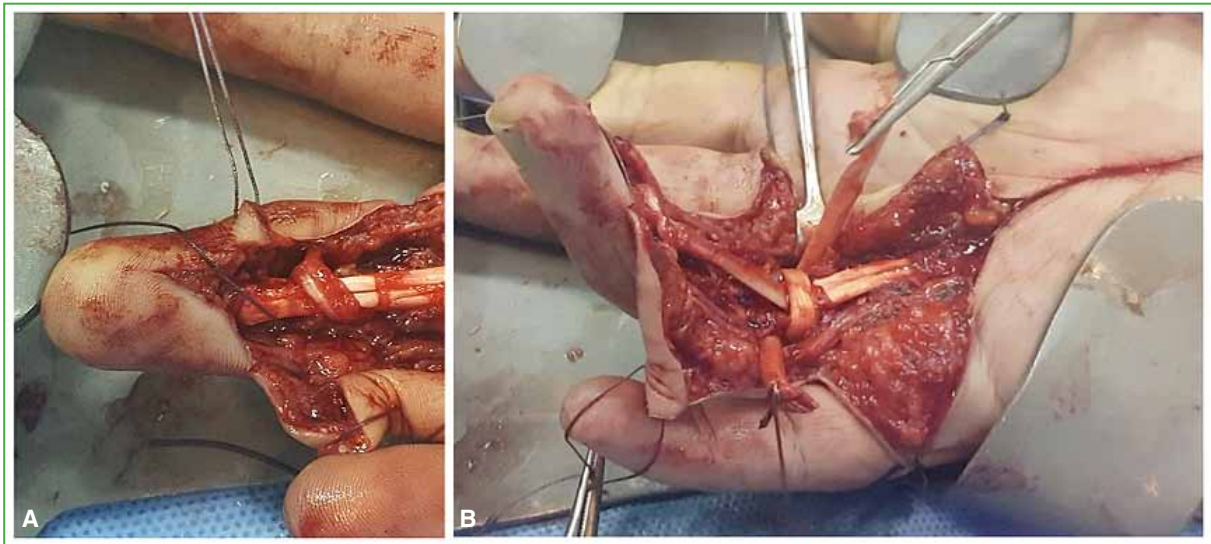


Figure 8. Reconstruction of pulleys. **A.** Reconstruction of A4 with flexor digitorum superficialis band. **B.** Reconstruction of A2 with flexor digitorum superficialis.

Table 2. Significant changes in the last 30 years

	Before	Now
Central stitch	2 strands	4 or more strands
Sheath treatment	Closed sheath	Open sheath
A2 and A4 pulleys	Whole A2 and A4	A2 can be opened up to 2/3 Whole A4
FDS	FDS is always sutured	FDS can be resected to avoid friction
Type of anesthesia	Plexus with tourniquet	WALANT active intraoperative flexion-extension test
Postoperative splint	Wrist flexion splint	Neutral wrist splint, highly selected cases without splint
Rehabilitation protocol	Only passive flexion after 48 h	Controlled active flexion from the 5 th day onwards

Once the sheath is exposed, it is necessary to observe the degree of injury it has. In simple wounds, the pulleys are usually whole. I usually open the sheath at the level of the cut and the nearby cruciform pulleys.

If the vinculum is healthy, the proximal end of the FDP is close to the injury (Figure 10); conversely, it is usually retracted in the palm if the vinculum is broken. On occasions, if the patient was using fist force at the time of the accident, it may be curled proximally, but always tied to the lumbrical (Figure 11). In those cases, I extend the skin incision to the palm. There, I find the proximal end(s) and thread them through the pulleys using a tendon passer or a simple silicone cannula with a nylon stitch. The distal end of the FDP will reach the suture area by flexing the distal interphalangeal joint (Figure 12).

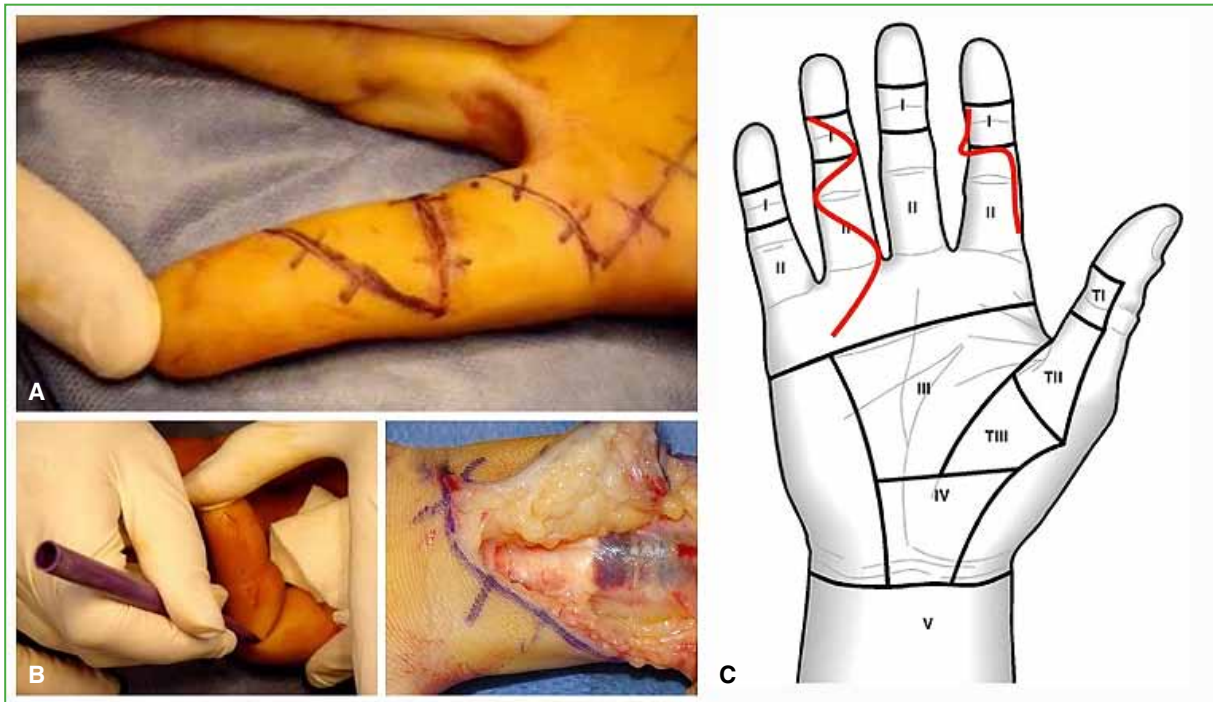


Figure 9. Skin incisions. **A.** Bruner incision. **B.** Break at the lateral limit of the fold. **C.** Raise flaps with subcutaneous cellular tissue to avoid devitalizing them.

Once the proximal ends have been threaded they can be held in place with an intramuscular needle by piercing the tendons and securing them to the sheath (Figures 10, 12, and 13). If the lesion is at the level of the proximal interphalangeal joint, the position of Camper's chiasm must be respected and this may require opening the most distal portion of A2 (it can be resected or simply opened). I suture the FDS lesion in the band area with a 3-0 U-stitch in each (Figure 13). If the FDS is injured in its entire portion, I repair it in the same way as the FDP. For the center stitch I use 3-0 nylon with double thread, I prefer the modified Kessler technique which will leave four strands side to side with four Pennington grasps. If there are healthy vincula, I try to make the stitch in the volar half of the circumferential area to respect nutrition, since they enter through the dorsal area of the tendon. If I cannot use a double thread, I make a cross center stitch (4 strands). I add a running peripheral suture with nylon 6-0 (Figure 13). It is important to bear in mind that to indicate early active flexion, the suture must tolerate 40 N of load during the first week and this implies that at least four strands pass from side to side with four locked grasps and one running peripheral suture. Next, I perform the DEFT test and check for lack of gapping and friction (Figure 14). If I observe friction, I prefer to open more sheath or to resect a band of the FDS. If necessary, I do not hesitate to resect it completely. If I observe gapping, I redo the suture.

At the moment I am not adding substances to attempt to chemically manipulate the repair process or adhesions as they are still being studied.

I close the skin with closely spaced 4-0 nylon sutures.

I always used the Kleinert method to rehabilitate my patients (active extension, passive flexion with elastic band and a pulley in the palm). For five years, I have been trying to test the resistance of my repair with DEFT and after the fifth postoperative day, I start with controlled non-resisted active mobility. If I cannot test intraoperative flexion-extension and I have doubts regarding the strength of the chosen configuration, I indicate Kleinert from the beginning (Figure 6).

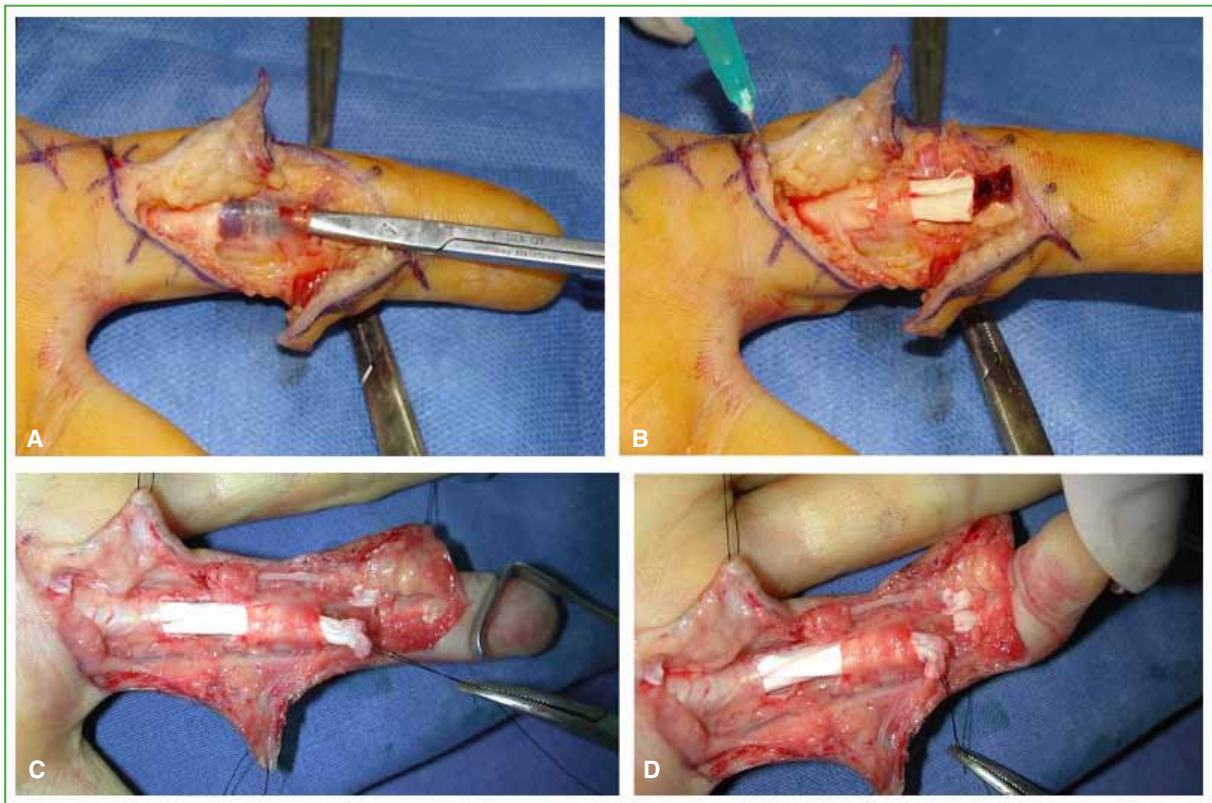


Figure 10. A. If the vinculum is healthy, the proximal end is close. B. End threaded and held with an intramuscular needle that fixes it to the sheath. C and D. Distal end approach, flexing the distal interphalangeal joint.

THE FUTURE

Pharmacological manipulation of the repair process is in the experimental stage. The objective is to increase the intrinsic capacity for tendon repair and decrease the formation of adhesions. The elements that can improve repair are: undifferentiated cells similar to those found in the epitenon and growth factors that promote cell proliferation and collagen production. Stem cell-seeded sutures are currently being used.³⁰ Injecting growth factors into the tendon ends is also being tested; as their lifespan is short, polymers with growth factors are impregnated to produce a prolonged release.^{31,32} Another method is gene therapy: the genes that produce growth factors are identified, they are placed in a viral vector (adenovirus), then this set—called a transgene—is injected into the tendon ends and a continuous production of growth factors is achieved for four weeks.³³

The substances that could reduce adhesions when injected into the area are: 5-fluorouracil, hyaluronic acid or interfering RNA that silences factors that favor fibrosis. Exposure of the tissues to 5-fluorouracil for 5 min inhibits fibroblast proliferation for 36 days without affecting the intrinsic healing of the tendon.³⁴ On the other hand, hyaluronic acid would favor tendon gliding within the sheath, reducing friction.³⁵ The interposition of tissues that act as a barrier to extrinsic healing, such as the amniotic membrane, is also being tested.³⁶

Although these investigations are not yet supported by human evidence, it appears that the biological path would lead future advances.

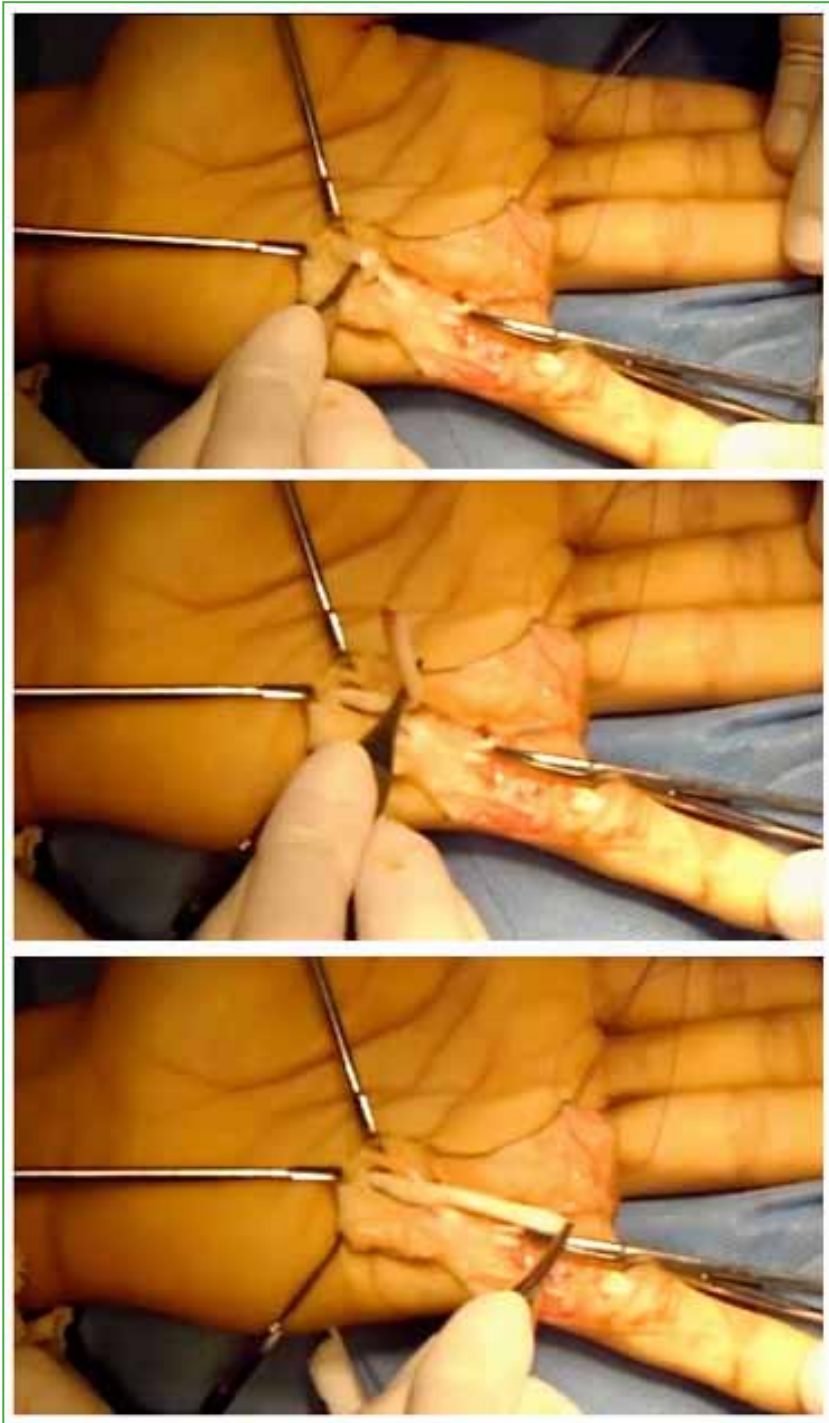


Figure 11. Proximal end in the palm, sometimes curled proximally, but always supported by the lumbrical.

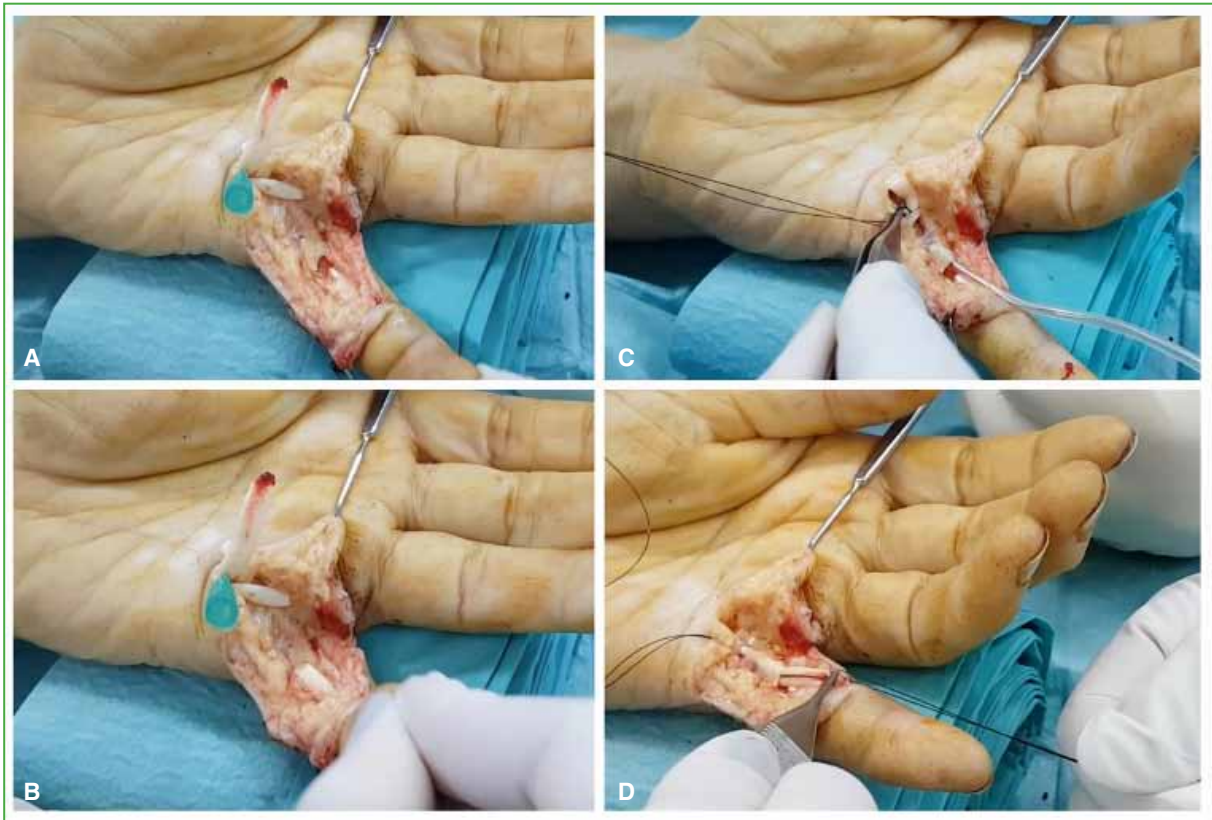


Figure 12. Threading the proximal end. **A.** The ends are placed in the palm. **B.** By flexing the distal joints, the distal end of the flexor digitorum profundus appears. **C and D.** Threading through A2 with a cannula and nylon.

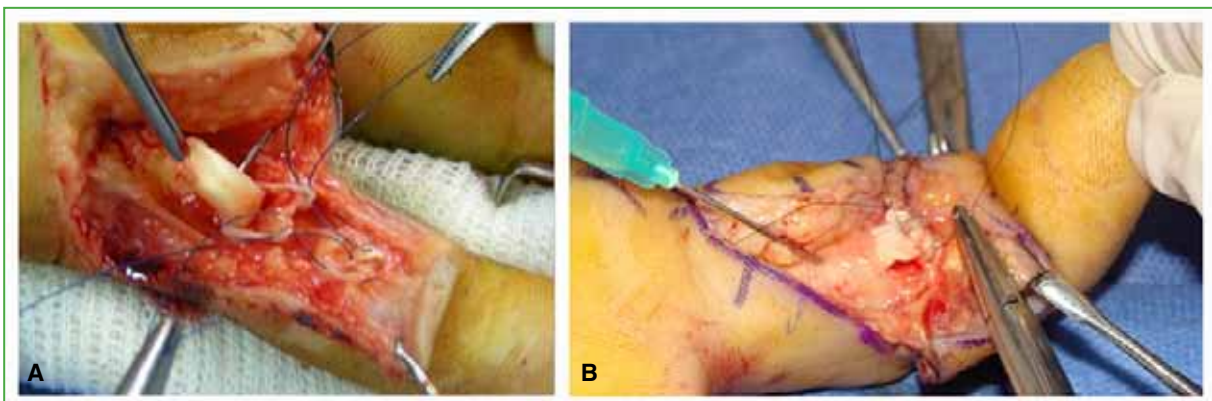


Figure 13. **A.** Flexor digitorum superficialis suture with two 4-0 nylon U-stitches, respecting Camper's chiasm. **B.** Running suture with 6-0 nylon after central stitch.

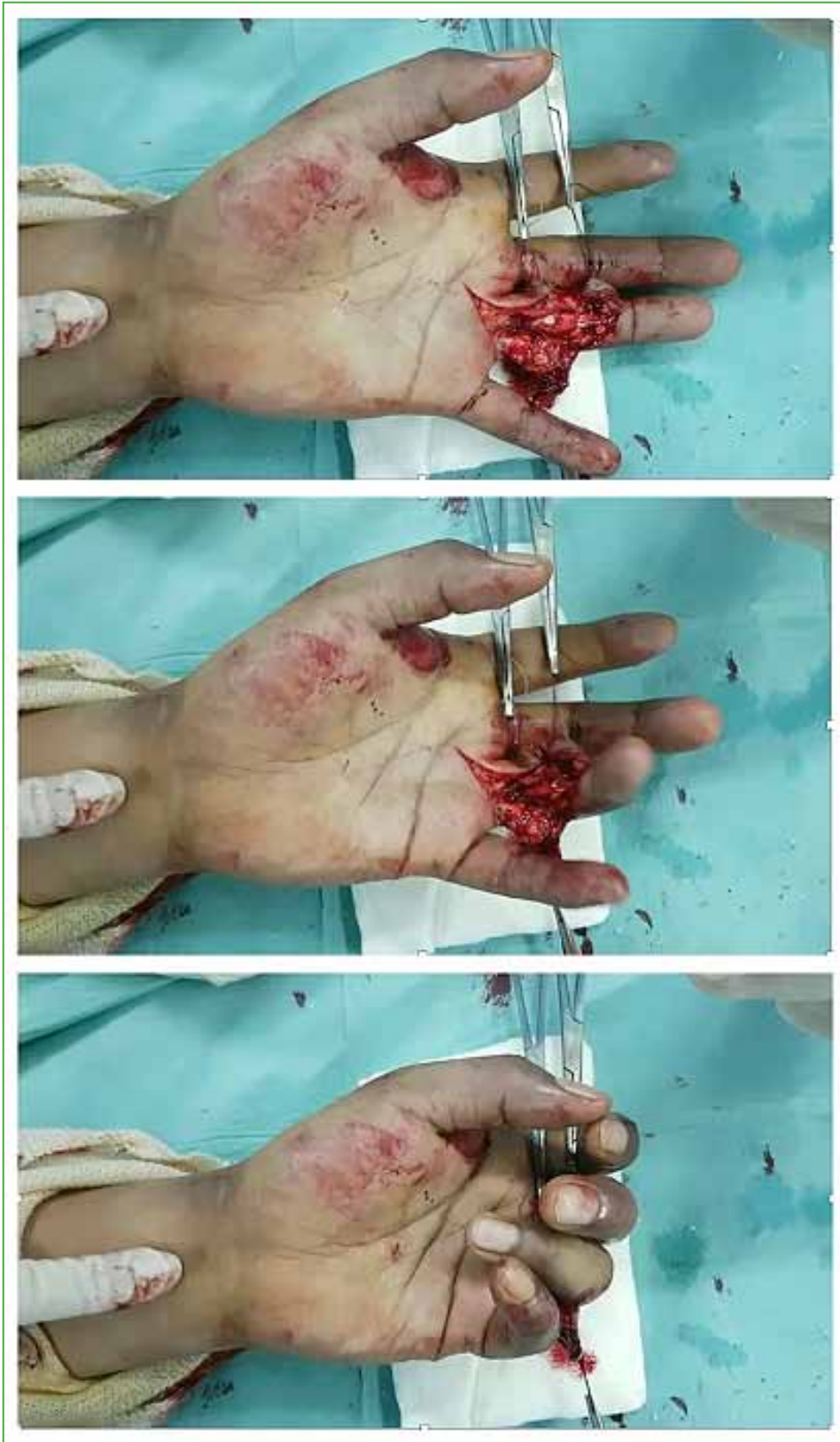

Figure 14. Active flexion-extension test. DEFT = digital extension-flexion test with the patient awake (WALANT: *Wide Awake Local Anesthesia no Tourniquet*).

Conflict of interest: The author declares she does not have any conflict of interest.

REFERENCES

1. Clayton RA, Court-Brown CM. The epidemiology of musculoskeletal tendinous and ligamentous injuries. *Injury* 2008;39(12):1338-44. <https://doi.org/10.1016/j.injury.2008.06.021>
2. Kaplan EB, Hunter JM. Functional anatomy of the flexor tendon system: The muscles and tendon systems of the fingers. En: Hunter JM, Schneider LH, Mackin EJ (eds). *Tendon and nerve surgery in the hand. A third decade*. St. Louis, Mosby; 1997:240-52.
3. Fussey JM, Chin KF, Gogi N, Gella S, Deshmukh SC. An anatomic study of flexor tendon sheaths: a cadaveric study. *J Hand Surg Eur* 2009;34:762-5. <https://doi.org/10.1177/1753193409344529>
4. Doyle JR. Anatomy of the finger flexor tendon sheath and pulley system. *J Hand Surg Am* 1988;13:473-84. [https://doi.org/10.1016/s0363-5023\(88\)80082-0](https://doi.org/10.1016/s0363-5023(88)80082-0)
5. Strauch B, de Moura W. Digital flexor tendon sheath: an anatomic study. *J Hand Surg Am* 1985;10:785-9. [https://doi.org/10.1016/s0363-5023\(85\)80152-0](https://doi.org/10.1016/s0363-5023(85)80152-0)
6. Ochiai N, Matsui T, Miyaji N, Merklin RJ, Hunter JM. Vascular anatomy of flexor tendons. I. Vincular system and blood supply of the profundus tendon in the digital sheath. *J Hand Surg Am* 1979;4(4):321-30. [https://doi.org/10.1016/s0363-5023\(79\)80068-4](https://doi.org/10.1016/s0363-5023(79)80068-4)
7. Gelberman RH, Goldberg V, An KN, Banes A. Tendon. En: Woo SLY, Buckwalter JA (eds). *Injury and repair of the musculoskeletal soft tissues*. Park Ridge, IL: American Academy of Orthopaedic Surgeons; 1988:5-40.
8. Kryger GS, Chong AK, Costa M, Pham H, Bates S, Chang J. A comparison of tenocytes and mesenchymal stem cells for use in flexor tendon tissue engineering. *J Hand Surg Am* 2007;32(5):597-605. <https://doi.org/10.1016/j.jhsa.2007.02.018>
9. Manning CN, Havlioglu N, Knutsen E, Sakiyama-Elbert SE, Silva M, Thomopoulos S, et al. The early inflammatory response after flexor tendon healing: a gene expression and histological analysis. *J Orthop Res* 2014;32(5):645-52. <https://doi.org/10.1002/jor.22575>
10. Bunnell S. Repair of tendons in the fingers and description of two new instruments. *Surg Gynecol Obstet* 1918;26:103-10.
11. Verdan CE. Practical considerations for primary and secondary repair in flexor tendon injuries. *Surg Clin North Am* 1964;44:951-70. [https://doi.org/10.1016/s0039-6109\(16\)37336-4](https://doi.org/10.1016/s0039-6109(16)37336-4)
12. Kleinert HE, Kutz JE, Ashbell TS, Martinez E. Primary repair of lacerated flexor tendons in "no man's land". *J Bone Joint Surg Am* 1967;49:577. <https://doi.org/10.1201/b17524-8>
13. Kessler I, Nissim F. Primary repair without immobilization of flexor tendon division within the digital sheath: an experimental and clinical study. *Acta Orthop Scand* 1969;40(5):587-601. <https://doi.org/10.3109/17453676908989524>
14. Strickland JW. Development of flexor tendon surgery: twenty-five years of progress. *J Hand Surg Am* 2000;25(2):214-35. <https://doi.org/10.1053/jhsu.2000.jhsu25a0214>
15. Tang JB, Amadio PC, Guimberteau JC, Chang J. Primary flexor tendon surgery. En: *Tendon surgery of the hand*. Philadelphia: Elsevier; 2012:79-258.
16. Tang JB, Xie RG, Cao Y, Ke ZS, Xu Y. A2 pulley incision or one slip of the superficialis improves flexor tendon repairs. *Clin Orthop Relat Res* 2007;456:121-7. <https://doi.org/10.1097/01.blo.0000246564.96208.b0>
17. Tang JB. Wide-awake primary flexor tendon repair, tenolysis, and tendon transfer. *Clin Orthop Surg* 2015;7(3):275-81. <https://doi.org/10.4055/cios.2015.7.3.275>
18. Lalonde DH, Martin AL. Wide-awake flexor tendon repair and early tendon mobilization in zones 1 and 2. *Hand Clin* 2013;29(2):207-13. <https://doi.org/10.1016/j.hcl.2013.02.009>
19. Miller B, Dodds SD, deMars A, Zagoreas N, Waitayawinyu T, Trumble T. Flexor tendon repairs: the impact of fiberwire on grasping and locking core sutures. *J Hand Surg Am* 2007;32(5):591-6. <https://doi.org/10.1016/j.jhsa.2007.03.003>
20. Wu YF, Cao Y, Zhou YL, Tang JB. Biomechanical comparisons of four-strand tendon repairs with double-stranded sutures: effects of different locks and suture geometry. *J Hand Surg Eur* 2011;36(1):34-9. <https://doi.org/10.1177/1753193410379554>

21. Su BW, Protopsaltis TS, Koff MF, Chang KP, Strauch RJ, Crow SA, et al. The biomechanical analysis of a tendon fixation device for flexor tendon repair. *J Hand Surg Am* 2005;30(2):237-45. <https://doi.org/10.1016/j.jhsa.2004.07.020>
22. Hirpara KM, Sullivan PJ, O'Sullivan ME. A new barbed device for repair of flexor tendons. *J Bone Joint Surg Br* 2010;92(8):1165-70. <https://doi.org/10.1302/0301-620X.92B8.23029>
23. Duran RJ, Houser RG, Coleman CR, Stover MG. Management of flexor tendon lacerations in zone 2 using controlled passive motion postoperatively. En: Hunter JM, Schneider LH, Mackin EJ (eds). *Rehabilitation of the hand*. St. Louis: Mosby; 1978:217-24.
24. Zhao CF, Amadio PC, Zobitz ME, Momose T, Couvreur P, An K. Effect of synergistic motion on flexor digitorum profundus tendon excursion. *Clin Orthop Relat Res* 2002;396:223-30. <https://doi.org/10.1097/00003086-200203000-00033>
25. Silfverskiöld KL, May EJ, Törnvall AH. Flexor digitorum profundus excursions during controlled motion after flexor tendon repair in excursions during controlled motion after flexor tendon repairs in zone II: a prospective clinical study. *J Hand Surg Am* 1992;17(1):122-31. [https://doi.org/10.1016/0363-5023\(92\)90127-b](https://doi.org/10.1016/0363-5023(92)90127-b)
26. Strickland JW. Flexor tendon repair: Indiana method. *Indiana Hand Center Newsletter* 1993;1:1-12.
27. Groth GN. Pyramid of progressive force exercises to the injured flexor tendon. *J Hand Ther* 2004;17(1):31-42. <https://doi.org/10.1197/j.jht.2003.10.005>
28. Savage R. The influence of wrist position on the minimum force required for active movement of the interphalangeal joints. *J Hand Surg* 1988;13(3):262-8. [https://doi.org/10.1016/0266-7681\(88\)90082-4](https://doi.org/10.1016/0266-7681(88)90082-4)
29. Paneva-Holevich E. Two-stage reconstruction of the flexor tendons. *Int Orthop* 1982;6(2):133-8. <https://doi.org/10.1007/BF00268657>
30. Yao J, Korotkova T, Riboh J, Chong A, Chang A, Smith R. Bioactive sutures for tendon repair: assessment of a method of delivering pluripotential embryonic cells. *J Hand Surg Am* 2008;33(9):1558-64. <https://doi.org/10.1016/j.jhsa.2008.06.010>
31. Chan BP, Fu S, Qin L, Rolf CG, Chan K. Effects of basic fibroblast growth factor (bFGF) on early stages of tendon healing: a rat patellar tendon model. *Acta Orthop Scand* 2000;71(5):513-8. <https://doi.org/10.1080/000164700317381234>
32. Thomopoulos S, Das R, Silva MJ, Sakiyama-Elbert S, Harwood FL, Zampiakis E, et al. Enhanced flexor tendon healing through controlled delivery of PDGF-BB. *J Orthop Res* 2009;27(9):1209-15. <https://doi.org/10.1002/jor.20875>
33. Kaplitt MG, Feigin A, Tang C, Fitzsimons HL, Mattis P, Lawlor PA, et al. Safety and tolerability of gene therapy with an adeno-associated virus (AAV) borne GAD gene for Parkinson's disease: an open label, phase I trial. *Lancet* 2007;369(9579):2097-105. [https://doi.org/10.1016/S0140-6736\(07\)60982-9](https://doi.org/10.1016/S0140-6736(07)60982-9)
34. Moran S, Ryan C, Orlando G, Pratt C, Michalko K. Effects of 5-fluorouracil on flexor tendon repair. *J Hand Surg Am* 2000;25:242-50. <https://doi.org/10.1053/jhsu.25a0242>
35. Moro-oka T, Miura H, Mawatari T, Kawano T, Nakanishi Y, Higaki H, et al. Mixture of hyaluronic acid and phospholipid prevents adhesion formation on the injured flexor tendon in rabbits. *J Orthop Res* 2000;18(5):835-40. <https://doi.org/10.1002/jor.1100180523>
36. Liu C, Bai J, Yu K, Liu G, Tian S, Tian D. Biological amnion prevents flexor tendon adhesion in zone II: a controlled, multicentre clinical trial. *Biomed Res Int* 2019;2019:2354325. <https://doi.org/10.1155/2019/2354325>