

Nerve Transfers for Elbow Flexion in Traumatic Brachial Plexus Injuries

Ricardo M. Gardenal,^{1,*} Manuel Vélez,^{2,*} Ernesto Glasberg,³ Matías Seri,⁴ Sebastián Faccendini,⁵ Miguel Slullitel,⁶ Jorge Bichara,^{7,*} Miguel Capomassi⁸

¹Upper Limb Surgery Department, Dr. Jaime Slullitel Institute, Rosario, Santa Fe, Argentina

²Orthopedics and Traumatology Service, Sanatorio Plaza, Rosario, Santa Fe, Argentina

³Orthopedics and Traumatology Service, Emergency Hospital "Dr. Clemente Alvarez", Rosario, Santa Fe, Argentina

ABSTRACT

Objective: To evaluate the results of different nerve transfers used for elbow flexion in patients with traumatic brachial plexus injury. **Materials and Methods:** Between April 2012 and January 2019, 13 patients (12 men) with traumatic brachial plexus injury underwent surgery. 5 patients had total paralysis and did not recover, 4 had total paralysis and partially recovered the lower trunk, and 4 had high paralysis. The nerve transfers performed for elbow flexion were: 3 intercostal nerves with a sural graft to the musculocutaneous nerve or its motor branch(es) (4 patients), 3 intercostal nerves to the musculocutaneous nerve without graft (3 patients), the accessory spinal nerve to motor branches of the musculocutaneous nerve with sural graft (2 patients), fascicles of the ulnar nerve to the motor branch of the biceps (3 patients) and fascicles of the ulnar nerve and fascicles of the median nerve to the motor branches of the biceps and anterior brachialis (3 patients). We assessed elbow flexion strength (M0-M5), pain on the visual analog scale, and DASH score. The average follow-up was 50 months. **Results:** Elbow flexion strength was M5 (1 patient), M4 (7 patients), M3 (1 patient), M2 (1 patient), and M1 (2 patients). The mean DASH score was 54.1 before surgery and 29.5 postoperatively. The preoperative pain score was 7 and 0.9 postoperatively. There were no complications. **Conclusions:** Nerve transfers achieved satisfactory outcomes for active elbow flexion reconstruction in patients with brachial plexus injury.

Keywords: Nerve transfers; elbow flexion; brachial plexus injury.

Level of Evidence: IV. Case report

Neurotizaciones para la flexión de codo en lesiones traumáticas del plexo braquial

RESUMEN

Objetivo: Evaluar los resultados de diferentes neurotizaciones utilizadas para la flexión del codo en pacientes con lesión traumática del plexo braquial. **Materiales y Métodos:** Entre abril de 2012 y enero de 2019, se operaron 13 pacientes (12 hombres) con lesión traumática del plexo braquial, 5 con parálisis totales sin recuperación, 4 con parálisis totales que recuperaron el tronco inferior parcialmente y 4 con parálisis altas. Las neurotizaciones para la flexión del codo fueron: 3 nervios intercostales con injerto sural a nervio musculocutáneo o su(s) rama(s) motora(s) (4 pacientes), 3 nervios intercostales a nervio musculocutáneo sin injerto (3 pacientes), nervio espinal accesorio a ramas motoras del nervio musculocutáneo con injerto sural (2 pacientes), fascículos del nervio cubital a rama motora del bíceps (3 pacientes) y fascículos del nervio cubital y fascículos del nervio mediano a ramas motoras del bíceps y braquial anterior (3 pacientes). Se evaluaron la fuerza de flexión del codo (M0-M5), el dolor con la escala analógica visual y se utilizó el puntaje DASH. El seguimiento promedio fue de 50 meses. **Resultados:** La fuerza de flexión del codo fue M5 (1 paciente), M4 (7 pacientes), M3 (1 paciente), M2 (1 paciente) y M1 (2 pacientes). El puntaje DASH promedio fue de 54,1 antes de la cirugía y 29,5 en el posoperatorio. El puntaje de dolor preoperatorio fue de 7 y de 0,9 posoperatorio. No hubo complicaciones. **Conclusiones:** Las neurotizaciones lograron resultados satisfactorios en la reconstrucción de la flexión activa del codo en pacientes con lesión del plexo braquial.

Palabras clave: Neurotizaciones; flexión codo; lesión plexo braquial.

Nivel de Evidencia: IV Serie de casos

Received on January 25th, 2022. Accepted after evaluation on June 28th, 2022 • Dr. RICARDO M. GARDENAL • drmartingardenal@gmail.com  <https://orcid.org/0000-0003-0013-9275>

How to cite this article: Gardenal RM, Vélez M, Glasberg E, Seri M, Faccendini S, Slullitel M, Bichara J, Capomassi M. Nerve Transfers for Elbow Flexion in Traumatic Brachial Plexus Injuries. *Rev Asoc Argent Ortop Traumatol* 2022;87(4):507-516. <https://doi.org/10.15417/issn.1852-7434.2022.87.4.1503>

INTRODUCTION

Traumatic brachial plexus injuries are rare, but severely disabling. In adults, recovery from elbow flexion paralysis is the first goal of treatment, followed by functional recovery of the shoulder.¹⁻⁴

Multiple reconstruction methods are available, such as microsurgical procedures—which are preferred in early stages—tendon transfers, vascularized and reinnervated free muscle transfers, arthrodesis, osteotomies, tenodesis, and arthrolysis, among others, for which there is no time limit. Microsurgical techniques include neurolysis, neuroorrhaphy with or without graft, and nerve transfer. In nerve transfers, a redundant or “sacrificable” donor nerve is sectioned and its proximal end is transferred to the distal end of an injured nerve, as close as possible to the muscle to be innervated (Figure 1). It is a nerve transfer from a functioning nerve to a more important denervated nerve, as long as the time elapsed since the injury does not exceed 12-16 months, since it is known that the best outcomes are obtained with procedures performed within the first five months.⁵ This is due to the fact that a muscle that does not receive its nervous stimulation, over time, suffers the degeneration and atrophy of its neuromuscular plates, which prevents its subsequent reinnervation.

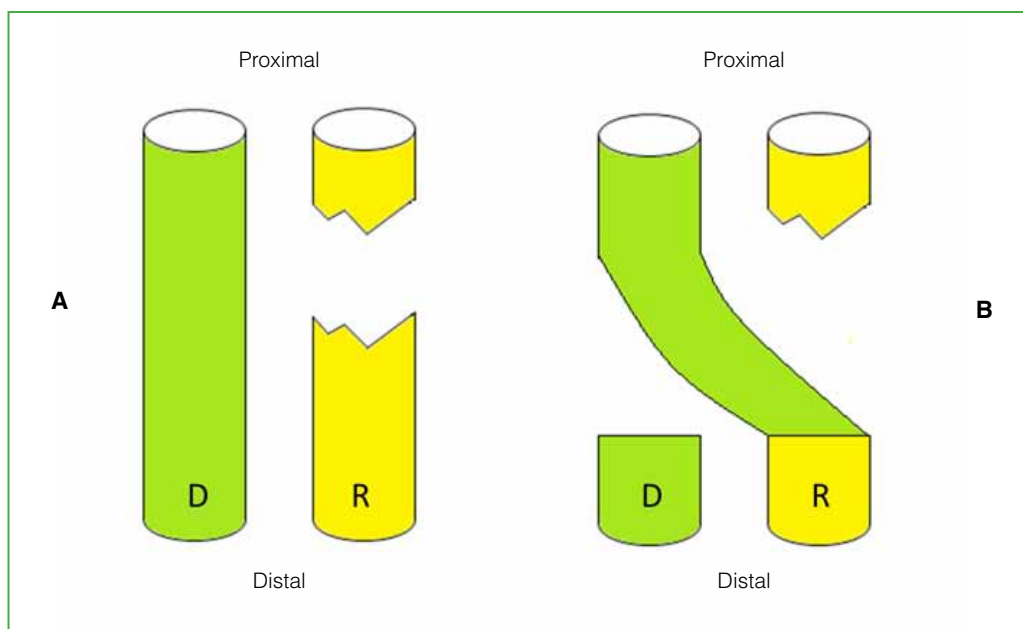


Figure 1. Diagram of a nerve transfer. **A.** Traumatic axonotmesis of the receptor nerve (R). **B.** Nerve transfer with donor nerve (D).

There are multiple possible nerve transfers for the shoulder, elbow or hand in the context of a brachial plexus injury. They can be categorized as extraplexus or intraplexus, depending on the donor nerve.

Extraplexus neurotizations include the transfer of a nerve outside the brachial plexus; the most commonly used are the intercostal, spinal accessory, and phrenic nerves. Intraplexus neurotizations are transfers of a functioning nerve component belonging to the brachial plexus. The transfer of fascicles of the ulnar or median nerve to motor branches of the musculocutaneous muscle for the biceps and anterior brachialis in high plexus injuries is widely used today. Another donor nerve used is the radial branch for the medial portion of the triceps for the axillary nerve.

The objective of this study was to evaluate the results of different neurotizations used to recover active elbow flexion in patients treated for traumatic brachial plexus injury.

MATERIALS AND METHODS

Between April 2012 and January 2019, 13 patients with traumatic brachial plexus injury underwent nerve transfers for elbow flexion, performed by the same surgeon, at three Centers. The patients were 12 men and a 10-year-old girl, and the average age at surgery was 26 years (range 10-44). The affected limb was the left in eight cases and the right in five patients (dominant limb in 38.4%). The palsies treated included five total brachial palsies that did not recover, four total palsies that partially recovered the lower trunk, and four upper palsies, two of them with partial recovery of the shoulder. The mechanism of the trauma was a traffic accident in 12 patients: motorcycle (10 patients), bicycle (1 patient), and car (1 patient). One patient had sustained direct trauma from falling on his shoulder into a eucalyptus tree trunk. The average time elapsed between trauma and surgery was 8.7 months (range 4-13). In 11 patients (85%), important associated traumatic pathologies were diagnosed (Table 1).

Table 1. Number of cases

Case	Age	Sex	Dominance	Limb	Type of paralysis	Associated injuries
1	25	M	Right-handed	Left	Total with partial recovery of finger flexion	Ipsilateral rib and clavicle fractures
2	21	M	Right-handed	Left	High	TBI with loss of consciousness
3	23	M	Right-handed	Left	Total	Nonunion of the clavicle and forearm (ulna and radius), ipsilateral leg <i>steppage</i>
4	28	M	Right-handed	Left	Total	Ipsilateral foot amputation
5	19	M	Right-handed	Left	Total	Open fracture of the ipsilateral humerus
6	23	M	Right-handed	Left	Total	TBI with loss of consciousness, seizures, mild cognitive sequela
7	33	M	Right-handed	Right	Total with full recovery of wrist and finger flexion	No
8	38	M	Right-handed	Right	Total with partial recovery of the ulnar, median and radial nerve	Fractures of the humerus and scapula, metacarpophalangeal dislocation (3, 4 and 5), fracture of the third ipsilateral metacarpal
9	21	M	Right-handed	Right	Total	TBI with loss of consciousness, fracture of the 1 st ipsilateral rib
10	44	M	Right-handed	Left	High	No
11	28	M	Right-handed	Left	Total with recovery of the ulnar nerve	Fractures of 4 ribs, scapula, open fracture dislocation of the ipsilateral elbow, contralateral brachial plexus palsy with spontaneous recovery in 3 months
12	10	F	Right-handed	Right	Total with partial recovery, shoulder abduction	Supracondylar fracture of the ipsilateral elbow
13	26	M	Right-handed	Right	Discharge with partial recovery, shoulder abduction	TBI with loss of consciousness, fracture of nasal bones and forearm bones

M = male, F = female, TBI = traumatic brain injury.

The nerve transfers used for the microsurgical reconstruction of elbow flexion were: three intercostal nerves with sural graft to the musculocutaneous nerve or its motor branch(es) for each case (4 patients), three intercostal nerves to the musculocutaneous nerve without graft interposition (1 patient), spinal accessory nerve to motor branches of the musculocutaneous nerve with sural graft (2 patients), motor fascicles of the ulnar nerve to motor branch of the biceps (simple Oberlin) (3 patients) and motor fascicles of the ulnar nerve and motor fascicles of the median nerve to motor branches of the biceps and anterior brachialis (double Oberlin) (3 patients). The fascicles of the ulnar nerve are used for the flexor carpi ulnaris muscle, whereas the median nerve fascicles are used for the palmaris longus. During surgery, the fascicles are electrostimulated to determine which ones predominantly innervate these muscles. The reconstruction techniques used were chosen individually, taking into account the different lesions of the patients, with different donor nerves available and also considering their associated conditions. As an example, three cases are shown, with different surgical techniques (Figures 2-4).

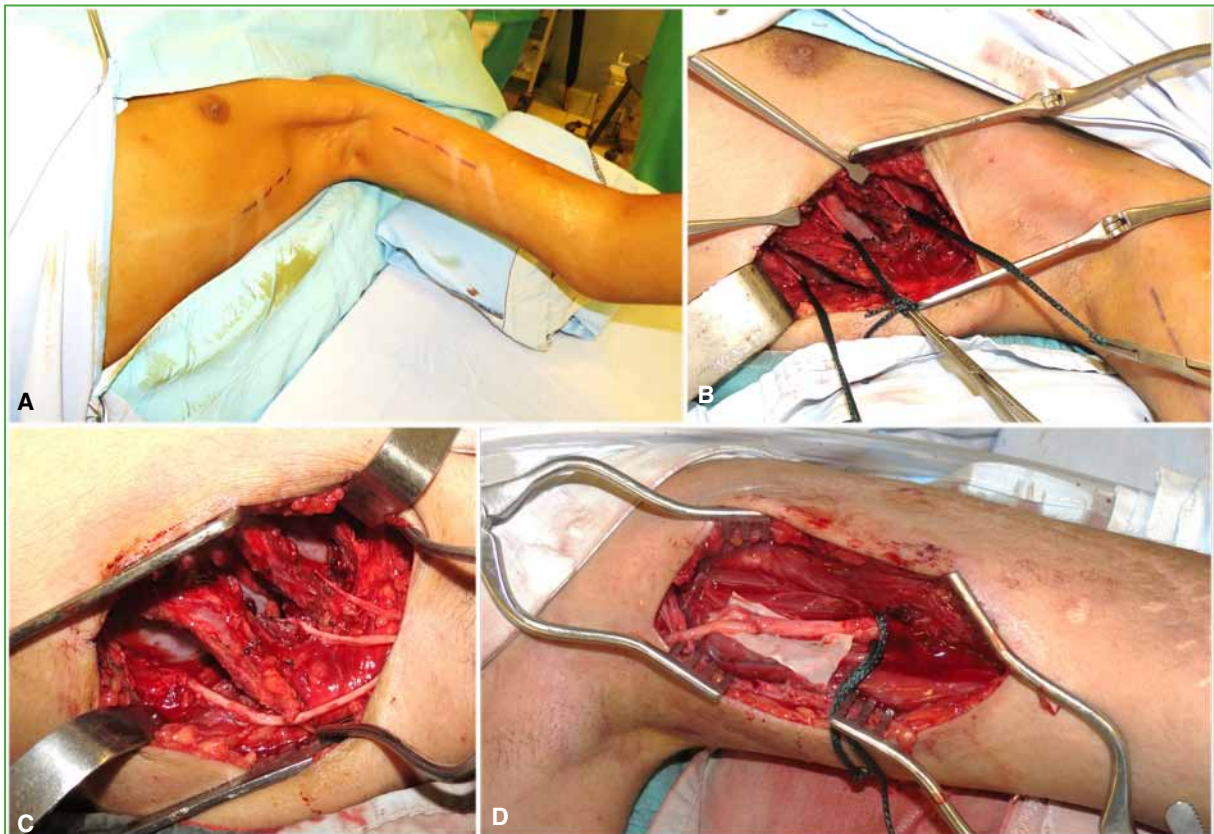


Figure 2. Nerve transfer of the motor branch of the biceps with three intercostal nerves with a sural graft. (Case 5). **A.** Presurgical markings and fields. **B.** Dissection of three intercostal nerves in the thorax. **C.** x3 Intercostal-sural neurorrhaphies. **D.** Neurorrhaphy of sural grafts to the motor branch of the biceps on the inner side of the arm.

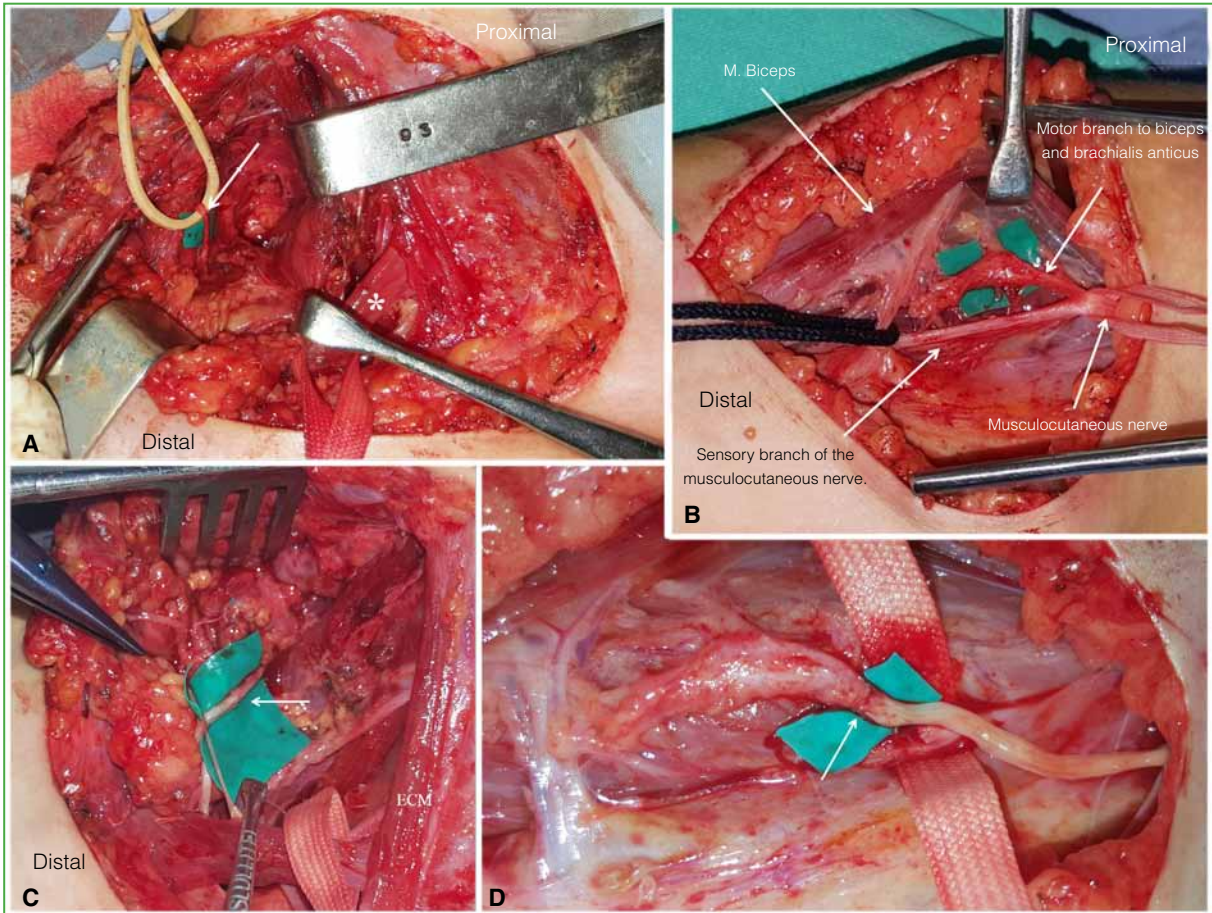


Figure 3. Neurotization of the motor branches of the musculocutaneous nerve with the spinal accessory nerve with a long sural graft (Case 12). **A.** Supraclavicular approach and dissection of the spinal accessory nerve (arrow). **B.** Dissection of the motor branches of the musculocutaneous nerve on the inner aspect of the arm. **C.** Neurotization of the spinal accessory-sural nerve (arrow) in the supraclavicular fossa. **D.** Sural graft neurotization to the motor branch of the biceps and anterior brachialis (arrow) on the inner aspect of the arm. *omohyoid muscle. SCM = sternocleidomastoid muscle.

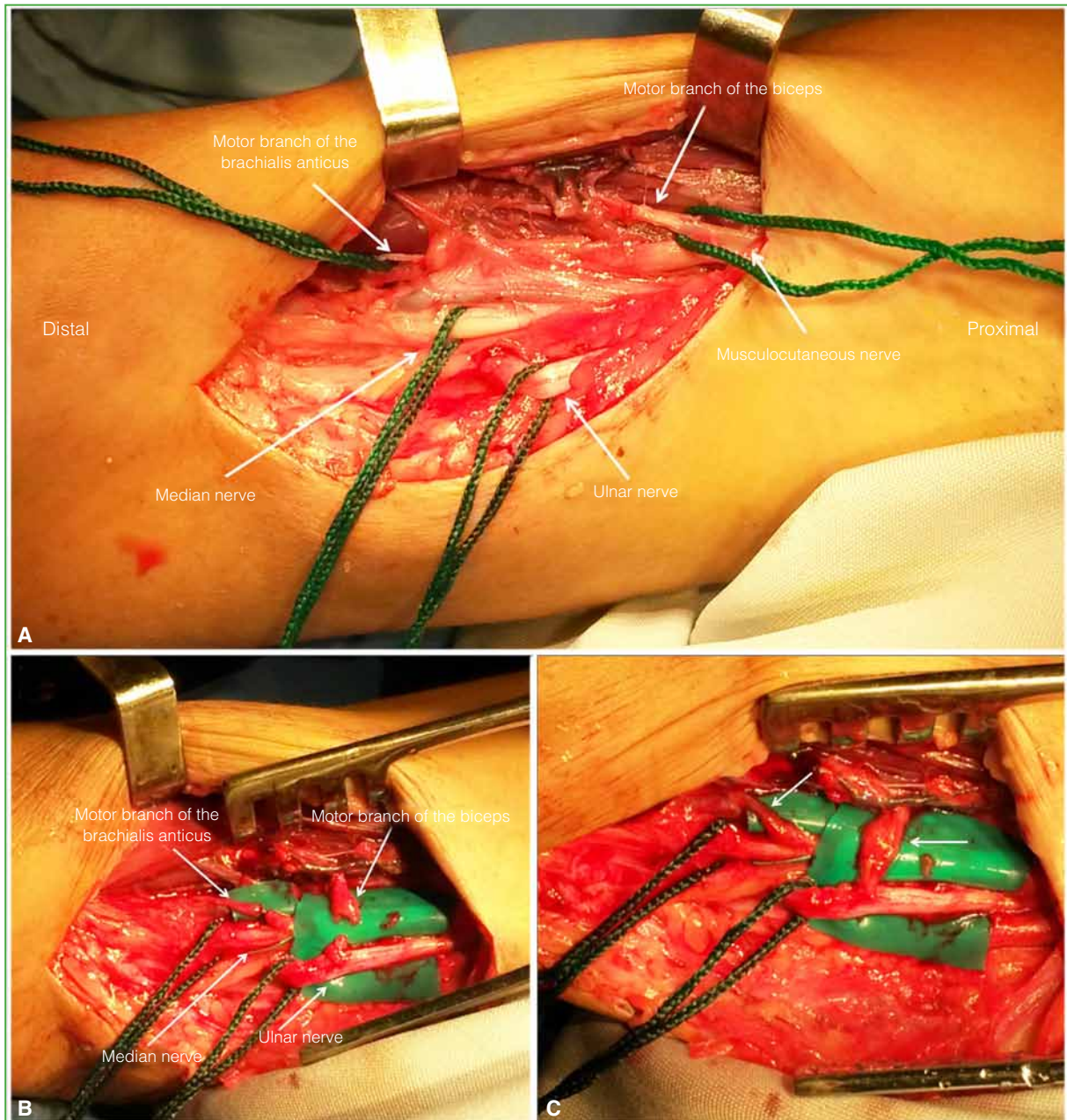


Figure 4. Neurotization of the motor branches of the biceps and anterior brachialis with motor fascicles of the ulnar and median nerves (Case 7). **A.** Approach to the inner aspect of the arm. **B.** Dissection of the motor fascicles of the ulnar and median nerves, and section of the motor branches of the biceps and anterior brachialis. **C.** Nerve transfers performed (arrows).

Although it is not the reason for this study, it is clarified that, for the shoulder, a supraclavicular neurolysis of the brachial plexus and a neurotization of the suprascapular nerve with an accessory spinal nerve were performed in seven patients.

The patients underwent rehabilitation protocols with physical therapy or occupational therapy according to their condition and the surgical technique used. In the first four weeks, movements that put the nerve sutures at risk were avoided, but the remaining joints were mobilized and treatment for pain, edema, and scarring was administered. After the first month, full passive range of motion was allowed and strengthening of the muscle group correspond-

ing to the transferred nerve(s) started, e.g. sit-ups and inspiratory exercises to strengthen the intercostal muscles. When observing the first sign of reinnervation of the elbow flexors, the muscle re-education phase began. This muscle strengthening is associated with active assisted flexion of the elbow, taking into account that the contraction of the reinnervated muscle begins with the contraction of the muscle corresponding to the donor nerve. In the case of neurotization using motor fascicles of the ulnar nerve for the biceps, the contraction of this muscle will be activated by flexing the wrist in ulnar deviation. As months go by, the loads and the repetitions of the exercises are increased and the cortical neuroplasticity of the patients will be able to make the flexion of the elbow independent of the contraction of the muscle corresponding to the donor nerve. That is, in the example above, the patient will be able to actively flex their elbow without needing to flex their wrist.

All patients underwent a subjective evaluation with the DASH score. (*Disabilities of the Arm, Shoulder and Hand*)⁶ and the visual analog scale (VAS) for pain before surgery and at the last control. Elbow flexion strength was assessed using the British *Medical Research Council* M0-M5 scale.⁷ Case 10 was excluded from the study, because the follow-up was shorter than one year, due to the loss of contact due to living in another province and lack of connectivity. The average follow-up of the remaining cases was 50 months.

RESULTS

In the last evaluation, the elbow flexion strength showed that the 10-year-old girl obtained an M5 value; seven patients had an M4 value; one patient, M3; one patient, M2; and two patients, M1. We consider satisfactory values to be those \geq M3, that is, those that manage to flex the elbow against the force of gravity, as has been established internationally.⁸ Nine patients (75%) obtained this result. The mean DASH score was 54.1 preoperatively and 29.5 postoperatively. The VAS score was 7 before the intervention and 0.9 at the last control. The reconstruction method used and its individual functional evaluation are shown in [Table 2](#).

The only complication occurred in the patient with nerve transfer of the intercostal musculocutaneous nerve without grafts, who suffered dehiscence of the wound in the armpit and was adequately treated with Irujol[®] ointment.

There were no pleural lesions during intercostal graft harvesting, nor neural pain or motor or sensory complications related to donor nerve territories.

DISCUSSION

Traditionally, in brachial plexus reconstruction, direct nerve repair with or without nerve grafts led to poor outcomes due to the long distances that axonal regeneration must travel after neurorrhaphy, which implies a longer time than the reinnervation potential of muscle motor plates, which is estimated at 12-18 months.⁹ Under these circumstances, neurotizations allow the regeneration distance between viable proximal motor axons and distal motor endplates to be reduced, thus achieving faster reinnervation and, in most cases, better functional outcomes.

In addition, it is very common for brachial plexus injuries to be directly irreparable, from a technical point of view. Such is the case of root avulsions in which there is no proximal nerve ending that can be sutured.

Another possible scenario is patients who could not undergo direct neurorrhaphy within the indicated time, due to delays in the specialized consultation or other injuries, and functional recovery is no longer possible. In our field, it is common for patients to consult with delay for the resolution of their paralysis, as they have already been evaluated in one or several Centers that do not have the technical possibility of microsurgical treatment and the referral is often late. In the case series presented, 54% (7 patients) underwent surgery after 10 or more months of evolution.

Direct repair at sites adverse to nerve regeneration, such as areas with loss of skin coverage, infection, or vascular injury, will also not be successful.

There is another advantage of nerve transfers. When the goal is to recover motor function, neurotization of pure motor axons to a motor nerve is more likely to achieve the desired function than coaptation of a mixed (motor-sensory) nerve to the mixed distal end. In addition, in neurotizations, nerve grafts are less frequently needed than in traditional neurorrhaphy.

In summary, the basic indication for nerve transfers is injuries in which direct repair is not possible or in which it is, but functional recovery with direct repair or nerve grafting is unlikely.⁹

Table 2. Technique used and outcomes

Case	Elbow reconstruction	Trauma-surgery time (months)	Flexion strength of the elbow	DASH Preoperative period:	final DASH	VAS (preoperative)	VAS (final)	Follow-up (months)
1	3 intercostals with sural graft	10	4	52.5	28.3	4	1	111
2	Ulnar fascicles to biceps branch	11	4	40.8	15	6	0	103
3	3 intercostal nerves without graft to musculocutaneous	11	1	57.8	30.8	7	0	19
4	3 intercostals with sural graft	10	4	53.3	32.5	10	2	25
5	3 intercostals with sural graft	13	4	52.4	29.1	9	0	93
6	Accessory spinal nerve with sural graft	13	3	46.7	23.8	2	0	36
7	Fascicles from the ulnar to the biceps branch and from the median to the anterior brachial branch	6	4	71.7	36.7	9	0	17
8	Ulnar fascicles to biceps branch and median nerve to anterior brachial branch	6	1	63.9	43.3	8	4	58
9	3 intercostals with sural nerve grafts	4	2	61.7	32.3	10	2	40
10	Ulnar fascicles to biceps branch	6	No	No	No	No	No	Insufficient
11	Ulnar fascicles to biceps branch	10	4	55.7	29.1	6	0	47
12	Accessory spinal nerve with sural graft	6	5	38.6	26.8	9	0	28
13	Median nerve fascicles to biceps branch and ulnar fascicles to anterior brachialis branch	8	4	55	27.2	5	2	27

DASH = *Disabilities of the Arm, Shoulder and Hand*, VAS = *Visual Analog Scale*

The results obtained in our series to achieve elbow flexion with nerve transfers were adequate and within what was expected, according to the literature. In the meta-analysis by Merrell et al.,⁸ 71% of M3 strength or more was observed with neurotizations for elbow flexion, regardless of the donor nerve; the two most used nerves were the intercostal nerves and the spinal accessory nerve. Better outcomes can be expected with intraplexus neurotization with motor fascicles of the ulnar nerve (Oberlin), with which 97% of M3 strength or more is achieved.^{10,11} The functional recovery time of the biceps is shorter than with any other neurotization. This is its biggest advantage. This is because the transfer is carried out very close to the muscle to be reinnervated and without graft interposition. Therefore, the procedure is especially useful for patients who, for whatever reason, are being treated more than six months post-injury.

In 2002, Humphreys and Mackinnon¹² described a double fascicular transfer technique for elbow flexion. It involves the nerve transfer of the motor branches of the biceps and the anterior brachialis with redundant fascicles of the ulnar and median nerves, without the need to interpose a nerve graft. In this way, the brachialis anterior adds to the flexion force provided by the biceps. Regarding the outcomes, there are authors¹³⁻¹⁵ who ratify the superiority of double nerve transfer compared to single transfer of the motor branch of the biceps; however, others find no functional difference between the two techniques.^{16,17}

The limitations of this study are its retrospective design, with a modest number of patients, given that a rare pathology is being evaluated. For this reason, it is not possible to perform a statistical analysis with sufficient power to establish definitive treatment guidelines.

CONCLUSION

In our series, nerve transfers were valid and reliable options in the reconstruction of active elbow flexion in patients with traumatic injury to the brachial plexus, with a low rate of complications.

Conflict of interest: The authors declare no conflicts of interest.

M. Velez ORCID ID: <https://orcid.org/0000-0003-4094-0876>

E. Glasberg ORCID ID: <https://orcid.org/0000-0002-2447-8573>

M. Seri ORCID ID: <https://orcid.org/0000-0001-7219-712X>

S. Faccendini ORCID ID: <https://orcid.org/0000-0001-8035-6055>

M. Stullitel ORCID ID: <https://orcid.org/0000-0001-7575-9212>

J. Bichara ORCID ID: <https://orcid.org/0000-0002-3624-2488>

M. Capomassi ORCID ID: <https://orcid.org/0000-0002-4445-662X>

REFERENCES

1. Brophy RH, Wolfe SW. Planning brachial plexus surgery: Treatment options and priorities. *Hand Clin* 2005;21(1):47-54. <https://doi.org/10.1016/j.hcl.2004.09.007>
2. Wood MB, Murray PM. Heterotopic nerve transfers: Recent trends with expanding indication. *J Hand Surg Am* 2007;32(3):397-408. <https://doi.org/10.1016/j.jhsa.2006.12.012>
3. Palazzi Coll S, Cáceres Lucero J. Lesiones del plexo braquial en el adulto: parte 2. *Rev Asoc Argent Ortop Traumatol* 2000;65(2):148-55. Available at: https://www.aaot.org.ar/revista/1993_2002/2000/2000_2/650209.pdf
4. Boretto J, Alfie V, Thomas MG, Galucci G, De Carli P. Neurotizaciones extraplexuales e intraplexuales en el tratamiento de las avulsiones radiculares (C5-C6) traumáticas del plexo braquial del adulto. *Rev Asoc Argent Ortop Traumatol* 2010;75(2):192-9. Available at: https://www.aaot.org.ar/revista/2010/n2/Rev_AsocArgentOrtopTraumatol_2010_75_192-199_Boretto.pdf
5. Chwei-Chin Chuang D. Nerve transfers in adult brachial plexus injuries: My methods. *Hand Clin* 2005;21(1):71-82. <https://doi.org/10.1016/j.hcl.2004.10.004>
6. Hudak PL, Amadio PC, Bombardier C. Development of an upper extremity outcome measure: the DASH (disabilities of the arm, shoulder and hand) [corrected]. The Upper Extremity Collaborative Group (UECG). *Am J Ind Med* 1996;29(6):602-8. [https://doi.org/10.1002/\(SICI\)1097-0274\(199606\)29:6<602::AID-AJIM4>3.0.CO;2-L](https://doi.org/10.1002/(SICI)1097-0274(199606)29:6<602::AID-AJIM4>3.0.CO;2-L)
7. Medical Research Council. *Aids to the investigation of peripheral nerve injuries*. 2nd ed. London: Her Majesty's Stationery Office, 1942.
8. Merrell GA, Barrie KA, Katz DL, Wolfe SW. Results of nerve transfer techniques for restoration of shoulder and elbow function in the context of a meta-analysis of the English literature. *J Hand Surg Am* 2001;26(2):303-14. <https://doi.org/10.1053/jhsu.2001.21518>
9. Mackinnon SE, Colbert SH. Nerve transfers for brachial plexus reconstruction. *Hand Clin* 2008;24(4):341-61. <https://doi.org/10.1016/j.hcl.2008.07.001>
10. Leechavengvongs S, Witoonchart K, Uerpairojkit C, Thuvasethakul P, Ketmalasiri W. Nerve transfer to biceps muscle using a part of the ulnar nerve in brachial plexus injury (upper arm type): a report of 32 cases. *J Hand Surg* 1998;23(4):711-6. [https://doi.org/10.1016/S0363-5023\(98\)80059-2](https://doi.org/10.1016/S0363-5023(98)80059-2)
11. Oberlin C. Nerve transfer to biceps muscle using a part of ulnar nerve for C5-6 avulsion of the brachial plexus— anatomical studies and report of four cases. *J Hand Surg Am* 1994;19(2):232-7. [https://doi.org/10.1016/0363-5023\(94\)90011-6](https://doi.org/10.1016/0363-5023(94)90011-6)
12. Humphreys DB, Mackinnon SE. Nerve transfers. *Oper Tech Plastic Reconstruct Surg* 2002;9(3):89-99. [https://doi.org/10.1053/otpr.2003.S1071-0949\(03\)00057-X](https://doi.org/10.1053/otpr.2003.S1071-0949(03)00057-X)

13. Goubier J-N, Teboul F. Technique of the double nerve transfer to recover elbow flexion in C5, C6, or C5 to C7 brachial plexus palsy. *Tech Hand Up Extrem Surg* 2007;11(1):15-7. <https://doi.org/10.1097/01.bth.0000248360.14448.6b>
14. Ray WZ, Pet MA, Yee A, Mackinnon SE. Double fascicular nerve transfer to the biceps and brachialis muscles after brachial plexus injury: clinical outcomes in a series of 29 cases. *J Neurosurg* 2011;114(6):1520-8. <https://doi.org/10.3171/2011.1.JNS10810>
15. Liverneaux PA, Diaz LC, Beaulieu JY, Durand S, Oberlin C. Preliminary results of double nerve transfer to restore elbow flexion in upper type brachial plexus palsies. *Plast Reconstr Surg* 2006;117(3):915-9. <https://doi.org/10.1097/01.prs.0000200628.15546.06>
16. Carlsen BT, Kircher MF, Spinner RJ, Bishop AT, Shin AY. Comparison of single versus double nerve transfers for elbow flexion after brachial plexus injury. *Plast Reconstr Surg* 2011;127(1):269-76. <https://doi.org/10.1097/PRS.0b013e3181f95be7>
17. Martins RS, Siqueira MG, Heise CO, Foroni L, Teixeira MJ. A prospective study comparing single and double fascicular transfer to restore elbow flexion after brachial plexus injury. *Neurosurgery* 2013;72(5):709-14; discussion 714-5; quiz 715. <https://doi.org/10.1227/NEU.0b013e318285c3f6>