

Case Presentation

Rodrigo Re

Diagnostic Imaging Service, Osteoarticular/Musculoskeletal Area – Interventionism, Sanatorio Allende, Córdoba, Argentina

Resolution on page 299.

A 15-year-old adolescent who suffered a traffic accident. The patient denied having lost consciousness and reported severe pain in the neck, with functional impairment as well as dysesthesia in the lower limbs. He was admitted in a spine table with cervical immobilization with a collar.

The radiographs included in the management protocol for traumatized patients were requested, in which the anteroposterior and lateral radiographs of the cervical spine stood out.

FINDINGS AND INTERPRETATION OF IMAGING STUDIES

In the radiographs of the cervical spine (**Figure 1**), a bilateral facet dislocation was visualized in the lateral projection, as well as loss of continuity of the three lines (anterior, posterior, and spinolaminar) at C5-C6 with overlapping of the facets of C5 on C6 (circle). There were no visible fractures.

The patient was hospitalized to continue with the studies and to undergo a more exhaustive neurological evaluation.

The imaging study was completed with a computed tomography and magnetic resonance imaging of the cervical spine.

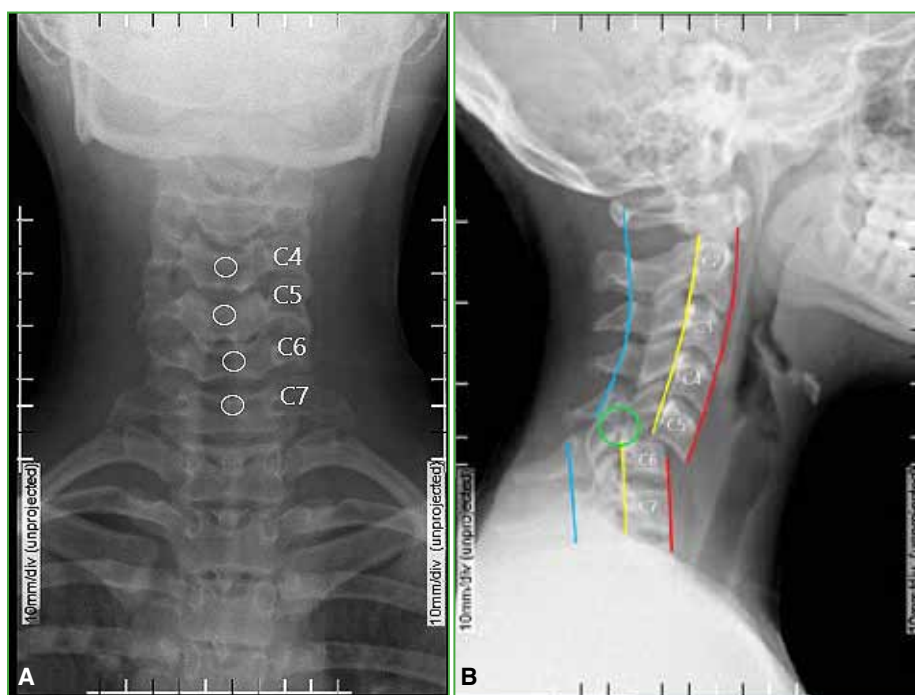


Figure 1. Cervical spine radiographs. **A.** Anteroposterior. Loss of continuity of the three lines (anterior, posterior, and spinolaminar) at C5-C6 with overlapping of the facets of C5 on C6 (circle). **B.** Lateral. Bilateral facet dislocation. Enlargement of the space between the C5-C6 spinous processes with loss of normal alignment. No evidence of fracture lines. No visible fractures.

Dr. RODRIGO RE • rodrigo_re@hotmail.com  <https://orcid.org/0000-0001-7382-9459>

How to cite this article: Re R. Postgraduate Orthopedic Instruction – Imaging. Case Presentation. *Rev Asoc Argent Ortop Traumatol* 2022;87(2):142. <https://doi.org/10.15417/issn.1852-7434.2022.87.2.1523>