

Recalcitrant Humeral Nonunion: Biological Reconstruction Technique

Martín Caloia, Alejandro Meritano, Diego González Scotti, Sergio Ronconi, María Emilia Serur, Hugo Caloia, Gerónimo Chamorro, Gonzalo Guevara Herrera, Agustina Laboranti

Hand and Reconstructive Upper Limb Surgery Sector, Orthopedics and Traumatology Service, Hospital Universitario Austral, Buenos Aires, Argentina

ABSTRACT

Introduction: Nonunion of the humeral shaft occurs in between 2% and 10% of non-surgically treated fractures and up to 15% of fractures treated with initial open reduction and internal fixation. The definition of recalcitrant nonunion is still under debate. The purpose of this study is to present the outcomes of a series of patients with recalcitrant pseudarthrosis of the humerus who were treated with stable osteosynthesis combined with biological reconstruction using allograft utilizing a novel surgical approach.

Materials and Methods: The series included 33 patients treated between 2012 and 2021. 20 women and 13 men, with a mean age of 65.4 years. The evolution time of recalcitrant pseudarthrosis was 33.3 months. The mean follow-up was 33.2 months. **Results:** Out of a total of 33 patients treated with this technique, 32 (97%) achieved a complete consolidation and one patient had a partial consolidation. The average consolidation period was 4.6 months and the complete osseointegration of the allograft was 8.1 months. For the functional evaluation, the visual analog scale (VAS), ASES score, Constant score and elbow motion arcs were taken into account. **Conclusions:** Even among experienced surgeons, the treatment of recalcitrant pseudarthrosis of the humerus remains an obstacle and an unsolved challenge. The use of a specialized osteosynthesis material added to a bone allograft fixed with screws significantly increases mechanical stability, allowing early range of motion, and works as an osteoinductive and osteoconductive scaffold, all of which are essential for consolidation.

Keywords: Nonunion; recalcitrant; allograft; humeral fractures.

Level of Evidence: IV

Seudoartrosis recalcitrante de húmero: técnica de reconstrucción biológica

RESUMEN

Introducción: La incidencia de seudoartrosis en las fracturas de húmero tratadas de forma conservadora es del 2-10%, y del 15% en aquellas operadas. La definición de seudoartrosis recalcitrante es aún tema de debate. El objetivo es comunicar los resultados de una serie de pacientes con seudoartrosis recalcitrante de húmero tratados con osteosíntesis estable y reconstrucción biológica con aloinjerto mediante una nueva técnica de montaje. **Materiales y Métodos:** La serie incluyó a 33 pacientes evaluados entre 2012 y 2021, 20 mujeres y 13 hombres (edad promedio 65.4 años). El tiempo de evolución de la seudoartrosis recalcitrante era de 33.3 meses. Todos tuvieron un seguimiento promedio de 33.2 meses. **Resultados:** Treinta y dos de los 33 pacientes tratados con esta técnica (97%) tuvieron una consolidación completa y uno, una parcial. El período de consolidación promedio fue de 4.6 meses y el de osteointegración completa del aloinjerto, de 8.1 meses. Para la evaluación funcional se consideraron la escala analógica visual, el puntaje ASES, el puntaje de Constant-Murley y los arcos de movilidad del codo. **Conclusiones:** El manejo de las seudoartrosis recalcitrantes de húmero sigue siendo un dilema y un problema no resuelto aún para los cirujanos experimentados. La combinación entre el uso de un material de osteosíntesis específico sumado al aloinjerto óseo fijado con tornillos aumenta considerablemente la estabilidad mecánica, permite una movilidad precoz, y actúa como un andamio osteoinductor y osteoconductor vital para la consolidación.

Palabras clave: Húmero; seudoartrosis recalcitrante; aloinjerto; diáfisis.

Nivel de Evidencia: IV

Received on April 3rd, 2022. Accepted after evaluation on February 1st, 2023 • Dr. MARTÍN CALOIA • mcaloia@intramed.net  <https://orcid.org/0000-0002-8103-3036>

How to cite this article: Caloia M, Meritano A, González Scotti D, Ronconi S, Serur ME, Caloia H, Chamorro G, Guevara Herrera G, Laboranti A. Recalcitrant Humeral Nonunion: Biological Reconstruction Technique. *Rev Asoc Argent Ortop Traumatol* 2023;88(4):392-408. <https://doi.org/10.15417/issn.1852-7434.2023.88.4.1556>

INTRODUCTION

Humeral diaphysis fractures occur between the upper edge of insertion of the pectoralis major proximally and the supracondylar ridge distally. These injuries constitute 1.2% of all fractures in adults,¹ and have an annual incidence of between 10 and 20 per 100,000 inhabitants.²⁻⁵ In published studies, the incidence of nonunion in humerus fractures varies considerably, from 2% to 10% of conservatively treated fractures, and 15% of operated fractures.⁶⁻⁸ This variance is attributed, in large part, to the unusual vascular contribution of the humeral diaphyseal area, which in 93.8% of cases is represented by a nutrient foramen.⁹ Most foramina are located in three-fifths of the humerus and have a downward direction towards the elbow joint.^{10,11} Fractures located in this segment can damage the nutrient supply and bring problems for consolidation, especially when extrinsic factors or morbidities, or intrinsic factors related to the type of immobilization or fixation used, coexist, altering the ‘diamond concept’ of Giannoudis et al.¹² needed for healing. In this way, the evolution of the fracture can be towards hypertrophic or atrophic nonunion, the latter is the most frequent. Pseudarthrosis of long bones remains a major problem worldwide and that of the humerus is no exception, it is a condition difficult to treat even in expert hands. The term nonunion has been defined in several ways, and there is up to 55% disagreement about the right time to consider it.¹³

The US Food and Drug Administration defines it as a “fracture that is at least 9 months old and has not shown any signs of healing for 3 consecutive months.” Others have recommended that, for long bones, the entity should be considered within a period of six months, during which no signs of radiological consolidation of the fracture are evident.¹⁴ Accordingly, the definition of ‘recalcitrant nonunion’ is even more difficult. According to some authors, it refers to nonunion that does not respond to conventional treatment in any of its variants in patients who have had surgery at least three times over a two-year period.¹⁵ Others, on the other hand, consider them as those that require more than one intervention to heal.¹⁶ In their study of 125 patients, Wiss and Garlich argue that the main risk factors for this type of condition are the number of previous procedures (2 or more), the history of infection and the initial treatment of the fracture.¹⁶ We define recalcitrant nonunion as a fracture that does not respond to conservative or surgical treatment with at least one of the following characteristics:

- for conservative treatment, we take into account the lack of consolidation over a period of two years, in patients without major risk factors, and one year in those with two or more risk factors (mentioned below);
- for surgical treatment, a minimum of two previous operations without clinical and radiological signs of consolidation.

Although numerous studies have been published on the treatment of nonunion when there is no diaphyseal consolidation of the humerus, where surgical reduction and osteosynthesis combined with autologous bone graft is considered the gold standard, little has been written about the difficult scenario that represents the management of recalcitrant nonunion.

The objective of this article is to communicate the clinical and radiological outcomes obtained in a consecutive series of patients with recalcitrant nonunion of the humerus evaluated retrospectively, by prospective treatment with stable internal osteosynthesis associated with biological reconstruction with non-irradiated frozen structured allograft using a telescope technique or a novel ‘Onlay 90°- 90°’ technique of placement, according to the deficit of bone stock and the type of nonunion to be rescued.

MATERIALS AND METHODS

It is a series of 37 patients with recalcitrant nonunion of the humerus, evaluated retrospectively, analytically and descriptively, between 2012 and 2021, in the Hand and Reconstructive Upper Limb Surgery Service, operated on by a level V expert surgeon and a level IV advanced surgeon, from the same surgical team, according to the Tang classification.¹⁷

The following inclusion criteria were considered: 1) patients with recalcitrant nonunion of the humerus, with previous failed conservative treatment or surgery including those with a history of infection, 2) patients with definitive failed treatment by our surgical team and 3) patients with a postoperative follow-up of at least one year. The exclusion criteria were: treatment of nonunion with a different technique from that proposed.

This reduced the sample to 33 patients. In the first evaluation, all consulted for pain and functional impairment.

The series consisted of 20 women and 13 men, with an average age of 65.4 years (range 27-80) They were grouped according to the kinematics of trauma into high-energy (patients <50 years) and low-energy accidents, such as falls from own height (patients >50 years). The progression time of recalcitrant nonunion was 33.3 months (range 3-120). The average number of previous surgeries was 3.28. Patients treated conservatively (15.15%) averaged 31.2 months until surgery (range 12-51) (Tables 1 and 2).

Table 1. Patient demographics

Patient	Age	Time of evolution (months)	Previous interventions	Allograft	Consolidation
CE	79	120	6	Onlay + intercalary	Yes
CO	73	76	3	Onlay	Yes
EA	66	66	2	Onlay	Yes
VO	65	64	5 (Infection)	Onlay	Yes
EI	66	66	9	Onlay + intercalary	Yes
DA	75	51	0	Onlay	Yes
AN	71	59	1	Onlay	Yes
CC	73	59	2	Onlay	Yes
LI	68	59	2 (Infection)	Onlay	Yes
NR	66	52	6 (Infection)	Onlay + Intercalary	Yes
RS	77	50	0	Onlay	Yes
MP	65	36	1	Onlay	Yes
RE	70	72	1	Onlay	Yes
SE	80	19	0	Onlay	Yes
BM	69	24	0	Onlay	Yes
CE	65	14	5	Onlay + Intercalary	Yes
NR	69	12	7	Onlay + Intercalary	Yes
CA	66	12	0	Onlay	Yes
PA	69	12	1	Onlay	Yes
LE	72	4	3	Onlay	Partial
MR	27	11	2	Onlay	Yes
SR	34	3	2	Onlay	Yes
RS	77	24	4	Onlay	Yes
BJ	45	15	2	Onlay	Yes
DJ	46	10	3	Onlay	Yes
MS	47	7	5	Onlay	Yes
TS	68	18	3	Onlay	Yes
BZ	74	16	2	Onlay	Yes
MM	62	18	2	Onlay	Yes
MA	67	14	6	Onlay	Yes
CS	63	12	2	Onlay	Yes
MRI	75	21	5	Onlay + Intercalary	Yes

Table 2. Analysis of data

Quantity	33		
Sex	Female: 20 (60.6%)		Male: 13 (39.4%)
Type of trauma	Low energy: 28 (85%)		High energy (15%)
Laterality	Right: 19 (57.6%)		Left: (42.4%)
Dominance	Dominant: 18 (54.5%)		Non-dominant: 15 (45.5%)
Location	Proximal: 7 (21.2%)	Shaft: 20 (60.6%)	Distal: 6 (18.2%)
Consolidation time	Minimum: 4 months	Average: 4.6 months	Maximum: 7 months
Osseointegration:	Minimum: 7 months	Average: 8.1 months	Maximum: 11 months
Follow-up	Minimum: 12 months	Average: 33.2 months	Maximum: 75 months

The mean follow-up of all patients was 33.2 months (range 12-75) and the clinical evaluation included the Constant-Murley score, visual analog scale (VAS), *American Shoulder and Elbow Surgeons Score* (ASES) and elbow functionality using goniometry. In the treated patient population, different risk factors for the development of this condition were identified (Table 3).

Table 3. Risk factors for recalcitrant nonunion of the humerus

Inherent to the patient	Inherent to the fracture	Treatment
Obesity	Fracture pattern*	Functional Brace*****
Smoking	Location**	Insufficient fixation
Alcoholism	Deforming forces	Number of previous surgeries
Diabetes	Open fractures***	
Use of corticosteroids	Infections***	
Osteoporosis	Third fragment***	
Prior shoulder/elbow stiffness	Pathological fractures***	
Advanced age	Homolateral forearm fracture	
	Magnitude of separation between bone fragments****	

*Ring et al., 2007; Papasoulis et al., 2010; Rutgers and Rings, 2006. **Ekholm et al., 2010. ***Modaber and Jupiter, 1998. ****Neuhaus et al., 2014. *****Toivanen et al., 2005.

The following studies were requested as routine and preoperative planning: comparative anteroposterior and lateral humerus radiographs, preferably digital; computed tomography with 3D reconstruction and 'skip' punch biopsy of the affected segment in cases of doubt or history of infection. In four patients with several previous surgeries (more than 4) and more than one osteosynthesis plate, rapid printing 3D models were used for preoperative planning in order to quantify the bone defect zone and correctly choose the implant and the exact length of the bone graft or non-irradiated frozen structural intercalary allograft. In the remainder, the measurement was performed with the routine preoperative studies requested. If a larger bone resection was necessary because of the infeasibility or doubtful vitality of the ends observed during surgery, planning was modified during the surgical procedure. It should be noted that this *in situ* modification does not create a complication, since, in all cases, a homolateral total humerus allograft is requested.

Radiological evolution was analyzed with digital anteroposterior, lateral and oblique radiographs and computed tomography at 6 weeks, 3, 6 and 9 months.

On the other hand, for rescue surgery with the proposed technique to be successful, we believe that several fundamental factors must be taken into account in planning. For this, we developed the 'hexagon rule' which is very useful for diagnosis and preoperative planning in these difficult scenarios (Figure 1). This scheme takes into account the patient's inherent risk factors, joint stiffness, disuse bone atrophy, range of motion and resorption at the level of the nonunion focus and operculum closure. We believe that the previous analysis of this hexagon allows us to evaluate therapeutic possibilities, choose the best reconstruction technique for each particular case and assemble an intraoperative logical sequence during the technique.

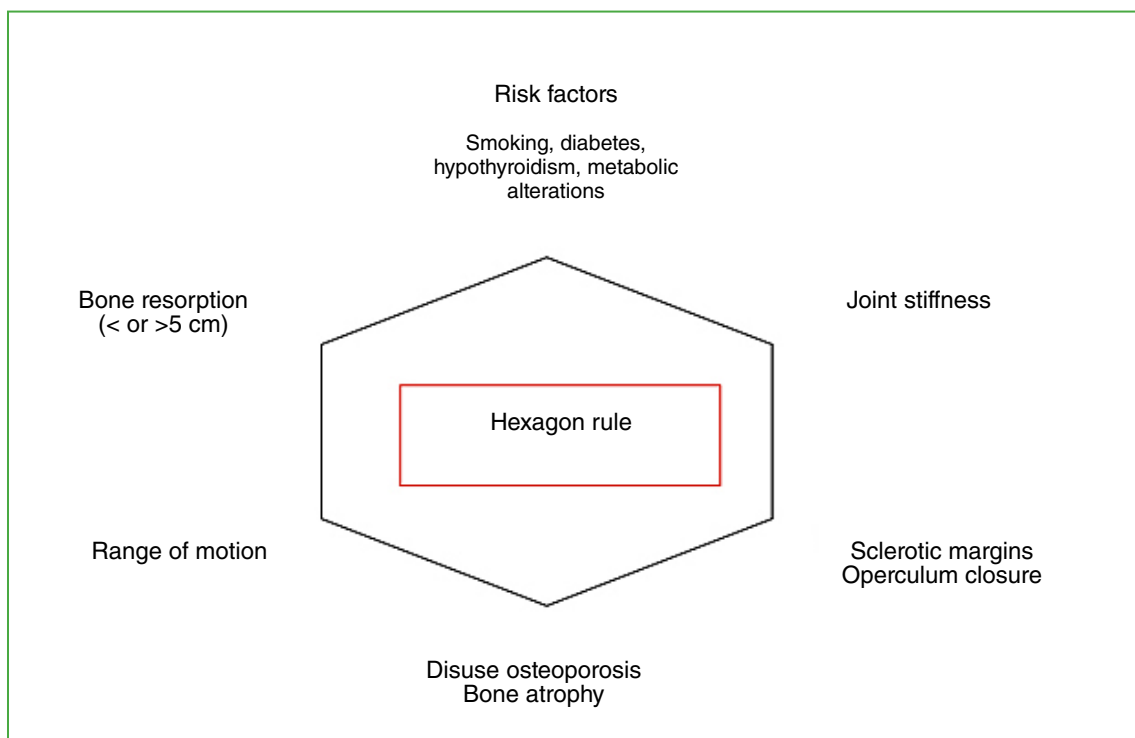


Figure 1. Hexagon rule.

We propose a technique based on three essential principles of fracture treatment:

- Rigid stabilization of fragments
- Stimulation of the osteogenesis process
- Early range of motion exercises.

To these principles, we add Giannoudis' diamond concept.^{18,19}

Surgical technique

As already mentioned, this technique was designed based, firstly, on the classic concepts of diamond healing described by Giannoudis,^{18,19} where the presence of osteogenic cells, osteoinductive mediators and an osteoconductive matrix in the focus is necessary; and secondly, risk factors (summarized with the hexagon rule), where bone stock, disuse osteoporosis and the stiffness of neighboring joints (shoulder and elbow) produce, biomechanically, greater stress at the level of the focus and are common causes of failures in traditional methods. Some published complications due to morbidity of the autologous bone donor zone, such as pain,

functional impairment and bruising, were also considered, especially if the bone stock requirements were large and required hospitalization of certain patients. Through meticulous preoperative planning, two modalities of biological reconstruction can be used as an adjunct to stable internal osteosynthesis according to bone stock deficit and bone quality at the time of intervention. We chose 5 cm of bone defect as a cutting point because we can shorten the limb to that extent without compromising neurovascular structures and obtain a rigid assembly with the technique used, facilitating soft tissue healing and patient tolerance, even though we prefer to maintain anatomical length whenever possible.

Deficit <5 cm in length: biological plate or strut cortical frozen non-irradiated humerus allograft placed in an arrangement we call ‘Onlay 90°- 90°’ associated with ground allograft (canopy technique).

Deficit >5 cm in length: non-irradiated frozen structured allograft of the humerus, intercalary or ‘telescope’ associated with intramedullary ground allograft.

A correct preoperative planning can minimize errors and speed up surgical times (Figure 2).

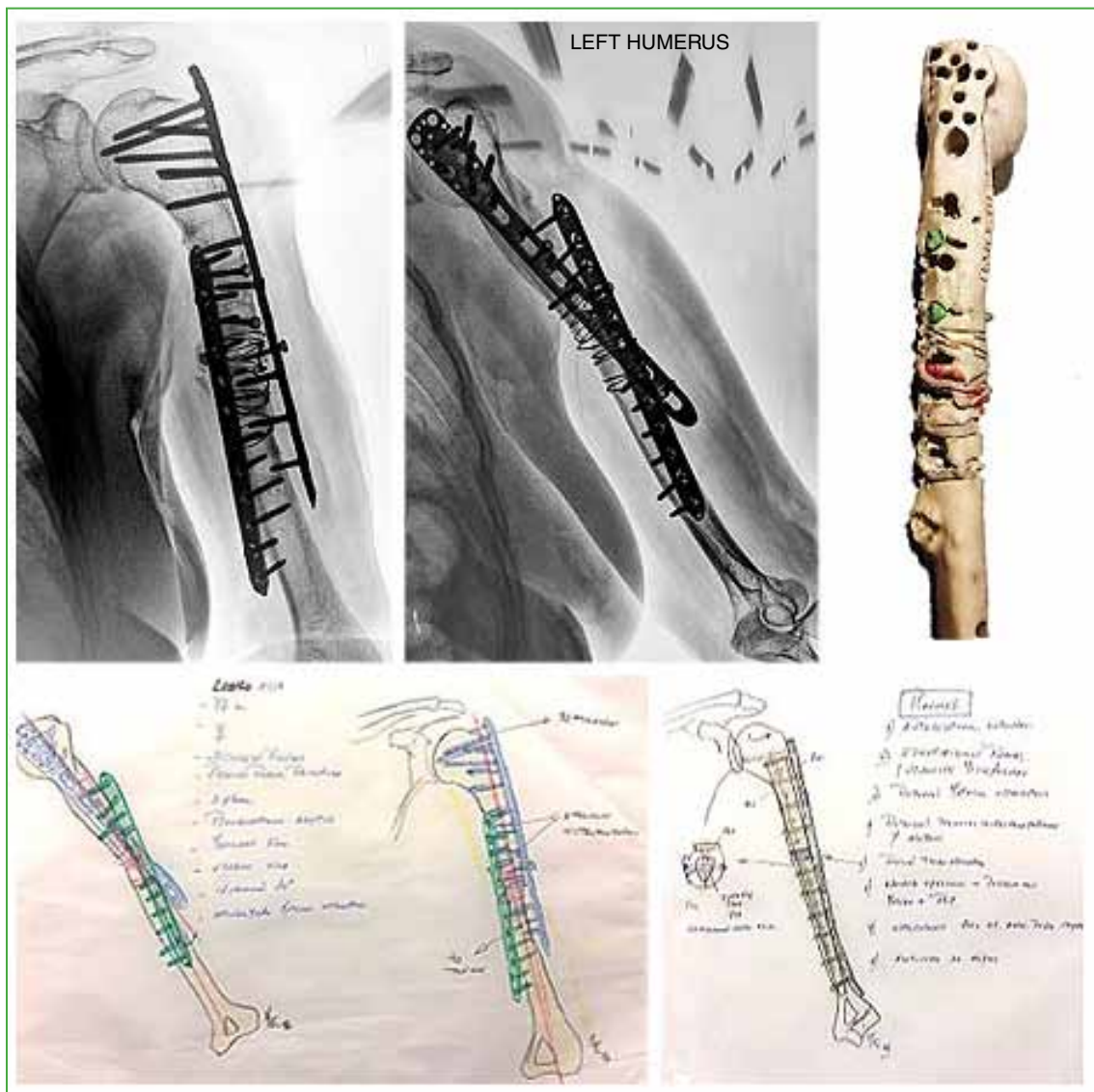


Figure 2. Preoperative planning.

Key sequence and steps

- General anesthesia or plexus block assisted by ultrasound and sedation. Positioning of the patient in the dorsal position at 45° (beach chair position), with the exception of the distal third performed in the ventral or lateral position with a support at elbow level.
- Expanded or posterior deltopectoral approach when nonunion is near the supracondylar region with electro-scalpel (Covidien®) to reduce bleeding and pain, and improve skin aesthetics.
- Frozen or punch biopsy when there is doubt or history of infection (in cases with >5 polymorphonuclear leukocytes per field a cement spacer is made with antibiotic - Masquelet technique).
- Antibiotic prophylaxis 30 min before surgery with 2 g IV cefazolin, followed by a booster dose within 2 hours of starting the procedure.
- Resection of keloid scars, if any.
- Neurolysis and repair of the radial or ulnar nerve under microsurgical magnification. This step can be time consuming especially if the patient has had several previous surgeries or radial nerve neuropraxia.
- Treatment of the nonunion focus: decortication, saucerization of the site without consolidation, resection of bone tissue with macroscopic aspect of necrosis, regularization of ends, alignment (Figure 3).

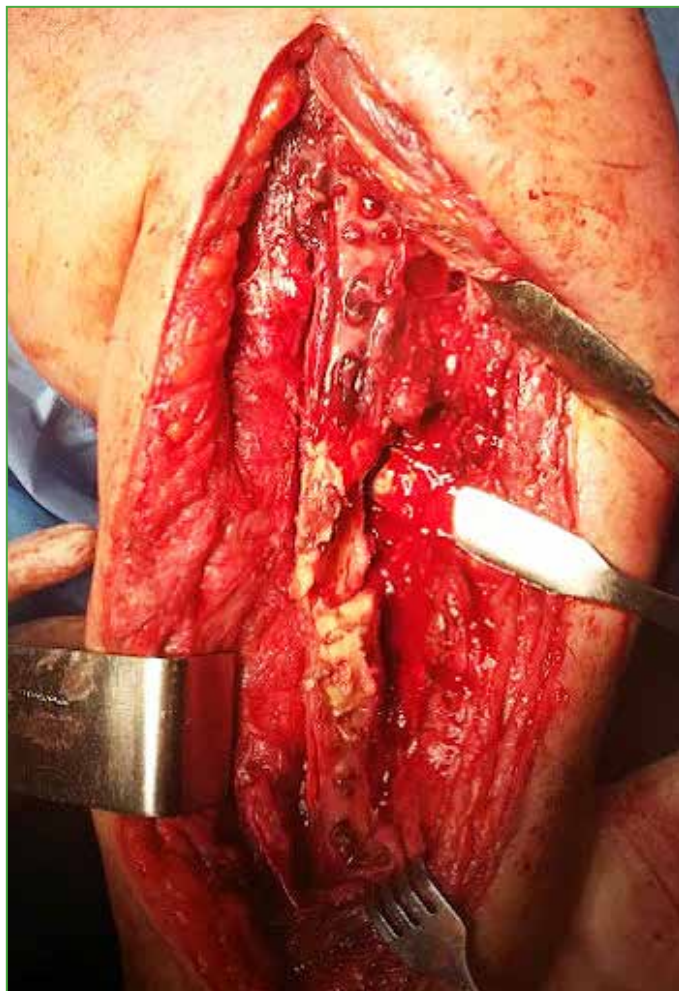

Figure 3. Visualization of the mid-shaft humerus bone stock defect after removal of osteosynthesis material.

- Osteosynthesis: with 3.5/4.5 LC-DCP plate with at least four bicortical screws at each end; Phyllos® type plates or anatomical plates for the lower end of the humerus according to the topography of the recalcitrant nonunion to be treated (Figure 4).

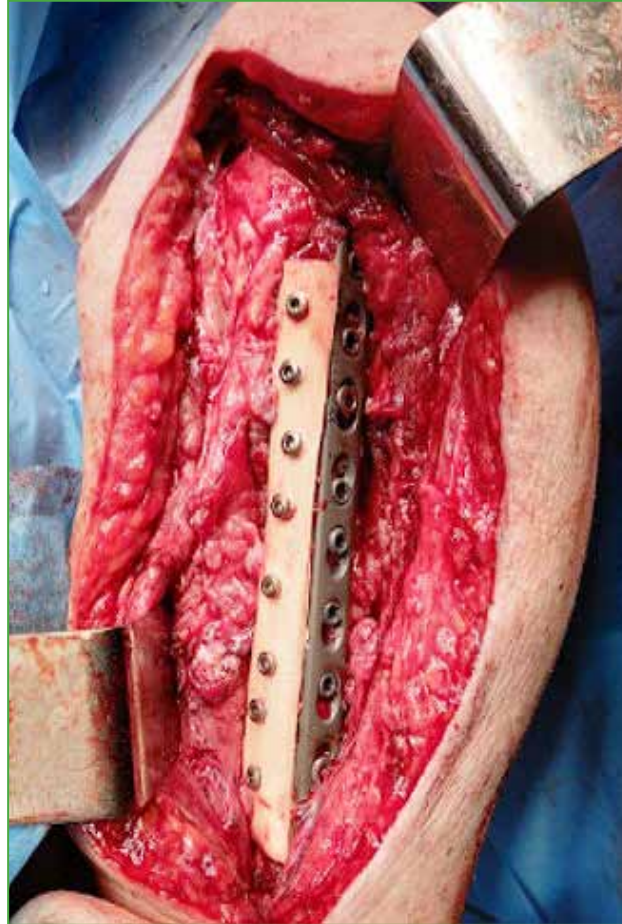


Figure 4. Onlay 90-90° technique. The arrangement of the DCP plate and the structural allograft is observed, which is fixed to the bone with 4.5 mm screws.

In defects <5 cm in length, structural humerus allograft (biological plate) struts of equal length to that of the osteosynthesis plate are used, fixed to the native bone by 3.5/4.5 mm compression screws placed anterior to 90° of the plate that is usually located on the lateral face acquiring a fixation system of 90°-90° ('Onlay 90°-90°'). In this way, a rigid and stable assembly is obtained that allows early range of motion, favors the incorporation of the allograft and prevents its reabsorption (Figure 4). At the native bone-structural allograft interface, a ground allograft is placed in the form of a 'canopy' (Figure 5) to generate greater osseointegration and fill the spaces that may remain at that interface. Figure 6 shows a schematic of the surgical technique when the defects measure <5 cm.

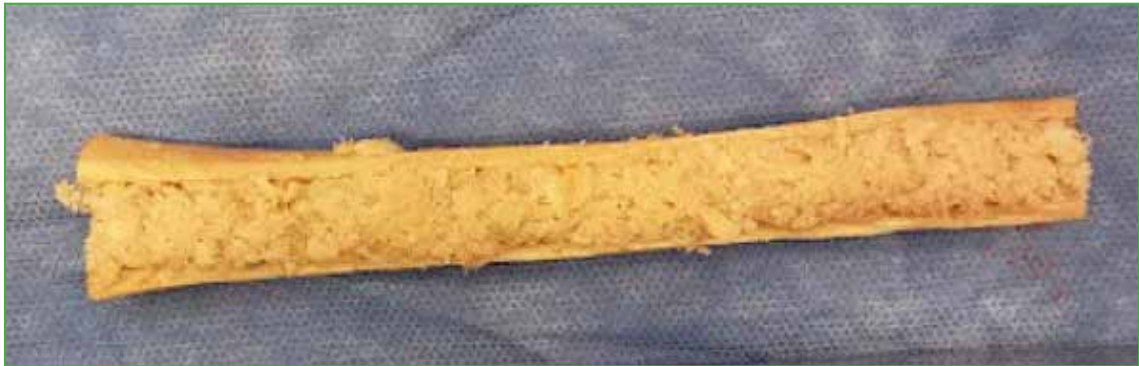

Figure 5. Canopy preparation: arrangement of the ground allograft within the structural allograft in the form of a 'canopy'.

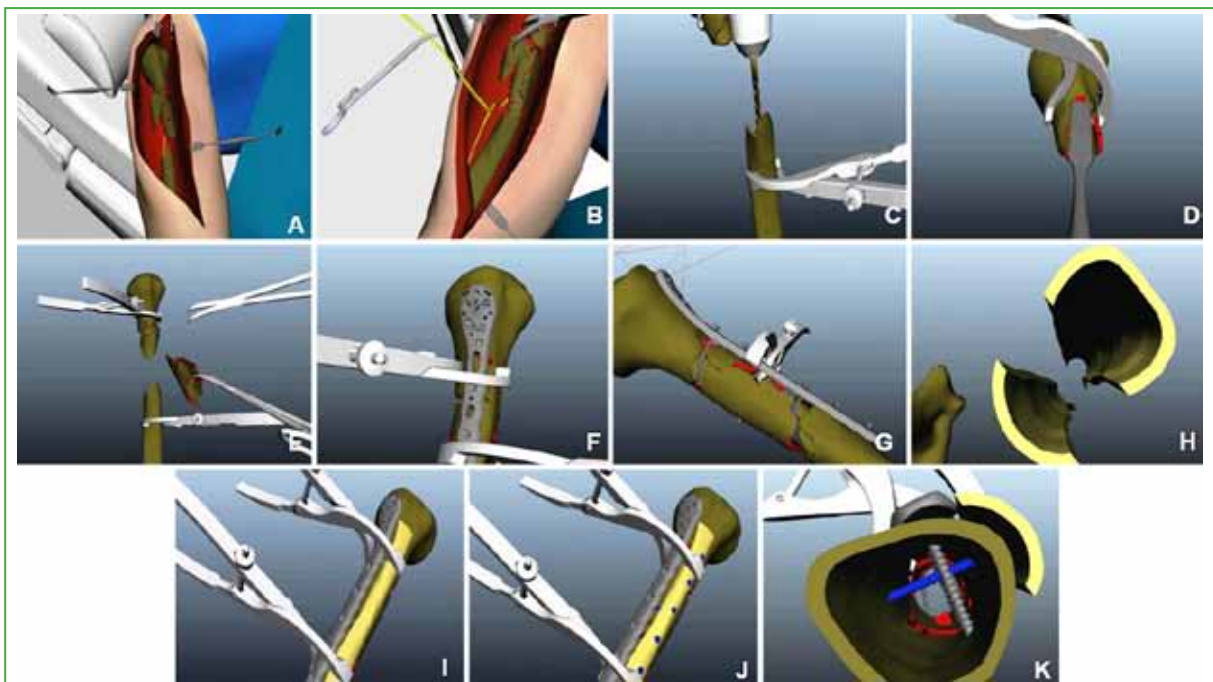


Figure 6. Scheme of the surgical technique. Bone stock deficit <5 cm. 90-90° Technique. **A.** Exposure of the nonunion focus. **B.** Nerve identification. **C.** Treatment of the nonunion focus. **D.** Multiple decortications. **E.** End regularization – Removal of devitalized tissues. **F.** Locking plate placement according to the segment to be treated. **G.** Fixation. **H.** Allograft preparation. **I.** Presentation of the preparation on native bone. **J.** Fixation of the allograft strut to the native bone using screws. **K.** 90°-90° arrangement of screws from an intramedullary view.

In defects >5 cm in length, a frozen non-irradiated humerus allograft is placed in structural intercalary or 'telescope' form to increase the rigidity of the assembly, associated with osteosynthesis in lateral compression of the same characteristics as those used for defects <5 cm and placement of ground allograft in an intramedullary way (Figure 7).

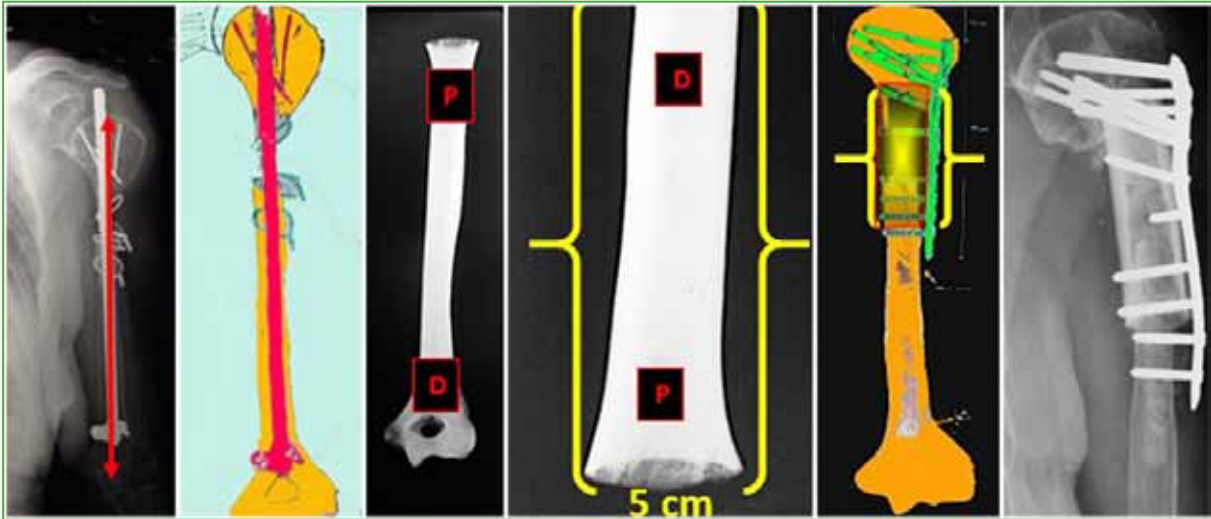


Figure 7. Scheme of the surgical technique. Bone stock deficit >5 cm. 90-90° Technique.

In both techniques, vancomycin 2 g powder is always added to the allograft.

If there is joint stiffness due to immobilization or previous surgeries (shoulder-elbow), an arthrolysis of the glenohumeral or distal joint is performed at the elbow level, a key step to achieve a normal distribution of forces and avoid overloads at the repair site.

Intradermal skin closure is performed, without drainage and usually without static immobilization.

Postoperative antibiotic prophylaxis is not administered.

Rehabilitation protocol

After one week, the protocol of assisted passive range of motion of the shoulder and elbow joint, and treatment of surgical scarring are initiated. From the third week onwards, active range of motion and increased muscle toning exercises are indicated, the exercises should have a progressive controlled load until corroborating the osseointegration by CT scan with metal suppression.

RESULTS

At the last evaluation, 32 of the 33 patients (97%) treated with this technique had complete consolidation; six (18.18%) had been treated with intercalary graft in the 'telescope' form and 27 (81.81%), by allograft strut; in one case, partial consolidation was achieved that did not require a new procedure, because the patient had no symptoms (Table 2).

The period of consolidation observed on CT scan for the presence of bridges of bone trabeculae across the focus of nonunion was 4.6 months (range 4-9). The time required for complete allograft osseointegration is even longer and is around 8.1 months on average (range 7-11) (Figure 8). The average follow-up was 33.2 months (minimum 12, maximum 75).

In two cases, platelet-rich plasma was used as an adjuvant. One was intercalary and the other 'Only 90°-90°'. This method was chosen due to the poor bone quality of the region of the humerus near the focus of consolidation and the number of previous surgeries (more than 7). There was no difference from treatment without platelet-rich plasma in terms of consolidation times, although we believe it is an additional biological contribution.

Patients with more rapid consolidation had fewer previous surgeries (<2), no history of infections and fewer or no comorbidities (<3 risk factors [Table 1]).

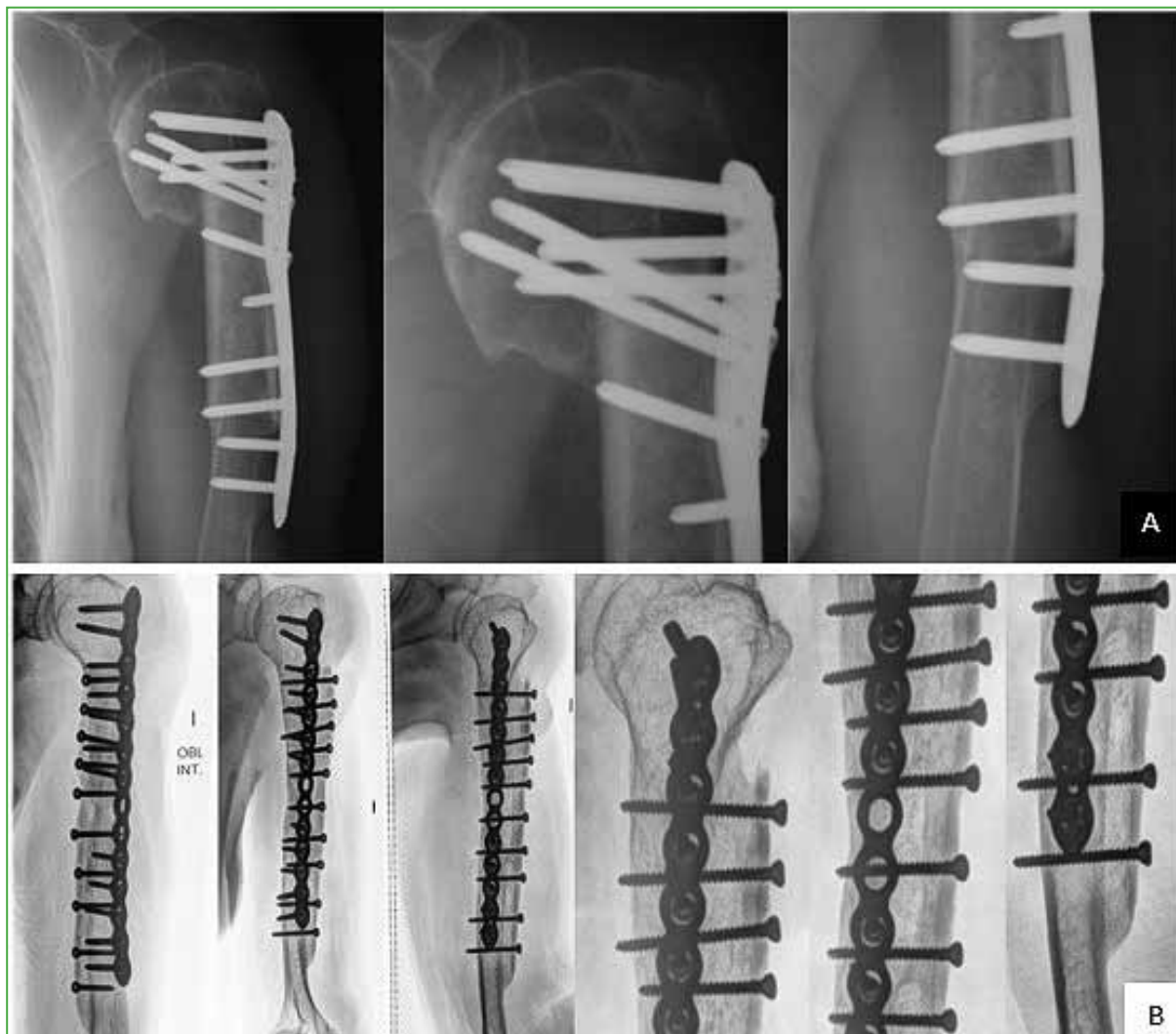


Figure 8. Postoperative control a year after surgery. **A.** Telescope technique for defects >5 cm. **B.** Onlay 90°-90° technique. In both cases, consolidation of the nonunion and complete allograft osseointegration are observed.

Shoulder arthrolysis was performed in seven cases (6 in the proximal humerus and the remaining in the diaphyseal location) and elbow arthrolysis was performed in four cases (distal humerus), no post-surgical infections or radial nerve palsy were recorded. Three patients had suffered a previous infectious condition treated with surgical debridement and intravenous antibiotics. In no case was resection of more than 1 cm of nonunion focus necessary. One patient required a second intervention for material breakage (“Onlay 90°-90°” technique) after a fall from his own height, two months after surgery. The material was removed and a new osteosynthesis was performed with the same reconstruction technique and the final consolidation occurred after nine months. There were no major complications, such as deep or superficial infection, loosening of osteosynthesis material or nerve lesions (radial paralysis), reabsorption or allograft fracture, with any of the aforementioned techniques. As negative outcomes, we must mention the aesthetic defect in some patients, which is directly proportional to the number of previous surgeries but has no impact on interpersonal life; the transient postoperative pain referred to the volume of the implant, which disappears after the ninth month of rehabilitation; and the postoperative hematoma, which may appear with the consequent increased risk of infection if a thorough hemostasis is not performed.

Visual analog scale (VAS), ASES score, Constant-Murley scale and elbow arcs of motion were considered for the functional assessment (Table 4).

Table 4. Preoperative and postoperative clinical evaluation

Clinical evaluation						
	Before surgery	1 month post-op	3 months post-op	6 months post-op	9 months post-op	12 months post-op
VAS	Min.: 7 Max.: 10 Mean: 8.7.	Min.: 3 Max.: 8 Mean: 5.2.	Min.: 2 Max.: 6 Mean: 4.1	Min.: 1 Max.: 5 Mean: 2.2.	Min.: 1 Max.: 3 Mean: 1.3.	Min.: 1 Max.: 3 Mean: 0.9
ASES	Min.: 7 Max.: 15 Mean: 12.3.	Min.: 11 Max.: 19 Mean: 17.1.	Min.: 16 Max.: 23 Mean: 20.2.	Min.: 20 Max.: 25 Mean: 22.5.	Min.: 22 Max.: 27 Mean: 25.4.	Min.: 24 Max.: 30 Mean: 27.1
Clinical evaluation one year after surgery						
Constant-Murley Scale	Excellent: 14 (42.4%)		Good: 13 (39.4%)		Fair: 6 (18.2%)	
Elbow functionality	10-130° 22 patients (66.6%)	15-130° 5 patients (15.1%)	20-115° 3 patients (9%)	30-115°: 2 patients (6%)	40-105°: 1 patient (3%)	

VAS = visual analog scale; ASES = American Shoulder and Elbow Surgeons Score.

According to the VAS, the average preoperative score was 8.7 (range 7-10). One month after the operation, it was 5.2 (range 3-8); at six months, 2.2 (range 1-5); and at 12 months, 0.9 (range 1-3).

Regarding the ASES score, only the patient-reported section was used. The average score was 12.3 (range 7-15) before surgery; 17.1 (range 11-19) after the first month; 22.5 (range 20-25) at 6 months; and 27.1 (range 24-30) after a year.

The postoperative evaluation of shoulder function according to the Constant-Murley scale was performed after one year and yielded the following results: excellent (14 patients; 42.4%), good (13 cases; 39.3%) and fair (6 cases; 18.1%) (Figure 9).

Regarding elbow function, the range of motion was also evaluated at one year, and the results were: 10-130° (22 patients; 66.6%), 15-130° (5 cases; 15.1%), 20-115° (3 cases; 9%), 30-115° (2 cases; 6%) and 40-105° (1 case; 3%).

The poorer outcomes were obtained in those patients whose focus of nonunion was closer to the joint (shoulder/elbow), and when the evolution time was >4 years, with extensive soft tissue compromise or previous infectious process.

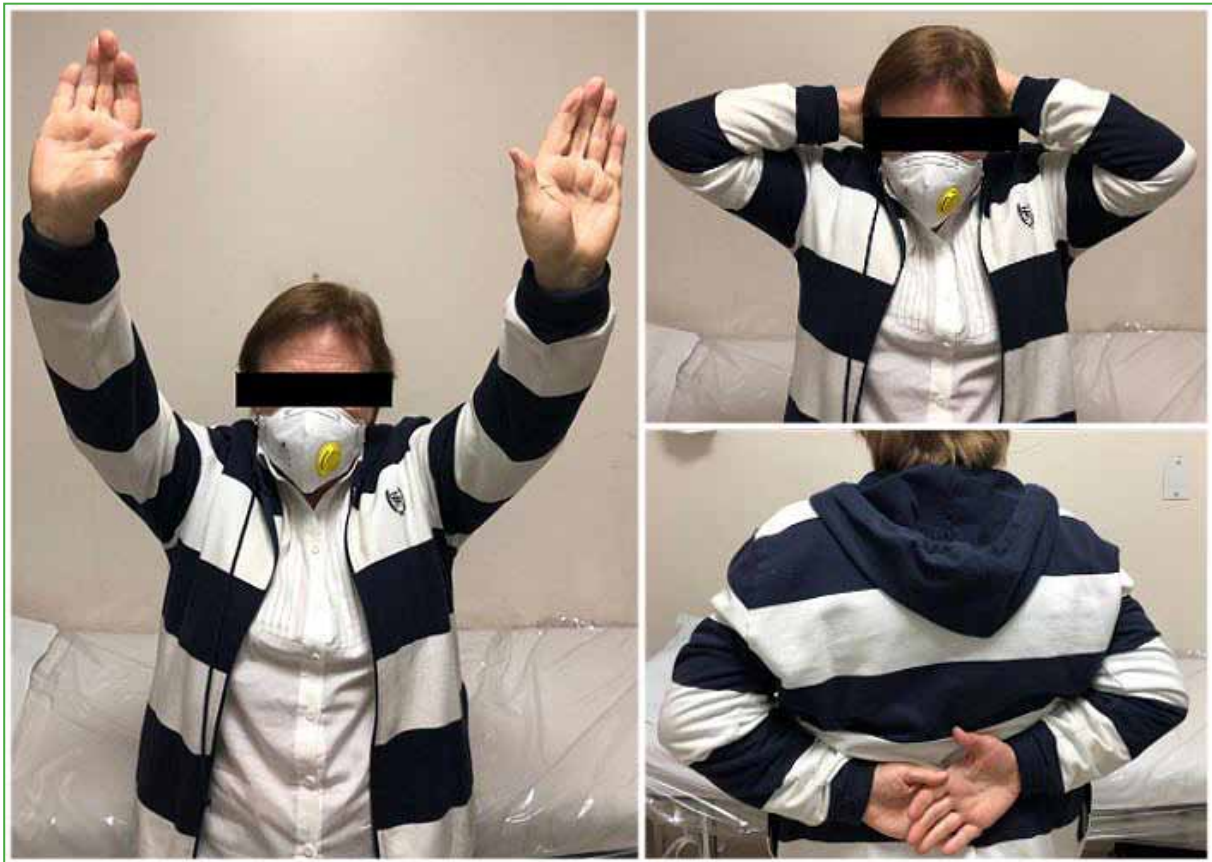

Figure 9. Functional evaluation.

DISCUSSION

Even among experienced surgeons, the treatment of recalcitrant pseudarthrosis of the humerus remains an obstacle and an unsolved challenge. The personal history, the time of disease evolution, and the condition of the soft tissue and bone quality as a result of previous surgeries or disuse make preoperative planning and surgical technique difficult, and the results unpredictable, resulting in a not insignificant rate of complications.

Stable internal fixation and autologous bone grafting remains, for many, the gold standard procedure for the management of humeral nonunion with satisfactory outcomes in terms of consolidation. Its use is not without complications or morbidity, especially from the donor area when grafting is performed in large numbers; in addition, some of these patients require hospitalization to control pain.

At the same time, the allograft has been shown to be useful as a structural and biological contribution, especially advantageous if there are large bone defects, avoiding the morbidity of the donor zone,^{20,21} but with possible risks of infection or reabsorption.

Several authors have described the use of autologous and heterologous grafting in the treatment of humerus nonunion with very good outcomes.

Garbayo Marturet et al. presented five patients >65 years with diaphyseal nonunion of the humerus of more than 18 months of evolution, treated with LCP locking plates, decortication, and ground allograft or autograft, with a 100% consolidation rate. They define recalcitrant nonunion as a major bone defect caused by implant mobilization, a biological factor significantly altered by the loss of vascular supply as a result of multiple in-

terventions, and a functional loss characterized by joint stiffness and muscle and tendon alterations, similar to the Giannoudis diamond concept, regardless of the time since nonunion or the number of previous operations.²²

Campochiaro et al. added the use of platelet-rich plasma to the treatment of nonunion using LCP locking plates and structural allograft, treating nine patients and achieving complete consolidation in an average of seven months.²³

Gogus et al. use structural bone allograft for complex primary fractures of the humerus and femur in patients with osteopenia (mostly elderly) and describe it as a novel idea.²⁴ Unlike in this study, stabilization is performed in parallel. We believe that the “Onlay 90°-90°” arrangement gives more rigidity and better mounting for fixing.

Van Houwelingen et al. treated six patients with a technique similar to one of our suggestions (structural allograft plus rigid osteosynthesis), with the exception that the graft was fixed with plate screws as a 180° ‘sandwich’ (lateral plate plus medial structural allograft) with 100% consolidation in an average of three months.⁹ The difficulty of this technique lies in the placement of the allograft at the level of the medial face of the humerus, since the humeral artery and vein, and the median and ulnar nerves run through this zone. Also, as already mentioned, the parallel placement and not at 90° could be less rigid in certain circumstances.

In a series of 10 patients with humeral diaphyseal nonunion treated similarly to Van Houwelingen, Hornicek et al. obtained a 100% consolidation rate at three months, except for one case at six months, and established that cortical allograft struts provided the structural support and osteoinduction to improve healing of fracture nonunion.²⁵

Marinelli et al. treated 57 patients with diaphyseal nonunion of the humerus using locking plates associated with structural allograft with 93% consolidation. The comparison of the success rates of the various bone fixation techniques is limited by the fact that, in the relatively few published studies, the series are small and heterogeneous; in addition, the highly variable clinical and radiographic presentation of nonunion (mobile-rigid, atrophic-hypertrophic), surgical difficulties (osteoporosis, maintenance of bone stock, presence of fixation devices, shortage of soft tissue and previous scarring) and comorbidities (smoking, alcoholism and obesity) prevent comparison of the different series.²⁶

The association between the use of a special osteosynthesis material for the humerus (Phylos® type plate for the proximal extremity, LC-DCP for the diaphysis and anatomical for the lower end of the humerus), added to the structured bone allograft, either in the form of a bone strut or intercalary telescope, fixed with screws, considerably increases the mechanical stability, this allows an early range of motion, and acts as an osteoinductive and osteoconductive scaffold, helping to reconstruct bone defects and eliminate the increases in tension in the osteosynthesis material that could lead to a failure in the case of a native bone of poor bone quality, and thus has a more even distribution of loads.

The stable internal fixation and lack of irradiation of the bank allograft used in the processing not only prevent reabsorption, but also favor the integration usually observed in our casuistry eight months after the operation. We have not observed infections or rejections in treated patients, but reports of a low rate of disease transmission have been published, and would therefore be one of the weaknesses of using this type of biological input, although we think that this variable has a direct relationship with the quality of processing of the tissue bank. We think that the addition of vancomycin as perioperative prophylaxis along with allograft placement could explain this result in addition to what has already been mentioned. Although levels of consolidation are high with the technique used, functional outcomes vary depending on the location of nonunion, they are poorer the closer it is to the joint, especially the glenohumeral. Despite this, patients have marked symptom relief, the VAS score drops significantly and they resume independence for daily living tasks.

Recalcitrant nonunion of the humerus usually occurs at the diaphyseal level.^{8,16,19,22} There are several risk factors that predispose patients to this type of condition, some of them more preponderant than others. In most cases, it is due to incorrect management of conservative treatment or defects in the surgical technique used in the management of the initial fracture added to the type of patient to be treated. It is critical to consider the ‘hexagon rule,’ which is extremely useful for preoperative planning since it allows for the consideration of aspects that could lead surgical rescues to fail in the approach of this entity.

We present a new surgical technique of biological reconstruction with frozen non-irradiated allograft that has achieved encouraging outcomes, which could address the adverse scenario represented by recalcitrant humeral nonunion.

Like other authors,²¹ we observed that younger patients have a lower consolidation time rate than older patients. Another advantage of allograft use is the possibility of doing it on an outpatient basis. 87.8% of our cases were done under this modality, with immediate monitoring the next day of the procedure. This could be considered an advantage of the method as it reduces hospitalization time and costs, and the possibility of resolution in times such as the recent SARS-CoV-2 pandemic. The use of locking plates in the treatment of this condition is of vital importance, because many cases of nonunion present with poor bone quality, as well as the use of structural allograft that provides additional rigid support.

As strengths of the study, we believe that our sample size is considerable in relation to the prevalence of the disease treated. The results in terms of consolidation and postoperative function are encouraging. The technique proposed in its two modalities is reproducible and offers certain advantages, such as avoiding the morbidity of the patient's own grafting and, in this way, being able to carry out the procedure on an outpatient basis and thus have the possibility of reducing hospitalization costs. In addition, the rigidity of the assembly obtained in the nonunion focus allows to quickly recover the mobility of the limb and thus improve the quality of life of patients, especially those who have been immobilized for more than a year.

On the other hand, it is important to mention that the study has certain weaknesses, such as its retrospective nature, without a control group of patients treated as standard and with a heterogeneous sample, although we think that, due to its frequency, it is difficult to find published comparative studies.

CONCLUSIONS

We present a new technique to treat the difficult and unusual recalcitrant nonunion of the humerus using a non-irradiated frozen structured allograft of the homolateral humerus, by means of two forms of assembly, according to the defect to be treated, associated with a rigid and stable internal osteosynthesis.

In our experience, the addition of ground allograft when using a 'strut' ('canopy technique') in the 'Onlay 90°-90°' configuration or in the 'telescope' form has allowed us to obtain a high rate of osseointegration and, therefore, consolidation, with a rate of excellent and good outcomes in 81.7% of patients. When the location was close to either the glenohumeral or elbow joint, the outcomes were poorer.

The 'hexagon rule' provides relevant information that assists the surgeon in preoperative planning, and that could explain the rate of good outcomes achieved combined with a refined surgical technique.

Conflict of interest: The authors declare no conflicts of interest.

A. Meritano ORCID ID: <https://orcid.org/0000-0001-5419-1859>

D. González Scotti ORCID ID: <https://orcid.org/0000-0001-9564-4834>

S. Ronconi ORCID ID: <https://orcid.org/0009-0000-9562-9976>

M. E. Serur ORCID ID: <https://orcid.org/0009-0009-4222-3724>

H. Caloia ORCID ID: <https://orcid.org/0000-0001-9288-1359>

G. Chamorro ORCID ID: <https://orcid.org/0009-0009-3235-3840>

G. Guevara Herrera ORCID ID: <https://orcid.org/0009-0001-7983-8839>

A. Laboranti ORCID ID: <https://orcid.org/0000-0002-7136-937X>

REFERENCES

1. Court-Brown CM, Caesar B. Epidemiology of adult fractures: A review. *Injury* 2006;37(8):691-7. <https://doi.org/10.1016/j.injury.2006.04.130>
2. Brinker MR, O'Connor DP. The incidence of fractures and dislocations referred for orthopaedic services in a capitulated population. *J Bone Joint Surg Am* 2004;86(2):290-7. PMID: 14960673

3. Ekholm R, Adami J, Tidermark J, Hansson K, Törnkvist H, Ponzer S. Fractures of the shaft of the humerus: An epidemiological study of 401 fractures. *J Bone Joint Surg Br* 2006;88(11):1469-73. <https://doi.org/10.1302/0301-620X.88B11.17634>
4. Tsai C-H, Fong Y-C, Chen Y-H, Hsu CJ, Chang CH, Hsu HC. The epidemiology of traumatic humeral shaft fractures in Taiwan. *Int Orthop* 2009;33(2):463-7. <https://doi.org/10.1007/s00264-008-0537-8>
5. Kim SH, Szabo RM, Marder RA. Epidemiology of humerus fractures in the United States: nationwide emergency department sample, 2008. *Arthritis Care Res (Hoboken)* 2012;64(3):407-14. <https://doi.org/10.1002/acr.21563>
6. Bergdahl C, Ekholm C, Wennergren D, Nilsson F, Möller M. Epidemiology and patho-anatomical pattern of 2,011 humeral fractures: data from the Swedish fracture register. *BMC Musculoskelet Disord* 2016;17(1):1-10. <https://doi.org/10.1186/s12891-016-1009-8>
7. Jupiter JB, von Deck M. Ununited humeral diaphyses. *J Shoulder Elbow Surg* 1998;7:644-53. [https://doi.org/10.1016/s1058-2746\(98\)90016-7](https://doi.org/10.1016/s1058-2746(98)90016-7)
8. Sarmiento A, Zagorski JB, Zych GA, Latta LL, Cappset CA. Functional bracing for the treatment of fractures of the humeral diaphysis. *J Bone Joint Surg Am* 2000;82:478-86. <https://doi.org/10.2106/00004623-200004000-00003>
9. Van Houwelingen AP, McKee MD. Treatment of osteopenic humeral shaft nonunion with compression plating, humeral cortical allograft struts, and bone grafting. *J Orthop Trauma* 2005;19(1):36-42. <https://doi.org/10.1097/00005131-200501000-00007>
10. Murlimanju BV, Prashanth KU, Prabhu LV, Saralaya VV, Pai MM, Rai R. Morphological and topographical anatomy of nutrient foramina in human upper limb long bones and their surgical importance. *Rom J Morphol Embryol* 2011;52(3):859-82. PMID: 21892530
11. Patake SM, Mysorekar VR. Diaphysial nutrient foramina in human metacarpals and metatarsals. *J Anat* 1977;124(Pt 2):299-304. PMID: 591428
12. Giannoudis PV, Einhorn TA, Marsh D. Fracture healing: the diamond concept. *Injury* 2007;38(Suppl 4):S3-S6. [https://doi.org/10.1016/S0020-1383\(08\)70003-2](https://doi.org/10.1016/S0020-1383(08)70003-2)
13. Bhandari M, Fong K, Sprague S, Williams D, Petrisor B. Variability in the definition and perceived causes of delayed unions and non-unions: a cross-sectional, multinational survey of orthopaedic surgeons. *J Bone Joint Surg Am* 2012;94(15):e1091-e1096. <https://doi.org/10.2106/JBJS.K.01344>
14. Fayaz HC, Giannoudis PV, Vrahas MS, Smith RM, Moran C, Pape HC, et al. The role of stem cells in fracture healing and non-union. *Int Orthop* 2011;35(11):1587-97. <https://doi.org/10.1007/s00264-011-1338-z>
15. Zaidenberg C. Pseudoartrosis recalcitrante del húmero distal: injerto óseo vascularizado del radio distal Nueva técnica quirúrgica. *Rev Asoc Argent Ortop Traumatol* 2008;73(1):6-12. Disponible en: https://www.aaot.org.ar/revista/2008/n1_vol73/art02.pdf
16. Wiss DA, Garlich, JM. Healing the index humeral shaft nonunion. *J Bone Joint Surg Am* 2020;102(5):375-80. <https://doi.org/10.2106/JBJS.19.01115>
17. Tang JB, Giddins G. Why and how to report surgeons' levels of expertise. *J Hand Surg Eur Vol* 2016;41(4):365-6. <https://doi.org/10.1177/1753193416641590>
18. Andrzejowski P, Giannoudis PV. The diamond concept for long bone non-union management. *J Orthop Traumatol* 2019;20(1):1-13. <https://doi.org/10.1186/s10195-019-0528-0>
19. Giannoudis PV, Einhorn TA, Schmidmaier G, Marsh D. The diamond concept—open questions. *Injury* 2008;39(Suppl 2):S5-S8. [https://doi.org/10.1016/S0020-1383\(08\)70010-X](https://doi.org/10.1016/S0020-1383(08)70010-X)
20. Lin CL, Fang CK, Chiu FY, Chen CM, Chen TH. Revision with dynamic compression plate and cancellous bone graft for aseptic nonunion after surgical treatment of humeral shaft fracture. *J Trauma* 2009;67(6):1393-6. <https://doi.org/10.1097/TA.0b013e31818c1595>
21. Hierholzer C, Sama D, Toro JB, Peterson M, Helfet DL. Plate fixation of ununited humeral shaft fractures: effect of type of bone graft on healing. *J Bone Joint Surg Am* 2006;88(7):1442-7. <https://doi.org/10.2106/JBJS.E.00332>
22. Garbayo Marturet AJ, Tejero Ibáñez A, Repáraz Padrós FJ, Castaño Serrano A. Tratamiento de la pseudoartrosis recalcitrante de húmero en pacientes de edad avanzada. *Anales Sis San Navarra* 2014;37(2):257-64. <https://doi.org/10.4321/S1137-66272014000200009>
23. Campochiaro G, Baudi P, Gialdini M, Corradini A, Duca V, Rebuzzi M, et al. Humeral shaft non-union after intramedullary nailing. *Musculoskeletal Surg* 2017;101(2):189-93. <https://doi.org/10.1007/s12306-017-0468-x>
24. Gogus A, Ozturk C, Tezer M, Camurdan K, Hamzaoglu A. "Sandwich technique" in the surgical treatment of primary complex fractures of the femur and humerus. *Int Orthop* 2007;31(1):87-92. <https://doi.org/10.1007/s00264-006-0134-7>

25. Hornicek FJ, Zych GA, Hutson JJ, Malinin TI. Salvage of humeral nonunions with onlay bone plate allograft augmentation. *Clin Orthop Relat Res* 2001;(386):203-9. <https://doi.org/10.1097/00003086-200105000-00026>
26. Marinelli A, Antonioli D, Guerra E, Bettelli G, Zaccarelli L, Rotini R. Humeral shaft aseptic nonunion: treatment with opposite cortical allograft struts. *Chir Organi Mov* 2009;93(Suppl 1):21-8. <https://doi.org/10.1007/s12306-009-0007-5>