

Intraoperative Iatrogenic Injury of the Radial Nerve in Humerus Osteosynthesis

Francisco López Bustos, Alexis Fernández, Carlos E. Martínez

Upper Limb Team, Orthopedics and Traumatology Service, Sanatorio Dupuytren, Autonomous City of Buenos Aires, Argentina

ABSTRACT

Introduction: The purpose of this study is to determine the incidence of intraoperative iatrogenic radial nerve injury after osteosynthesis of the diaphysis and distal end of the humerus, identify associated risk factors, and determine the prognostic factors involved in its recovery. **Materials and Methods:** We retrospectively assessed 82 humerus osteosynthesis cases between 2005 and 2021 who had normal radial nerve function before surgery. We evaluated the fixation systems used, the type of surgery (primary versus revision), and the intervals between surgeries. The diagnosis of postoperative radial palsy was made by clinical examination. All patients were treated with wrist extension splint, physiotherapy, and vitamins B1, B6, and B12. **Results:** After humerus fixation, 9 patients developed motor palsy. Seven cases were fixed with plates, one with a cable-plate system, and one with an anterograde locking intramedullary nail. Seven cases (22%) occurred after primary procedures, while two occurred during revisions. Within 6 months, 88% had regained full motor function. In the remaining 22% of patients with definite palsy, electromyography revealed no excitability of the radial nerve. **Conclusions:** The use of an osteosynthesis plate, as well as intraoperative dissection and neu-rolysis of the radial nerve, were identified as risk factors for the development of radial palsy. Reoperations on the humerus, on the other hand, are a risk factor that increases the likelihood of postoperative radial nerve palsy. A radial nerve with no excitability on the postoperative electromyogram has a poor prognosis of spontaneous radial nerve function recovery.

Keywords: iatrogenic; radial nerve; humerus fracture

Level of Evidence: IV

Lesiones iatrogénicas del nervio radial en la osteosíntesis de la diáfisis humeral

RESUMEN

Introducción: Los objetivos de este estudio fueron determinar la incidencia de lesión iatrogénica intraquirúrgica del nervio radial durante la osteosíntesis de la diáfisis y el extremo distal del húmero, distinguir factores de riesgos asociados y reconocer elementos pronósticos que participan de su recuperación. **Materiales y Métodos:** Se evaluaron, en forma retrospectiva, 82 osteosíntesis de húmero entre 2005 y 2021, sin parálisis radial preoperatoria. Se consideraron los sistemas de fijación utilizados, y se compararon las cirugías primarias con las reoperaciones y el tiempo transcurrido entre estas. El diagnóstico de parálisis radial posoperatorio fue clínico. Todos los pacientes fueron tratados con férula en extensión de muñeca, electroestimulación, kinesiología y vitaminas B1, B6, B12. La electromiografía se solicitó a los fines del pronóstico. **Resultados:** Nueve pacientes tuvieron déficit motor del nervio radial en el posoperatorio inmediato. El sistema de fijación era una placa (7 casos), sistema de cable-placa (1 caso) y clavo endomedular acerrojado anterógrado (1 caso). Siete ocurrieron en cirugías primarias y dos en reoperaciones. El 88% recuperó su función motora completamente antes de los 6 meses después de la parálisis. La electromiografía reveló un nervio radial no excitable en el 22% restante con parálisis definitiva. **Conclusiones:** El uso de placa de osteosíntesis, la disección intraoperatoria del nervio radial y las reoperaciones aumentan la incidencia de parálisis. Un nervio radial no excitable se relaciona con un peor pronóstico de recuperación espontánea.

Palabras clave: Iatrogenia; nervio radial; fractura de húmero.

Nivel de Evidencia: IV

Received on July 12th, 2022. Accepted after evaluation on June 10th, 2023 • Dr. FRANCISCO LÓPEZ BUSTOS • lopezbustosf@gmail.com  <https://orcid.org/0000-0002-2504-2026>

How to cite this article: López Bustos F, Fernández A, Martínez CE. Intraoperative Iatrogenic Injury of the Radial Nerve in Humerus Osteosynthesis. *Rev Asoc Argent Ortop Traumatol* 2023;88(4):427-434. <https://doi.org/10.15417/issn.1852-7434.2023.88.4.1622>

INTRODUCTION

As indications for surgical treatment of both fractures and pseudarthrosis of the humerus increase, cases of postsurgical iatrogenic paralysis are becoming more frequent. The incidence of post-surgical radial nerve palsy has been reported to be 5.1%.¹

Radial nerve injuries in humerus fractures are very disabling for performing activities of daily living. Once established, recovery either by conservative treatment or surgery takes no less than six months.²

There is still no consensus on how to approach the treatment of these complications given the diverse responsiveness of the nerve. The multiplicity of implants available today, the large number of techniques for fracture reduction and pseudarthrosis correction, as well as the different approach routes determine that the approach to iatrogenic radial nerve injury is also very dissimilar.

Causes of iatrogenic radial nerve palsy include manipulative trauma during fracture surgery (Figure 1), impingement of the nerve by fragments of the fracture itself, entrapment by the fracture callus, and scar tissue formation.³

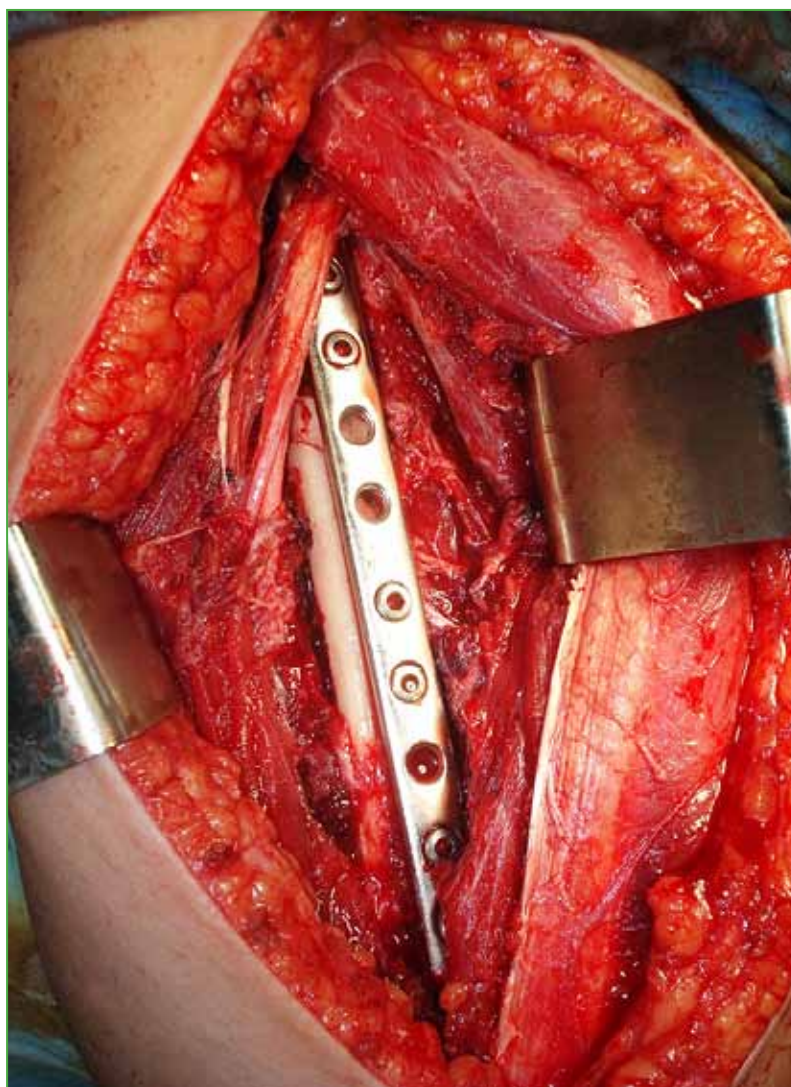

Figure 1. Relationship of the radial nerve with the straight plate on the posterior aspect of the humerus. Treatment of a diaphyseal fracture of the humerus.

The aim of this study was to determine the incidence of intraoperative iatrogenic radial nerve injury in osteosynthesis of the humeral shaft, to distinguish associated risk factors and to recognize the prognostic elements involved in its recovery.

MATERIALS AND METHODS

We retrospectively evaluated 82 osteosyntheses of the humeral diaphysis performed by the same surgeon in 74 adults (mean age 47 years; range 19-89) between June 2005 and March 2023.

Inclusion criteria were: reduction and osteosynthesis of the humerus diaphysis in adults without previous motor injury to the radial nerve. Pediatric patients and those with previous motor injury to the radial nerve were excluded.

The diagnoses were: acute traumatic fractures (63 cases), loosening of the osteosynthesis within 4 months after primary surgery (3 cases), nonunion (14 cases), pathological fracture (1 case) and humerus malunion (1 case).

Traumatic fractures were classified according to the AO classification system.

Twenty-eight acute traumatic fractures corresponded to group A; 27 to group B and eight to group C. In the case of the pathological fracture, the anatomic pathology analysis showed breast cancer metastasis. The malunion had an imbalance of 28° antecurvatum and 18° varus.

The fixation systems used were: plates with screws (57 cases), intramedullary nails (21 cases), spacer with antibiotic cement (2 cases) and cable-plate system (2 cases). Nineteen of the 59 fractures fixed with plates had also been fixed with screws using an out-of-plate compression technique.

Three traumatic fractures were open. The degree of exposure according to Gustilo's classification was: Gustilo I (1 case), Gustilo II (1 case) and Gustilo IIIA (1 case).

The choice of surgical approach and implant was based on patient activity, arm volume and soft tissue status in each particular case.

No osteosynthesis protocol or approach was followed for a particular type of fracture. The wide age range of the patients, the diverse occupational factors, the wide range of surrounding soft tissue injuries, the different medical insurances, the diverse socioeconomic level and, therefore, the access to osteosynthesis elements determined a wide variety of surgical techniques and implants that were chosen by the treating physician according to each patient.

The approaches used for the cases fixed with plates and screws were: trans-tricipital (30 cases), paratricipital (3 cases), deltopectoral extended to the distal third of the arm (14 cases) and lateral MIPO (minimally invasive plate osteosynthesis) (9 cases).

The intramedullary nails were placed anterogradely (17 cases) and retrogradely (4 cases).

The radial nerve was dissected during surgery in 28 cases and there was no evidence of macroscopic injury. Twenty-one surgeries were reoperations (26%).

Radial nerve injury was diagnosed by physical examination when the patient was unable to voluntarily perform wrist and finger extension and thumb abduction (Figure 2).

All patients were prescribed a wrist extension splint (Figure 3), electrostimulation, passive range of motion of the wrist and fingers, and pharmacological treatment with vitamin B1, B6, and B12 tablets once a day for 30 days, as soon as the diagnosis was confirmed.

Until 2014, electromyography was not requested, as this study was only advised if the patient showed no evidence of motor recovery after the third month, which did not occur in the four cases at the time. From then on, it was routinely requested within month after the paralysis occurred. In the evaluation, muscle values of M4 or more of the muscles innervated by the radial nerve were taken as the recovery parameter.

RESULTS

Nine patients (11%) suffered radial nerve motor deficits in the immediate postoperative period after reversal of surgical anesthesia. Four were men and five were women, and the average age was 44 years (range 22-82). The median follow-up was 7.9 months (range 5-15).

The distribution of these nine cases of postoperative paralysis was: seven for primary surgeries (6 operated after acute fractures and 1 for malunion) and two for reoperations (1 for nonunion and 1 for loss of reduction of an acute fracture) (Figure 4). All nine patients reported hypoesthesia in the sensitive territory of the radial nerve.

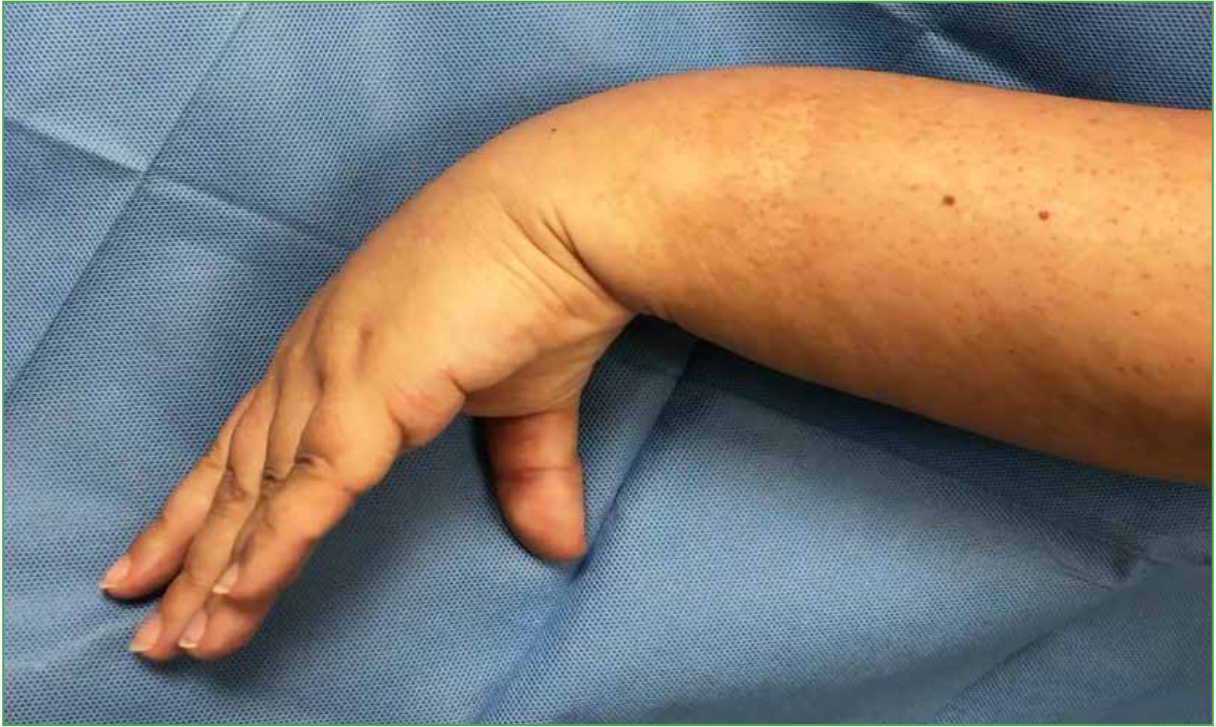

Figure 2. Wrist drop. A characteristic sign of radial nerve palsy.

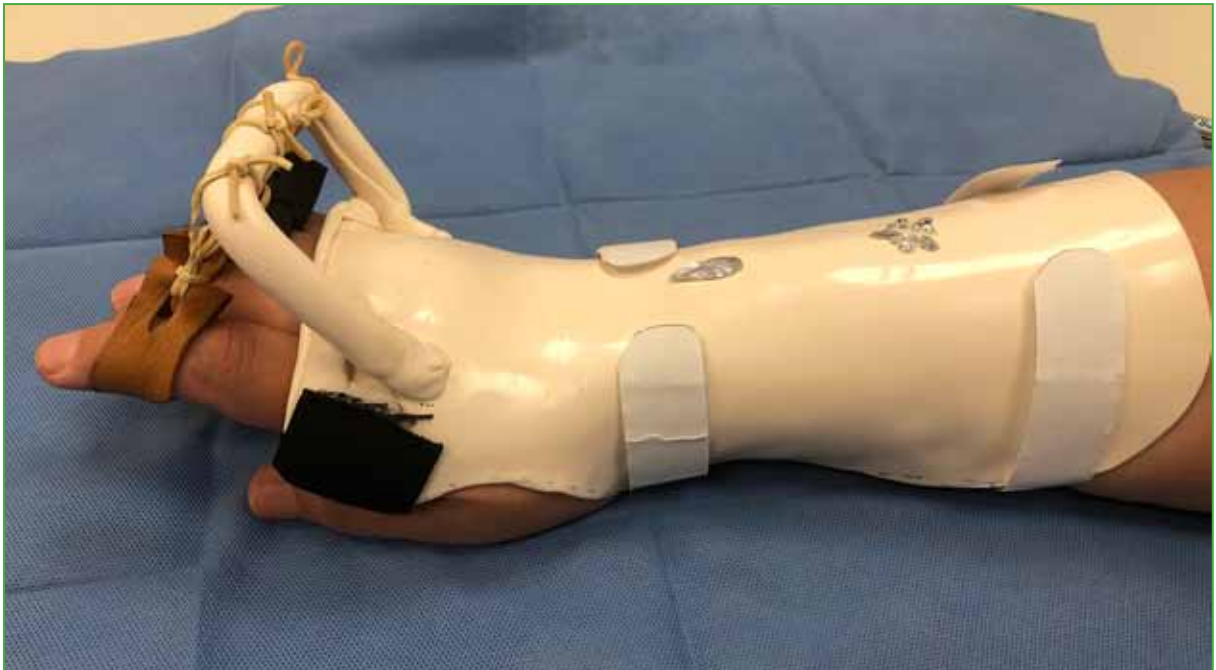

Figure 3. Thermoplastic splint for the rehabilitation of radial paralysis.

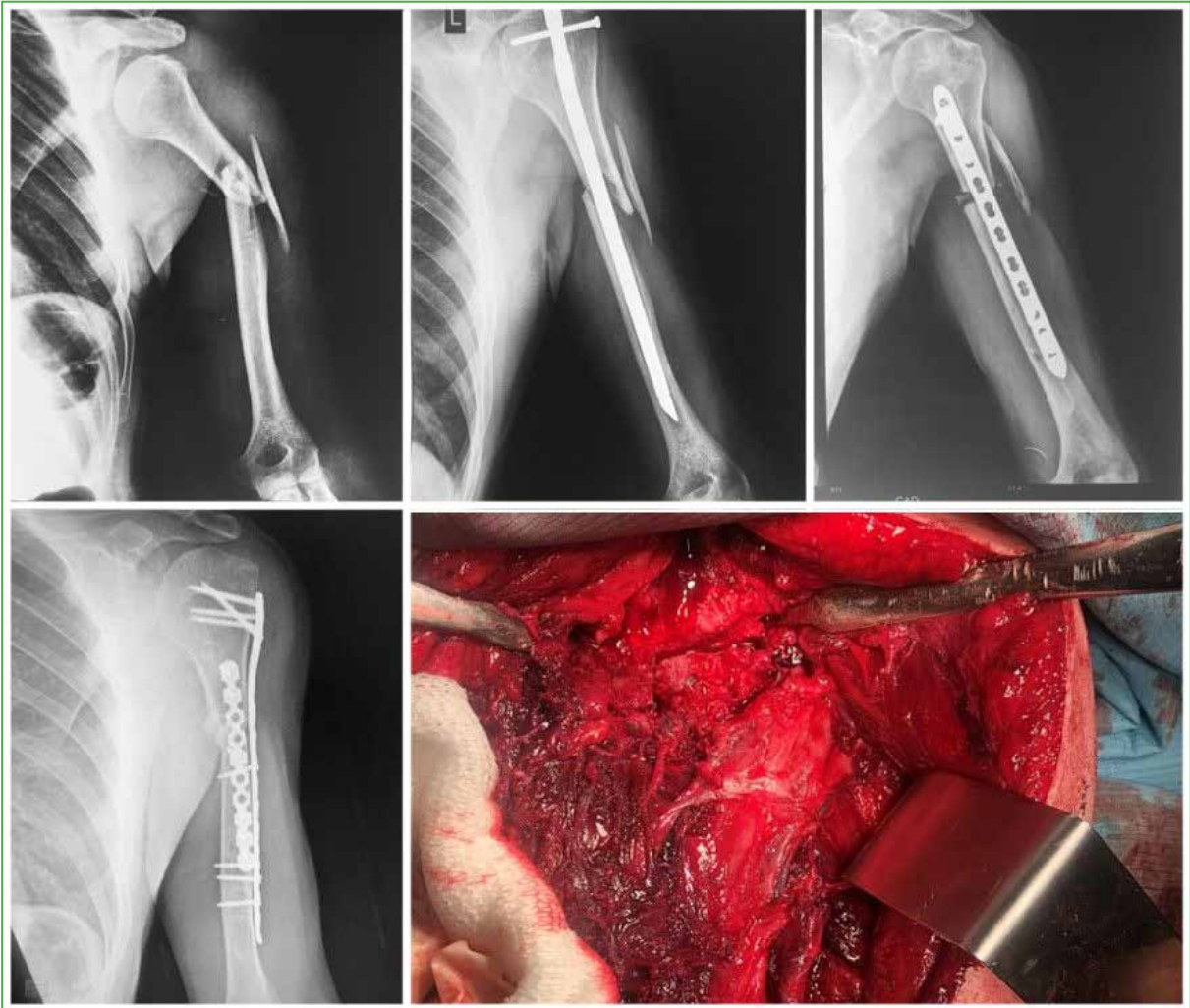


Figure 4. Fibrosis surrounding the radial nerve in a patient with recalcitrant pseudarthrosis of the humerus in whom three methods of osteosynthesis were performed.

As for the cases operated on for acute fractures, five plate osteosyntheses were performed: three with posterior approaches (2 paratricipital, 1 trans-tricipital) and two with minimvasive lateral approaches with an extra large proximal humerus regional locking plate. The remaining case was fixed by means of antegrade locked intramedullary nailing. In two of these patients, the screws were placed using the fragmentary compression technique, which requires greater traction on the soft tissues surrounding the humerus.

Nonunion and malunion occurred after osteosynthesis with a straight plate and a trans-tricipital approach.

On the other hand, in the patient with paralysis after revision osteosynthesis, an extended deltopectoral approach had been performed through the anterolateral aspect of the arm between the anterior and posterior compartments.

The only open fracture without preoperative radial nerve injury and radial nerve palsy after osteosynthesis was a transverse single-pattern diaphyseal fracture, Gustilo and Anderson type 1 (Table 1).

Table 1. Patients diagnosed with iatrogenic radial nerve injury.

Case	Diagnosis	Osteosynthesis used	Approach	Reoperation
1	Malunion	Straight 3.5 mm DCP plate	Trans-tricipital	No
2	Fracture	Extra-long proximal regional plate	Lateral MIPO	No
3	Fracture	Extra-long proximal regional plate	Lateral MIPO	No
4	Open fracture	Regional distal humerus plates	Trans-tricipital	No
5	Fracture	Intramedullary nail	Anterograde	No
6	Fracture	Plates + compression screw	Paratricipital	No
7	Reduction displacement	Cable-plate system	Expanded deltopectoral	Yes
8	Fracture	Plates + compression screw	Paratricipital	No
9	Infected pseudarthrosis	Straight 3.5 mm DCP plate	Trans-tricipital	Yes

MIPO (*minimally invasive plate osteosynthesis*).

Electromyography results one month after injury showed no radial nerve excitability in two cases and moderate radial nerve injury with partial reinnervation in the remaining four cases. Electromyography was not repeated when any of these patients showed any sign of motor recovery.

Four of the nine patients with postoperative paralysis had undergone primary surgery for radial nerve exploration and neurolysis, in which nerve indemnity was found (cases 2, 3, 8 and 9). These four patients recovered full motor and sensory function after electrostimulation treatment at 5, 3, 6 and 8 months, respectively (Table 2).

Table 2. Prognostic factors for recovery from iatrogenic radial nerve injury.

Patient	Intraoperative examination of the radial nerve	Electromyography	Recovery
1	No	No	Yes
2	No	No	Yes
3	Yes	No	Yes
4	No	Non-excitability radial nerve	No
5	No	Non-excitability radial nerve	No
6	No	Moderate radial nerve injury	Yes
7	No	Moderate radial nerve injury	Yes
8	Yes	Moderate radial nerve injury	Yes
9	Yes	Moderate radial nerve injury	Yes

The nine patients with iatrogenic radial nerve palsy were evaluated over a period of eight months (range 5-15). Seven recovered nerve function in an average of 6.5 months (range 3-9) by treatment with electrostimulation, joint mobility and vitamin B, with a value of M4 (6 cases) and M5 (1 case). Radial nerve exploration and neurolysis was not performed in any of the nine cases as treatment of postoperative paralysis.

Motor recovery began at 1.71 months (range 1-3). Two patients had no motor recovery at the time of follow-up. One underwent tendon transfers, but the other, who was already over the age of 80, declined such treatment.

DISCUSSION

At follow-up, 78% of iatrogenic radial nerve palsies reversed spontaneously. Plate osteosynthesis of the humerus diaphysis, intraoperative radial nerve neurolysis and reoperations represent a risk factor for the development of radial nerve motor palsy.

The radial groove is a crucial region of the radial nerve for the development of paralysis. In this segment, the nerve changes its location from posterior to lateral, makes intimate contact with the diaphysis of the humerus and the aponeurosis of the vastus lateralis, and thus decreases its elongation capacity. In this segment, the nerve is less mobile. Therefore, any elongation produced there will cause a sudden stretching of its neural sheath and its inner fascicles, thus producing, depending on the intensity, a greater or lesser interruption in the transmission of motor electrical impulses, which manifests itself in paralysis.⁴

Osteosynthesis of the humerus raises the risk of radial nerve injury, usually due to traction, but sometimes also due to pressure from a spacer, exposure or damage of a wick or the implant itself. The radial nerve is at risk in the middle third of the humerus with a posterior or lateral approach to the radius and in the distal third of the humerus with an anterolateral exposure. When the paralyzed radial nerve is anatomically intact, the chances of total restitution are high.⁵

In multiple studies, the rate of iatrogenic radial nerve palsy has been found to be higher with diaphyseal plate fixation compared to nail fixation.^{5,6}

In terms of treatment, there is no agreement on whether and when it is advisable to surgically examine the nerve.⁷

In other series, a high rate of spontaneous recovery has been reported in patients with primary iatrogenic injury: the expectant management strategy seems to be widely accepted, and early nerve exploration is only recommended in special situations, for example, if the fracture is open.

In contrast, opinions differ on the need for early nerve exploration in patients suffering from radial nerve palsy after initial surgical fixation of the humerus. While some authors recommend early exploration, others advocate an observation period of 4-6 months.⁷ Following the latter concept, surgical exploration was not performed in those patients who developed postoperative paralysis. Seventy-eight percent of the patients in our sample who developed iatrogenic radial nerve palsy recovered their motor function completely. The first sign of wrist extensor contraction was observed between the first and third month after the diagnosis of paralysis, without the need for further surgery.

The placement of a screw with an interfragmentary compression technique for humerus diaphyseal fractures requires the use of instruments (drill bit, soft tissue protector and motor) which, due to their dimensions, can cause traction of the radial nerve and the subsequent development of neuropraxia. Nineteen of the 59 fractures fixed with plates and screws were also fixed with screws using a compression technique. Two of these 19 cases (10.5%) developed radial nerve neuropraxia.

Because of scar tissue formation, the development of postoperative paralysis is less likely after revision surgery performed, at most, 10-14 days after initial surgery than 3-4 months after primary surgery.⁸ The rate of postoperative paralysis in our patients undergoing reoperations was 11% (2 cases in 21 reoperations) at an average of 224.55 days from primary surgery. These two patients were reoperated 458 and 53 days, respectively, after surgery.

Beyond the evolution of the implants, the rate of development of paralysis after osteosynthesis remains considerable (11%).

A factor in the development of such paralysis is the use of a plate compared to any other method of osteosynthesis, as well as the dissection and intraoperative neurolysis of the radial nerve. Secondly, reoperations on the humerus are a risk factor that increases the possibility of developing postoperative radial nerve palsy.

We did not find a relationship with age, type of fracture, presence of pseudarthrosis, or compressive screw placement.

The absence of clinical signs of motor recovery after three months of established paralysis, combined with a non-excitability radial nerve on postoperative electromyography, is associated with a poor prognosis for spontaneous radial nerve function recovery. We suggest nerve exploration in these cases.

Conflict of interest: The authors declare no conflicts of interest.

A. Fernández ORCID ID: <https://orcid.org/0000-0001-9237-113X>

C. E. Martínez ORCID ID: <https://orcid.org/0000-0002-6031-0532>

REFERENCES

1. Paris H, Tropiano P, Clouet D'orval B, Chaudet H, Poitout DG. [Fractures of the shaft of the humerus: systematic plate fixation. Anatomic and functional results in 156 cases and a review of the literature]. *Rev Chir Orthop Reparatrice Appar Mot* 2000;86:346-59. [En francés] PMID: 10880934
2. Shao YC, Harwood P, Grotz MR, Limb D, Giannoudis PV. Radial nerve palsy associated with fractures of the shaft of the humerus: a systematic review. *J Bone Joint Surg Br* 2005;87:1647-52. <https://doi.org/10.1302/0301-620x.87b12.16132>
3. Edward P, Kurth L. Postoperative radial nerve paralysis caused by fracture callus. *J Orthop Trauma* 1992;6:234-6. <https://doi.org/10.1097/00005131-199206000-00017>
4. Claessen FM, Peters RM, Verbeek DO, Helfet DL, Ring D. Factors associated with radial nerve palsy after operative treatment of diaphyseal humeral shaft fractures. *J Shoulder Elbow Surg* 2015;24(11):e307-11. <https://doi.org/10.1016/j.jse.2015.07.012>
5. Cagnet JM, Fabre T, Durandeu A. [Persistent radial palsy after humeral diaphyseal fracture: cause, treatment, and results. 30 operated cases]. *Rev Chir Orthop Reparatrice Appar Mot* 2002;88:655-62. [En francés] PMID: 12457110
6. Huerta Lazcarro J, Luna Pizarro D. [A comparison of the prevalence of radial nerve lesion after fixation of humeral shaft fractures with dynamic compression plate versus intramedullary nailing]. *Acta Ortop Mex* 2008;22:287-91. [En español] PMID: 19227933
7. Liu GY, Zhang CY, Wu HW. Comparison of initial nonoperative and operative management of radial nerve palsy associated with acute humeral shaft fractures. *Orthopedics* 2012;35(8):702-8. <https://doi.org/10.3928/01477447-20120725-10>
8. Schwab TR, Stillhard PF, Schibli S, Furrer M, Sommer C. Radial nerve palsy in humeral shaft fractures with internal fixation: analysis of management and outcome. *Eur J Trauma Emerg Surg* 2018;44(2):235-43. <https://doi.org/10.1007/s00068-017-0775-9>