

Use of Masquelet Technique for the Reconstruction of Bone Defects in the Ankle. Case Report

Fernando Vago Anaya, Juan Ignacio Crosa, Mauro A. Goveo, Emiliano Loncharich, César Á. Pesciallo

Foot and Ankle Sector, Orthopedics and Traumatology Service, Hospital Británico de Buenos Aires, Autonomous City of Buenos Aires, Argentina.

ABSTRACT

Segmental bone defects in the foot and ankle represent a challenge due to their anatomical characteristics, limited vascularization, and poor muscle coverage. The technique described by Masquelet has shown excellent results for the treatment of segmental bone defects in long bones. However, there are few studies in the literature on its use in the foot and ankle. The induced membrane technique offers a valid treatment alternative to solve bone defects. It allows treatment without the need for complex procedures, such as vascularized bone grafts or distraction osteogenesis, with a high rate of consolidation, preserving the length and function of the limb. Although we cannot prove that this procedure is the most indicated for the treatment of bone defects, we can affirm that all our patients have achieved consolidation, which encourages us to continue performing this same technique.

Keywords: Bone defect; foot and ankle; distal tibia; Masquelet technique.

Level of Evidence: IV

Reconstrucción de defectos óseos en la región del tobillo mediante la técnica de Masquelet. Presentación de casos

RESUMEN

Los defectos óseos segmentarios en la región del tobillo y el pie representan un desafío dadas sus características anatómicas con limitada vascularización y pobre cobertura muscular. La técnica descrita por Masquelet para el tratamiento de defectos óseos segmentarios en huesos largos ha logrado excelentes resultados. Sin embargo, se han publicado pocos estudios sobre su uso en la región del pie y tobillo. La técnica de la membrana inducida ofrece una alternativa terapéutica válida para resolver problemas de difícil solución en Ortopedia, como los defectos óseos. Permite tratarlos sin necesidad de procedimientos complejos, como el uso de injertos óseos vascularizados o de callotaxis, con una alta tasa de consolidación, conservando la longitud del miembro y con una buena función. Entre enero de 2016 y diciembre de 2018, tres pacientes con defectos óseos segmentarios fueron tratados mediante la técnica de Masquelet en nuestra institución. Pese a que no podemos probar que este procedimiento es el más indicado en este tipo de casos, sí podemos afirmar que se logró la consolidación en todos los pacientes y se resolvió el defecto óseo, lo que nos anima a seguir utilizando esta misma técnica.

Palabras clave: Defecto óseo; pie y tobillo; tibia distal; técnica de Masquelet.

Nivel de Evidencia: IV

INTRODUCTION

The anatomic region of the ankle is a major challenge for the treatment of segmental bone defects (SBD) due to its limited vascularity and poor soft tissue coverage.^{1,2} Among the main techniques for reconstruction are distraction osteogenesis, vascularized fibular grafting, intramedullary nail elongation, and trabecular titanium implants.^{3,4} These are surgically complex and demanding procedures with unpredictable and potentially catastrophic outcomes.⁵⁻⁷

Received on July 27th, 2023 Accepted after evaluation on February 14th, 2024 • Dr. FERNANDO VAGO ANAYA • fervagoanaya@gmail.com

 <https://orcid.org/0000-0001-8589-7782>

How to cite this article: Crosa JI, Vago Anaya F, Goveo M, Loncharich E, Pesciallo CA. Use of Masquelet Technique for the Reconstruction of Bone Defects in the Ankle. Case Report. *Rev Asoc Argent Ortop Traumatol* 2024;89(2):164-175. <https://doi.org/10.15417/issn.1852-7434.2024.89.2.1800>

Masquelet described a new technique for the treatment of SBDs.⁸ This procedure allows reconstruction of the bone surface, without the need for microsurgical skills or highly complex hospital infrastructure.⁹⁻¹⁴ In the first stage, a polymethylmethacrylate cement spacer is placed, which generates a foreign body reaction, with the subsequent development of an induced biological membrane. The spacer is removed in the second stage, which can be performed 6 to 10 weeks later, and the resulting cavity is filled with an autologous bone graft. The biomembrane's function is not just to prevent graft resorption and soft tissue interposition, but it also secretes growth factors that aid in bone consolidation.¹⁵⁻¹⁸

The purpose of this article is to present a series of patients with bone defects in the ankle region who were treated with the Masquelet technique, as well as to describe the technique's various applications in this region.

CLINICAL CASE 1

A 40-year-old man, with no relevant medical history, who had suffered an exposed fracture of the right tibial plafond in a car accident.

The initial treatment included surgical lavage, extensive debridement, and stability with a transarticular external ankle fixator.

After two weeks, a lateral fibula osteosynthesis was performed and, given the severe joint comminution, it was decided to maintain the distal tibia with a transarticular external fixator to recover bone stock, maintain length and consider a deferred tibiotalar arthrodesis.

Three months following the initial trauma, an ankle arthrodesis was performed using a specially designed anterior plate and cannulated screws to connect the metaphysis and tibial epiphysis to the talus, as well as ground bone allograft from our hospital's bone bank.

The soft tissue evolution was positive; nevertheless, there was a delay in tibiotalar fusion.

At 11 months after surgery, radiographs showed tibial plate fatigue associated with tibiotalar nonunion, and physical examination revealed movement at the fusion site (Figure 1).

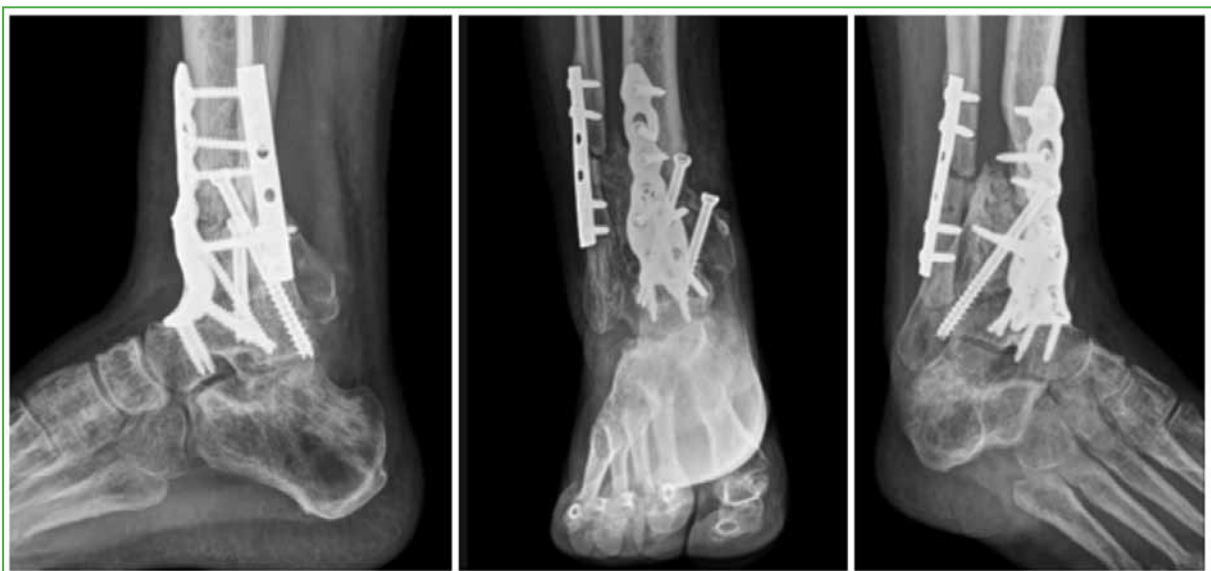

Figure 1. Anteroposterior, lateral and oblique ankle radiographs showing pseudarthrosis of a distal tibia with a failed ankle arthrodesis.

Complete laboratory tests were requested and the results were within normal values: white blood cell count 8500/mm³ (normal value: 4000-10,000/mm³), C-reactive protein 0.9 mg/dL (normal value: 0.8-1.2 mg/dL) and erythrocyte sedimentation rate 12 mm (normal value: 8-20 mm).

Because of the suspicion of infection caused by a lack of consolidation, implant fatigue, and prolonged pain, a two-stage revision using Masquelet's principles was decided.

In the first stage, an anteromedial approach of the distal tibia was used to confirm the absence of bone graft integration at the fusion level, and a lateral approach was used to confirm the lack of consolidation at the fracture site in the fibula. Both tibia and fibula implants were removed, and an extensive surgical debridement of the bone and soft tissue was conducted, which was observed as devitalized and bleeding, until bleeding ends were obtained in both ends. Following lavage, bone and remnant tissue samples were collected for culture and pathological examination. A bone defect was created around the metaphysis, tibial epiphysis, and talar dome.

The remaining bone defect (5 cm) was filled with two doses of cement with 2 g of vancomycin per dose, after stabilization with a retrograde tibiototalcalcaneal nail (Figure 2).

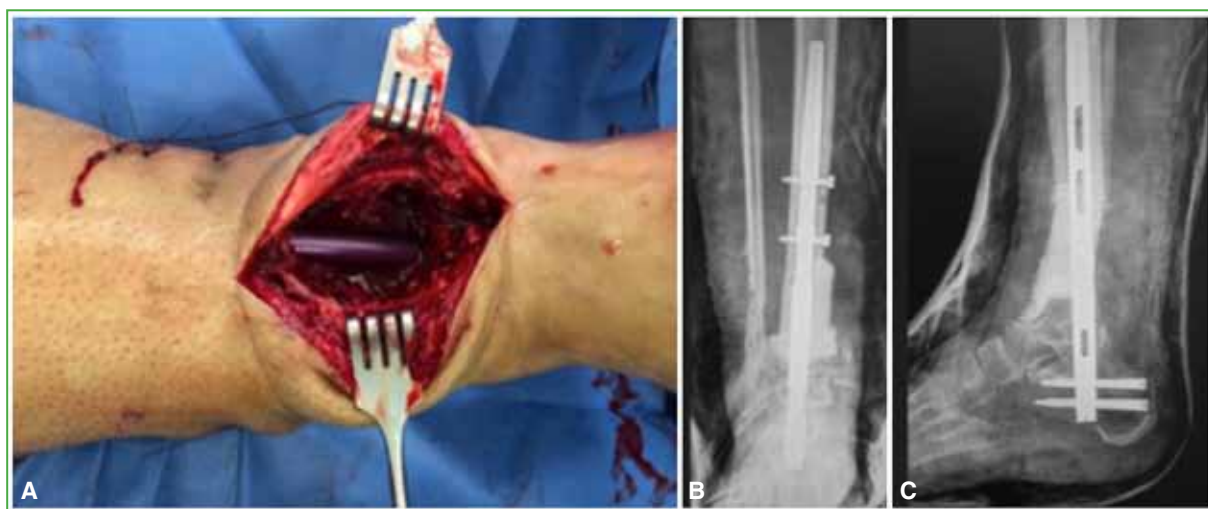


Figure 2. A. Intraoperative image of bone resection and stabilization with intramedullary nail. B and C. Anteroposterior and lateral ankle radiographs after the first surgical stage.

Cultures were positive for methicillin-sensitive *Staphylococcus aureus* in both bone and soft tissue.

The infection resolved after eight weeks of treatment with rifampicin and ciprofloxacin, as determined by sensitivity tests. For this reason, we proceeded with the second half of the Masquelet technique.

An anteromedial approach was performed through the previous scar. Once it was determined that the tissues were vital, Masquelet's membrane was incised and the antibiotic-loaded cement was completely removed. Finally, the remaining bone defect was filled with equal halves of ground allograft from the bone bank and autograft (obtained from the iliac crest) (Figure 3).

The remaining bone was sampled for culture and pathological anatomy, both of which yielded negative results. In any event, and given the patient's history, it was determined to complete one month of antibiotic treatment during the postoperative period, as recommended by the Infectious Diseases Department.

The rehabilitation protocol consisted of six months without weight bearing and immobilization with a walker boot and crutches. The patient then continued with progressive, crutch-assisted support. Full weight-bearing was authorized 11 months after the second surgical stage.

Serial clinical and radiographic controls were performed. At 13 months following the second operation, radiographic fusion was verified, and unassisted walking was authorized with a return to normal life (Figure 4).

After two years of follow-up, the patient walks unaided and without pain in the operated limb.

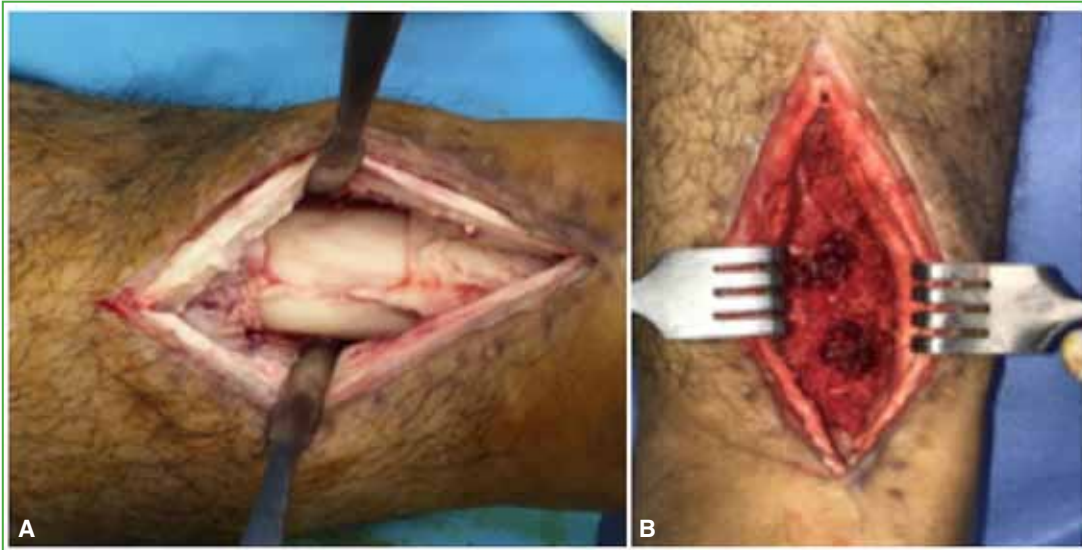


Figure 3. **A.** Intraoperative image of the second surgical stage (spacer). **B.** Filling of the bone defect.

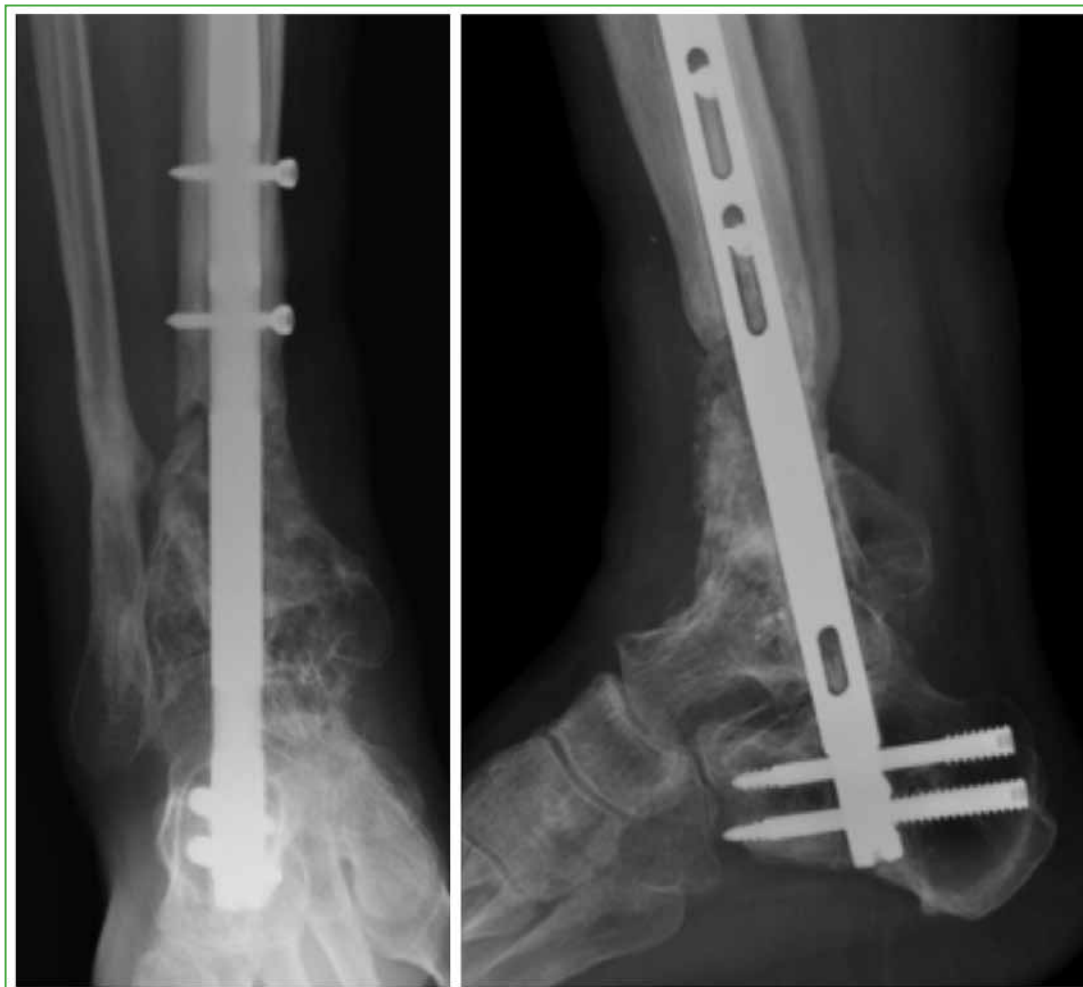

Figure 4. Anteroposterior and lateral ankle radiographs, 11 months after the second surgical stage.

CLINICAL CASE 2

A 47-year-old man with a clinical history of arterial hypertension, who had sustained a talus fracture in a motorcycle versus car accident in 2015 and had been treated with open reduction and internal fixation with retrograde screws and a medial plate.

Postoperatively, he suffered partial necrosis of the talar body and pseudarthrosis of the neck associated with the development of subtalar osteoarthritis, for which, in 2017, he underwent revision osteosynthesis with subtalar arthrodesis, at our institution. Three years later, he was still in pain and walked with the aid of a crutch.

Due to the persistence of pain, periodic and exceptional radiographic controls revealed pseudarthrosis of the talar neck fracture, avascular bone necrosis of the talar body, and a lack of consolidation of the subtalar arthrodesis, as well as the development of tibiotalar osteoarthritis.

With a preliminary diagnosis of infected pseudarthrosis based on prolonged pain, implant fatigue, and lack of consolidation, Masquelet's guidelines were used as the basis for a two-stage revision. In the first surgery, an extended medial approach was performed over the surgical scar. The osteosynthesis was removed, a bony sequestrum was discovered at that level, samples were collected for culture, and extensive debridement was performed until vital, bleeding bone was retrieved.

A defect was created around the talar body, tibial articular surface, and medial malleolus. Culture samples were collected from tibia and talus remnant bone, as well as soft tissue containing superficial fascia and anterior tibial tendon sheaths.

The calcaneus was stabilized with the tibia using a retrograde tibiocalcaneal nail, which kept the limb's length, and the defect was filled with two doses of cement containing 2 g of vancomycin each (Figure 5). In cultures, *Staphylococcus epidermidis* was isolated from distal tibia bone tissue.

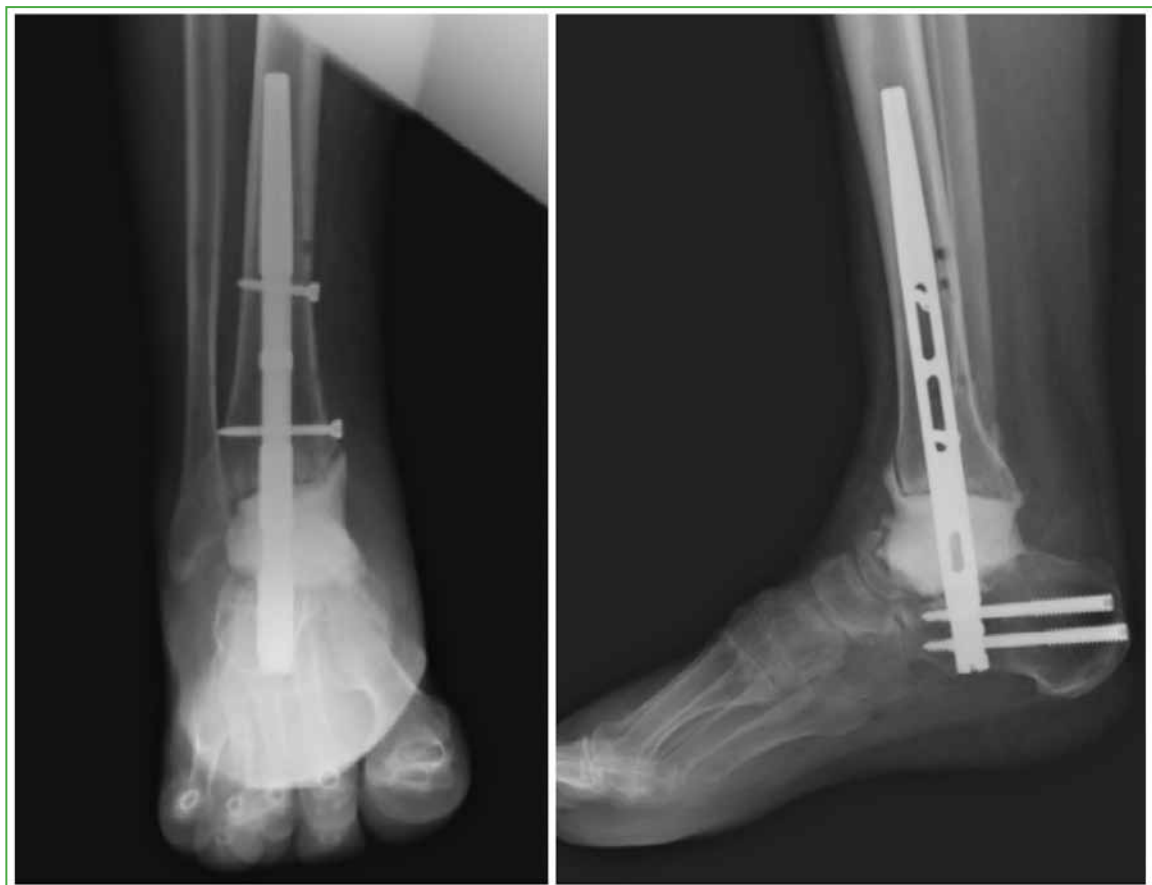

Figure 5. Anteroposterior and lateral ankle radiographs two months after the first surgery for pseudarthrosis of the talar neck plus necrosis of the talar body.

The infection resolved after nine weeks of treatment with levofloxacin and rifampicin, as determined by sensitivity tests.

Ten weeks following surgery, with the infection properly treated, it was agreed to proceed with the second surgical stage. The anterior scar was approached and, after visualizing that the tissues looked vital and bleeding, Masquelet's membrane was incised. All antibiotic-loaded cement was removed, the residual bone ends were treated, and samples were collected for culture and pathological anatomy, which were both negative. Finally, the remaining bone defect was filled with equal halves of autologous bone (obtained from the iliac crest) and ground allograft.

Antibiotics would not be administered beyond the second stage, as agreed upon by the Infectious Diseases Department.

Complete consolidation was observed 12 months after surgery (Figure 6). The rehabilitation protocol included six months of non-weight bearing immobilization with a walker boot, followed by six months of partial weight bearing with a walker boot and two crutches after the second surgical stage.

The patient achieved full unassisted weight bearing at 14 months after the second surgical stage.

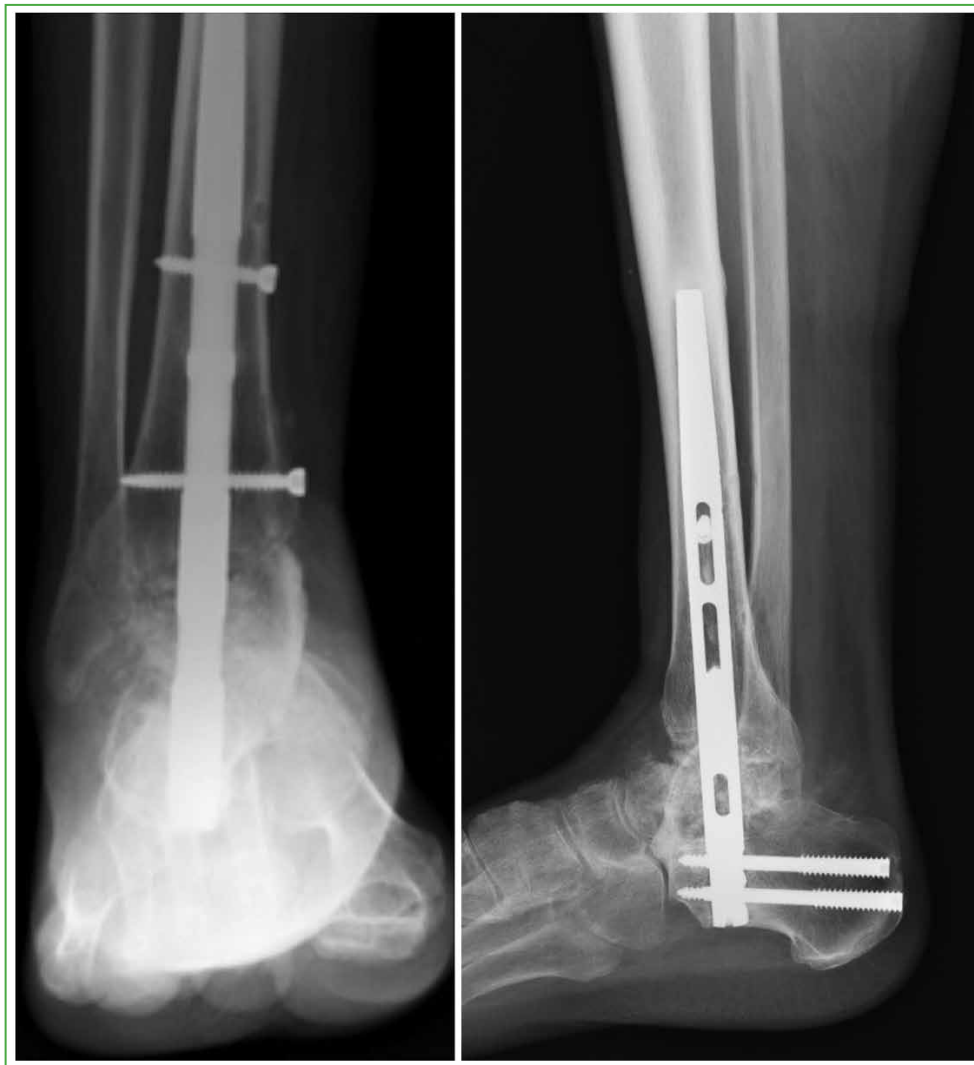

Figure 6. Anteroposterior and lateral ankle radiographs, eight months after the second surgical stage.

CLINICAL CASE 3

A 61-year-old man, with no relevant medical history, who had undergone left ankle arthroplasty for primary osteoarthritis in August 2017, at another institution. He developed an acute prosthetic infection, necessitating two surgical debridements one month after surgery. He received antibiotic treatment for three months, and the final cultures from both surgical debridements were negative.

He developed an anterior soft tissue coverage defect, which was treated with VAC® negative pressure wound therapy, resulting in wound closure nine months following the initial postoperative period.

The patient consulted our institution one year after surgery due to persistent pain in the left ankle. Physical examination revealed a limited and painful range of motion. The wounds were healed, with no signs of active infection.

The radiographs showed an alteration of the structure compatible with loosening of the prosthesis (Figure 7).

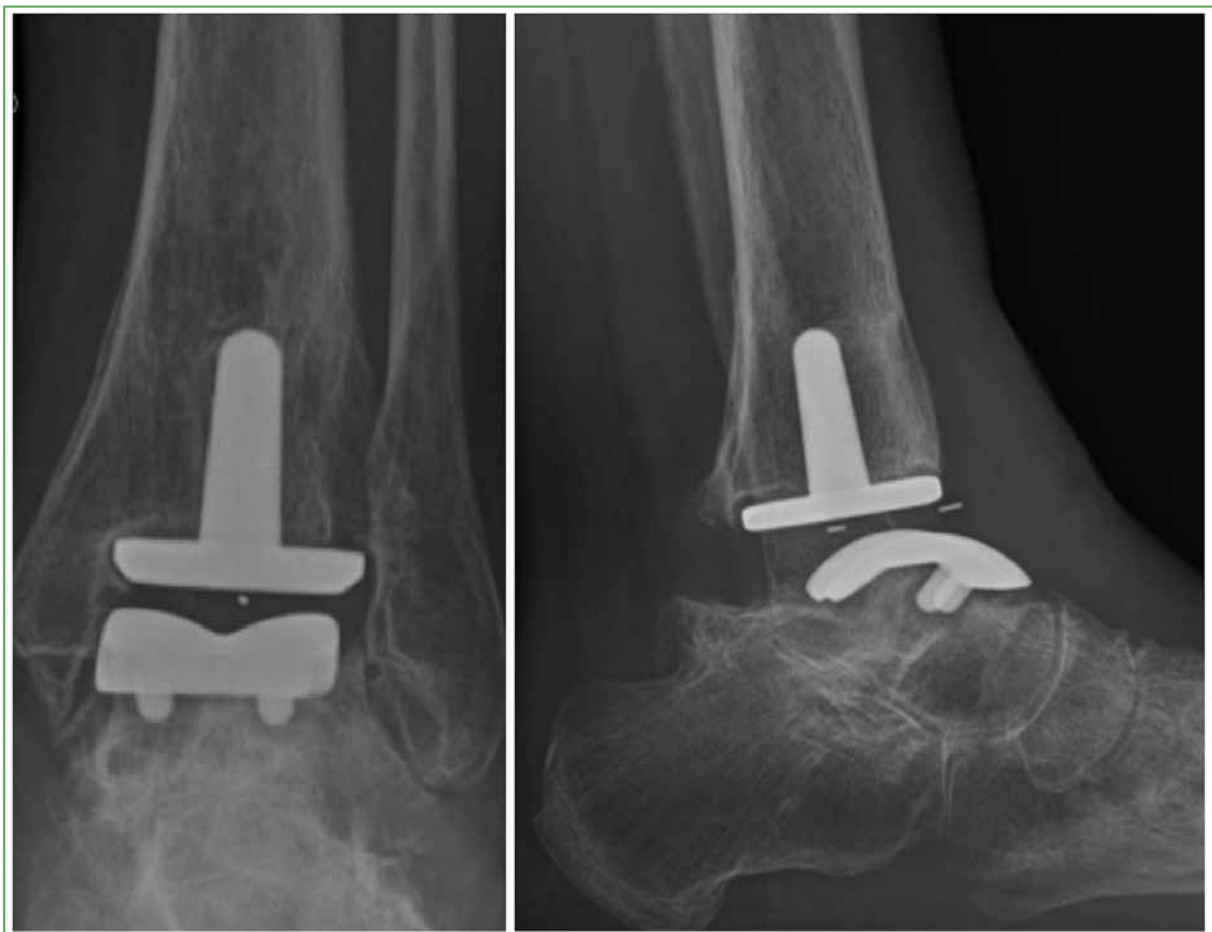


Figure 7. Anteroposterior and lateral ankle radiographs, one year after surgery. Loosening of the prosthesis is observed at the level of the tibia and talus.

Given the suspicion of septic loosening due to an infection history, a soft tissue coverage defect for nine months, and pain persistence at one year and three months, Masquelet's guidelines were adopted to direct a two-stage revision.

In the first surgery, an extended anterior ankle approach was performed over the surgical scar. The prosthesis components were removed, remnant bone samples were taken for bacteriological study and debridement was performed until vital and bleeding bone was obtained. A 2.5 cm remnant bone defect was noted. Distraction was performed to maintain the length of the limb and a tibiototalcalcanal nail was placed retrogradely. The bone defect was filled with two doses of cement containing 2 g of vancomycin per dose (Figure 8).

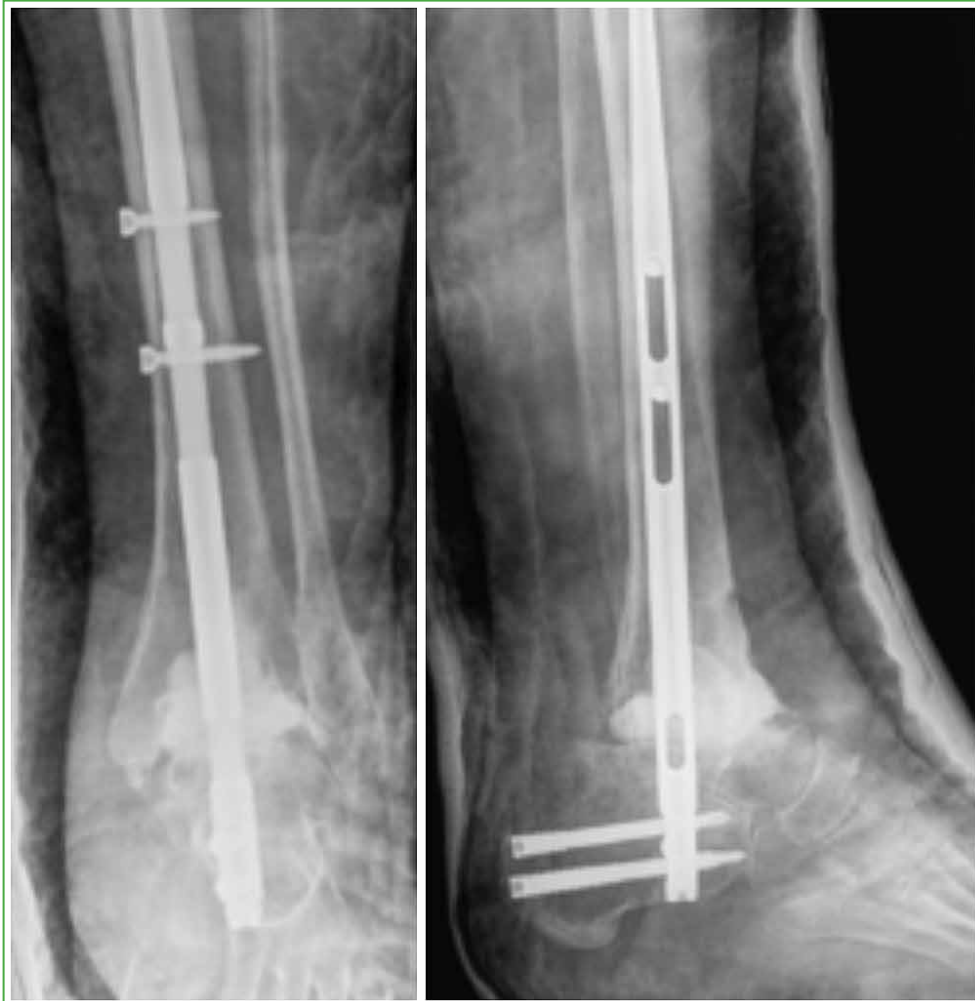

Figure 8. Anteroposterior and lateral ankle radiographs taken in the immediate postoperative period. Note the stabilization with a retrograde tibiototalcalcanal nail and the antibiotic-loaded cement that fills the bone defect.

After 10 weeks of treatment with minocycline and ciprofloxacin, and negative cultures, it was decided to continue with the second Masquelet stage.

The approach was made through the surgical scar. After observing that the tissues had a vital and bleeding appearance, Masquelet's membrane was incised and all the antibiotic-loaded cement was removed. Remnant bone samples were collected and yielded negative results. Finally, the bone defect was filled with equal halves of autologous bone (from the homolateral iliac crest) and ground allograft from the bone bank.

The patient was immobilized with a cast boot for three weeks and then continued with a non-weight-bearing walker boot. Progressive partial weight bearing began at three months protected with a walker boot and two crutches. Consolidation was achieved eight months after surgery. 9.5 months after the second surgery, the patient was able to bear full weight on his limb without help (Figure 9).

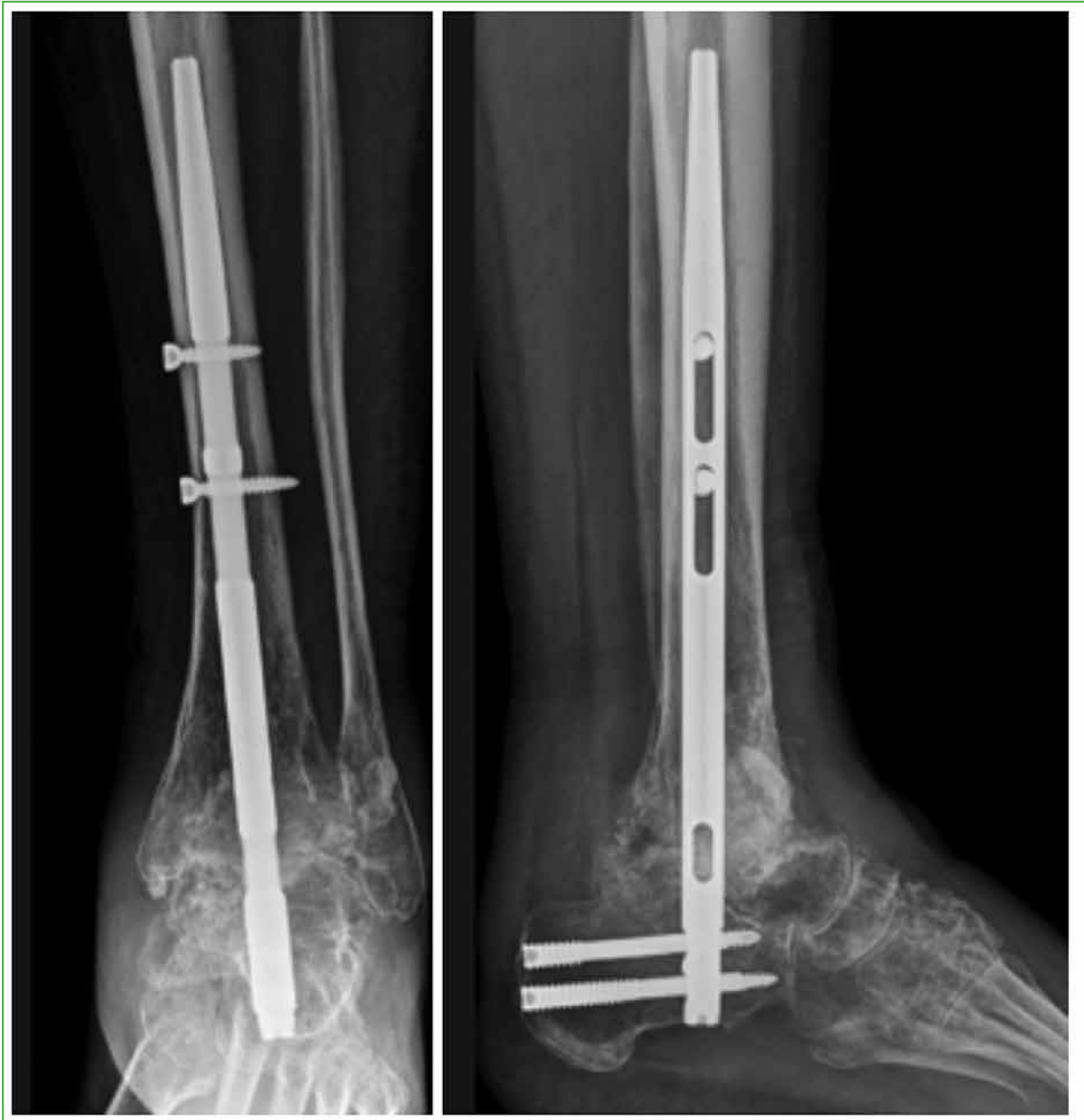

Figure 9. Anteroposterior and lateral ankle radiographs, one year after surgery. The consolidation and integration of the graft can be visualized.

DISCUSSION

SBD in the ankle and foot region represents a challenge due to its anatomical characteristics, limited vascularization, and poor muscle coverage.^{1,2} Excellent outcomes have been obtained with the technique described by Masquelet for the treatment of SBDs in long bones.^{9,10,12-14} However, there are few studies on its use in the foot and ankle region.

There are numerous causes for the generation of SBD in this region. Although most published studies correspond to defects secondary to open fractures, causes such as gouty tophi and osteomyelitis have also been reported.¹⁹⁻²¹ In our case series, SBD was generated by extensive surgical debridement. In two of them, as a treatment for a deep infection caused by a surgical site infection, and in the other, as a result of an ankle prosthesis loosening.

Initially used for the treatment of long bone SBD, the Masquelet technique began to be used in other regions of the body due to its good results.⁹⁻¹⁴ This two-stage procedure has unique characteristics. The cement spacer acts as a foreign body, causing the organism to generate a kind of vascularized capsule or biomembrane that surrounds it. This provides a privileged environment for the growth and incorporation of the bone graft. It also has the function of preventing graft resorption and secreting and maintaining osteoinductive growth factors.¹⁵⁻¹⁸ According to the literature, by the sixth week, the membrane is 1-2 mm thick, hypervascularized, and free of adhesions with the underlying spacer, indicating an optimal timing for the second surgical stage.^{15,17,18} In our case series, the time elapsed between the first and second surgeries was eight weeks (2 patients) and 10 weeks for the remaining patient. These times are very similar to those published on this region. Luo et al. performed the second surgery eight weeks later in their study of 19 patients who were treated for osteomyelitis in the distal third of the tibia.²² In a study of infected pseudarthrosis in the metatarsal region, Giannoudis et al. performed the second surgery between the 6th and 8th week.¹¹

In the second stage, the remaining cavity should be filled with bone grafts. Because of its osteogenic, osteoconductive and osteoinductive properties, the iliac crest is the reference site.^{14,15,18} In cases of larger defects, where the graft is insufficient, ground allograft from a tissue bank can be used, but without exceeding a ratio of 1 to 3.^{11,14} Despite this, consolidation rates of >90% have been published using a ratio of 1 to 1.^{23,24} Pesciallo et al. used up to 64% autologous graft, and obtained a consolidation rate of >90%.²³ In our series, the defects were filled with equal halves of autologous bone graft and ground allograft to avoid the need to use both iliac crests and we achieved consolidation rates similar to those published for the diaphyseal and distal tibial region.^{19,25,26}

The size or length of the defects, as in the rest of the long bones, does not appear to influence consolidation rates or the patient's ability to fully bear weight.¹⁹ However, in the foot and ankle region, these times are somewhat longer. Siboni et al. treated patients with defects up to 18 cm secondary to septic pseudarthrosis in the distal tibia and achieved consolidation in 93% of the cases, in an average of 14 months (range 3-32).²⁷ Similarly, Zooler et al. reported defects between 3 and 10 cm in the distal tibial region, with a 100% consolidation rate between two and nine months.²⁸ In our series, the defects measured 2.5; 6 and 5 cm, dimensions quite similar to those published, and consolidation was achieved in all patients, in an average of 10.3 months.

A strength of this study is that it is one of the few of its kind at the national level on a disease with few international publications, for which there are multiple treatment options and adequate management remains unclear. Its retrospective nature, the low number of patients and the heterogeneity of the variables under study are its main weaknesses.

We believe that more studies with a greater number of patients, as well as prospective comparative studies with other techniques, are required to obtain findings that will help us reach a therapeutic consensus in the treatment of SBD.

CONCLUSIONS

The induced membrane technique offers a valid treatment alternative to solve problems that are difficult to solve in orthopedics, such as bone defects. It enables us to treat them without the need for complex treatments such as vascularized bone grafts or callus distraction, while also retaining the length of the limb and ensuring good function.

Although we cannot prove that this procedure is the most indicated in this type of cases, we can affirm that consolidation was achieved in all patients and resolution of the bone defect, which encourages us to continue using this same technique.

Conflict of interest: The authors declare no conflicts of interest.

F. Vago Anaya ORCID ID: <https://orcid.org/0000-0001-8589-7782>
M. Goveo ORCID ID: <https://orcid.org/0009-0009-4761-6148>

E. Loncharich ORCID ID: <https://orcid.org/0009-0002-1106-3544>
C. Á. Pesciallo ORCID ID: <https://orcid.org/0000-0002-4461-8465>

REFERENCES

1. Andrzejowski P, Masquelet A, Giannoudis PV. Induced membrane technique (Masquelet) for bone defects in the distal tibia, foot, and ankle: Systematic review, case presentations, tips, and techniques. *Foot Ankle Clin* 2020;25(4):537-86. <https://doi.org/10.1016/j.fcl.2020.08.013>
2. Pelissier P, Bollecker V, Martin D, Baudet J. Foot reconstruction with the “bi-Masquelet” procedure. *Ann Chir Plast Esthet* 2002;47(4):304-7. [https://doi.org/10.1016/s0294-1260\(02\)00123-1](https://doi.org/10.1016/s0294-1260(02)00123-1)
3. Cattaneo R, Catagni M, Johnson EE. The treatment of infected nonunions and segmental defects of the tibia by the methods of Ilizarov. *Clin Orthop Relat Res* 1992;(280):143-52. PMID: 1611734
4. DeCoster TA, Gehlert RJ, Mikola EA, Pirela-Cruz MA. Management of posttraumatic segmental bone defects. *J Am Acad Orthop Surg* 2004;12(1):28-38. <https://doi.org/10.5435/00124635-200401000-00005>
5. Obremesky WT, Molina CS, Collinge C, Tornetta P, Sagi C, Schmidt A, et al. Current practice in the management of segmental bone defects among orthopaedic trauma surgeons. *J Orthop Trauma* 2014;28(8):e203-7. <https://doi.org/10.1097/BOT.0000000000000034>
6. Gaskill TR, Urbaniak JR, Aldridge JM. Free vascularized fibular transfer for femoral head osteonecrosis: donor and graft site morbidity. *J Bone Joint Surg Am* 2009;91(8):861-7. <https://doi.org/10.2106/JBJS.H.01105>
7. Myeroff C, Archdeacon M. Autogenous bone graft: donor sites and techniques. *J Bone Joint Surg Am* 2011;93(3):222-7. <https://doi.org/10.2106/JBJS.J.01513>
8. Masquelet AC, Fitoussi F, Begue T, Muller GP. Reconstruction of the long bones by the induced membrane and spongy autograft. *Ann Chir Plast Esthet* 2000;45(3):346-53. PMID: 10929461
9. Masquelet A, Kanakaris NK, Obert L, Stafford P, Giannoudis PV. Bone repair using the Masquelet technique. *J Bone Joint Surg Am* 2019;101(11):1024-36. <https://doi.org/10.2106/JBJS.18.00842>
10. Giannoudis PV, Faour O, Goff T, Kanakaris N, Dimitriou R. Masquelet technique for the treatment of bone defects: tips-tricks and future directions. *Injury* 2011;42(6):591-8. <https://doi.org/10.1016/j.injury.2011.03.036>
11. Giannoudis PV, Harwood PJ, Tosounidis T, Kanakaris NK. Restoration of long bone defects treated with the induced membrane technique: protocol and outcomes. *Injury* 2016;47(Suppl 6):S53-61. [https://doi.org/10.1016/S0020-1383\(16\)30840-3](https://doi.org/10.1016/S0020-1383(16)30840-3)
12. Wong TM, Lau TW, Li X, Fang C, Yeung K, Leung F. Masquelet technique for treatment of posttraumatic bone defects. *Sci World J* 2014;2014:710302. <https://doi.org/10.1155/2014/710302>
13. Mauffrey C, Hake ME, Chadayammuri V, Masquelet AC. Reconstruction of long bone infections using the induced membrane technique: Tips and tricks. *J Orthop Trauma* 2016;30(6):e188-93. <https://doi.org/10.1097/BOT.0000000000000500>
14. Pesciallo C, Garabano G, Montero Vincas A, Gómez DJ, Bidolegui F, Cid Casteulani A. Defectos óseos segmentarios infectados en huesos largos: tratamiento con técnica de Masquelet. *Rev Asoc Argent Ortop Traumatol* 2019;84(1):15-26. <https://doi.org/10.15417/issn.1852-7434.2019.84.1.853>
15. Taylor BC, French BG, Fowler TT, Russell J, Poka A. Induced membrane technique for reconstruction to manage bone loss. *J Am Acad Orthop Surg* 2012;20(3):142-50. <https://doi.org/10.5435/JAAOS-20-03-142>
16. Klauke K, Knothe U, Masquelet A. Effet biologique des membranes à corps étranger induites in situ sur la consolidation des greffes d'os spongieux. *Rev Chir Orthop Suppl* 1995:109-10 (70^e réunion annuelle de la SOFCOT).

17. Masquelet AC, Begue T. The concept of induced membrane for reconstruction of long bone defects. *Orthop Clin North Am* 2010;41(1):27-37. <https://doi.org/10.1016/j.ocl.2009.07.011>
18. Pelissier P, Masquelet AC, Bareille R, Mathoulin Pelissier S, Amedee J. Induced membranes secrete growth factors including vascular and osteoinductive factors and could stimulate bone regeneration. *J Orthop Res* 2004;22(1):73-9. [https://doi.org/10.1016/S0736-0266\(03\)00165-7](https://doi.org/10.1016/S0736-0266(03)00165-7)
19. Largey A, Faline A, Hebrard W, Hamoui M, Canovas F. Management of massive traumatic compound defects of the foot. *Orthop Traumatol Surg Res* 2009;95(4):301-4. <https://doi.org/10.1016/j.otsr.2009.02.005>
20. Mak MF, Stern R, Assal M. Masquelet technique for midfoot reconstruction following osteomyelitis in charcot diabetic neuropathy: a case report. *JBJS Case Connect* 2015;5(2):e281-5. <https://doi.org/10.2106/JBJS.CC.N.00112>
21. Liu F, Huang RK, Xie M, Pan H, Zhao JJ, Lei B. Use of Masquelet's technique for treating the first metatarsophalangeal joint in cases of gout combined with a massive bone defect. *Foot Ankle Surg* 2018;24(2):159-63. <https://doi.org/10.1016/j.fas.2017.01.009>
22. Luo F, Wang X, Wang S, Fu J, Xie Z. Induced membrane technique combined with two stage internal fixation for the treatment of tibial osteomyelitis defects. *Injury* 2017;48(7):1623-7. <https://doi.org/10.1016/j.injury.2017.04.052>
23. Pesciallo CA, Garabano G, Dainotto T, Ernst G. Masquelet technique in post-traumatic infected femoral and tibial segmental bone defects. Union and reoperation rates with high proportions (up to 64%) of allograft in the second stage. *Injury* 2021;52(11):3471-7. <https://doi.org/10.1016/j.injury.2021.08.031>
24. Karger C, Kishi T, Schneider L, Fitoussi F, Masquelet AC. Treatment of posttraumatic bone defects by the induced membrane technique. *Orthop Traumatol Surg Res* 2012;98:97-102. <https://doi.org/10.1016/j.otsr.2011.11.001>
25. Khan SN, Cammisa FP Jr, Sandhu HS, Diwan AD, Girardi FP, Lane JM. The biology of bone grafts. *J Am Acad Orthop Surg* 2003;26:923-4. PMID: 15712985
26. Pelissier P, Masquelet AC, Lepreux S, Martin D, Baudet J. Behavior of cancellous bone graft placed in induced membranes. *Br J Plast Surg* 2002;55:598-600. <https://doi.org/10.1054/bjps.2002.3936>
27. Siboni R, Joseph E, Blasco L, Barbe C, Bajolet O, Diallo S, et al. Management of septic non-union of the tibia by the induced membrane technique. What factors could improve results? *Orthop Traumatol Surg Res* 2018;104(6):911. <https://doi.org/10.1016/j.otsr.2018.04.013>
28. Zoller SD, Cao LA, Smith RA, Sheppard W, Lord EL, Hamad CD, et al. Staged reconstruction of diaphyseal fractures with segmental defects: Surgical and patient-reported outcomes. *Injury* 2017;48(10):2248-52. <https://doi.org/10.1016/j.injury.2017.06.018>