

Myths, Truths, Doubts and Confusions About Shockwave Therapy and Its Role in Musculoskeletal Pathology

Daniel Moya

Orthopedics and Traumatology Service, Hospital Británico de Buenos Aires, Autonomous City of Buenos Aires, Argentina

ABSTRACT

The advent of renal lithotripsy in the 1980s had a disruptive effect on the treatment of kidney stones. The discovery of the biological effects of shock waves quickly expanded the use of this therapeutic method to the field of Orthopedics and Traumatology. Although the topic has advanced significantly in recent years, there are still many questions and confusions in our specialty's environment, particularly among professionals who are not directly involved in the field. The objective of this presentation is to provide a scientific analysis of the points of controversy and the most frequent doubts.

Keywords: Shock waves; radial pressure waves; mechanotransduction.

Level of Evidence: V

Mitos, verdades, dudas y confusiones sobre las ondas de choque y su rol en la enfermedad musculoesquelética

RESUMEN

El advenimiento de la litotricia renal en la década de los 80 tuvo un efecto disruptivo en el tratamiento de los cálculos renales. El descubrimiento de los efectos biológicos de las ondas de choque expandió rápidamente el uso de este método terapéutico al campo de la Ortopedia y Traumatología. Si bien, en los últimos años, ha tenido un amplio desarrollo, persisten muchas confusiones y dudas en el ambiente de nuestra especialidad, sobre todo entre los profesionales que no están directamente involucrados en el tema. El objetivo de esta presentación es hacer un análisis de los puntos de controversia y las dudas más frecuentes, basado en la bibliografía científica.

Palabras clave: Ondas de choque; ondas radiales de presión; mecanotransducción.

Nivel de Evidencia: V

INTRODUCTION

The advent of renal lithotripsy in the 1980s had a disruptive effect on the treatment of kidney stones.¹ The application of mechanical waves made it possible to remove mineral deposits within the urinary tract and thus avoid surgery in a huge percentage of patients. Forty years later, the treatment, which was initially met with skepticism, is now a recognized and approved indication.²

Experience with the method led early urologists to notice consequences beyond the mechanical effect on the stones.³⁻⁵ The biological response induced by the mechanical waves thus opened up a new therapeutic dimension. This knowledge was quickly applied to orthopedics and traumatology pathology.^{3,6-9}

Despite more than 30 years since its first use in the field of musculoskeletal illnesses, traumatologists who are not directly involved in its usage continue to have several concerns and misinterpretations about the role of this therapeutic tool.

The objective of this presentation is to analyze the points of controversy and the most frequent doubts, based on the scientific literature.

Received on October 24th, 2023 Accepted after evaluation on October 27th, 2023 • Dr. DANIEL MOYA • drdanielmoya@gmail.com  <https://orcid.org/0000-0003-1889-7699>

How to cite this article: Moya D. Myths, Truths, Doubts and Confusions About Shockwave Therapy and Its Role in Musculoskeletal Pathology. *Rev Asoc Argent Ortop Traumatol* 2024;89(2):199-209. <https://doi.org/10.15417/issn.1852-7434.2024.89.2.1835>

Confusion: are radial and focused waves the same thing?

The mechanical forces of nature have influenced living beings since the genesis of life on our planet.³ Their use for therapeutic purposes began at the end of the 20th century.

There are two types of waves, electromagnetic and mechanical.¹⁰ Both focused and radial waves are mechanical waves.

Shock waves or focused waves are mechanical waves with well-defined characteristics.¹⁰⁻¹³ As seen in **Figure 1A**, they have a rapidly growing, short-lived peak positive pressure followed by a negative pressure phase. These waves are the ones initially described in the field of urology and they are the real shock waves. They can be generated by electrohydraulic, electromagnetic or piezoelectric sources.¹⁰⁻¹³

A decade after the first therapeutic application of focused waves, ‘radial waves’ appeared on the market as a more portable and cost-effective alternative.³ Historical and commercial reasons have determined that radial waves are also called ‘shock waves’, but this is inaccurate.^{10,13} The correct nomenclature is “focal shock waves” and “radial pressure waves,” respectively. Unfortunately, in most publications, the correct nomenclature is not respected, which generates a great deal of confusion.¹¹

From the physical point of view, radial waves (**Figure 1B**) are completely different from focused waves. Radial waves have a peak positive pressure 100 times lower and a pulse duration 1000 times longer.¹⁰⁻¹² The mechanisms of generation and action are also different.¹⁰⁻¹² Radial waves are generated by the impact of a projectile on an applicator, so they are also known as ballistic waves.^{10,12} Their mechanism of generation is based on the principle of action and reaction described by Newton.^{3,14}

The fact that they use different technology does not imply that one is superior to the other. In some cases, indications in the field of Orthopedics and Traumatology overlap and there are also specific indications for each method.^{11,12}

The risk levels are also different.¹² Focused waves, when used incorrectly or with inadequate indications, can cause severe complications that radial waves would not.^{13,15} This is one of the reasons why international societies recommend restricting focused waves to medical use.¹⁶

In short, radial waves and focused waves are mechanical waves that can have a therapeutic use in the field of Orthopedics and Traumatology, but they are completely different from the point of view of their generation and physical characteristics. Each method has its own set of indications, as well as some shared ones. Radial waves are not shock waves. It is recommended that focused waves be used by trained physicians.

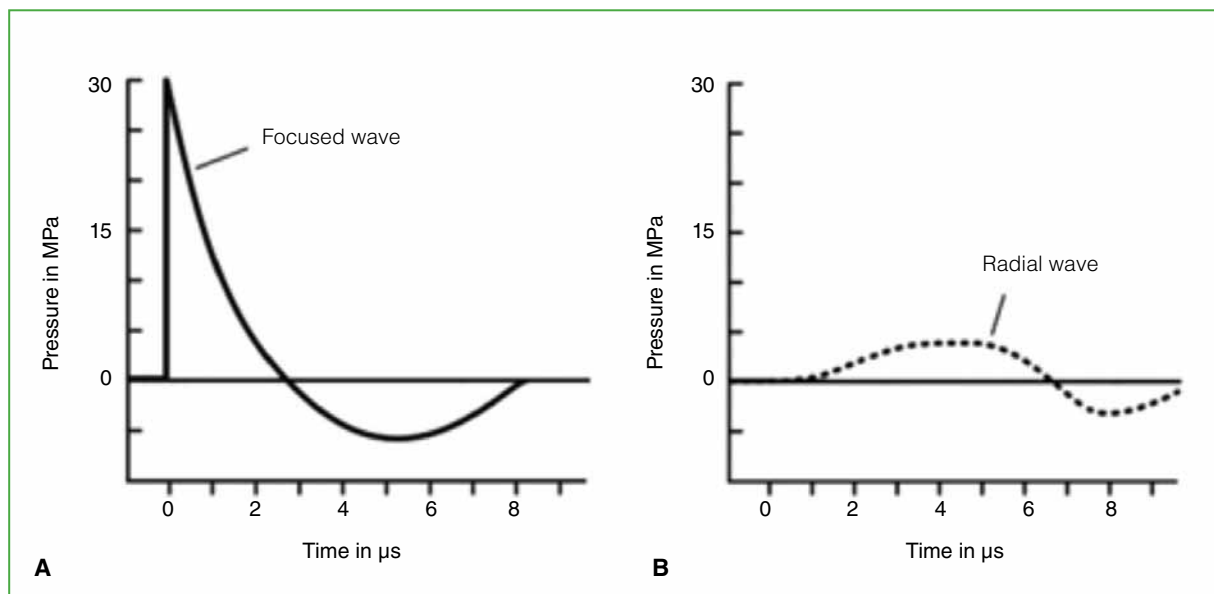


Figure 1. Comparison of the pressure profiles of a focused shock wave (**A**) and a radial wave (**B**).

Modified from: Loske AM, Moya D. Shock waves and radial pressure waves: time to put a clear nomenclature into practice. *J Reg Sci* 2021;1(1):4-8. <https://doi.org/10.13107/jrs.2021.v01.i01.005>

Myth: mechanical waves cause microtears in tissues (false)

It is common to hear that mechanical waves base their therapeutic action on microtrauma that cause bleeding and scarring processes. This is incorrect.

MRI studies performed after applying focused shock waves to the shoulder have ruled out any type of injury.¹⁷ Histological evaluation of bone tissue after the application of focused waves ruled out the presence of “microfractures” when therapeutic doses are used.¹⁸ The purely mechanical effect is only effective in the case of the destruction of calculi, which are inert mineral accumulations. In living tissues, the mechanism of action is biological, based on the phenomenon of mechanotransduction.^{12,13,19} Cells and the extracellular matrix are influenced by mechanical stimuli. These structures recognize the mechanical stimuli and generate a biological response.^{12,13,19}

It is perplexing that, in a field that has used mechanotransduction for over a century, this method of action is difficult to understand. All traumatologists know that by loading a fracture at the right time and under the right conditions, the healing process is accelerated. This is nothing more or less than applying mechanotransduction therapeutically as in the case of shock waves.

The process has four stages: physical, physico-chemical, chemical, and biological.^{12,19} The stimulated cell nucleus determines the release of exosomes with angiogenic effects.¹⁹⁻²² Vasculogenesis and angiogenesis are well-studied fundamental mechanisms of action in focused shock waves.^{12,13,19-23} Countless studies have shown that the local concentration of nitric oxide, cell replication factors and vascular growth factors increases after applying shock waves.^{12,19,19,21,23}

It is crucial to note that the therapeutic effects of mechanical waves are not solely based on mechanical effects, nor are they driven by microtrauma generation. The mechanism of action is biological and basically mediated by angiogenic and vasculogenic effects.

Confusion: what are the indications for each type of wave?

As mentioned above, there are ideal indications for each type of wave and other indications are shared (Figure 2).^{12,13} Focused waves are indicated for conditions that require the use of higher levels of energy, such as tendon calcifications^{24,25} and bone lesions.^{6,26} They are also capable of accessing greater depths than radial waves.²⁷

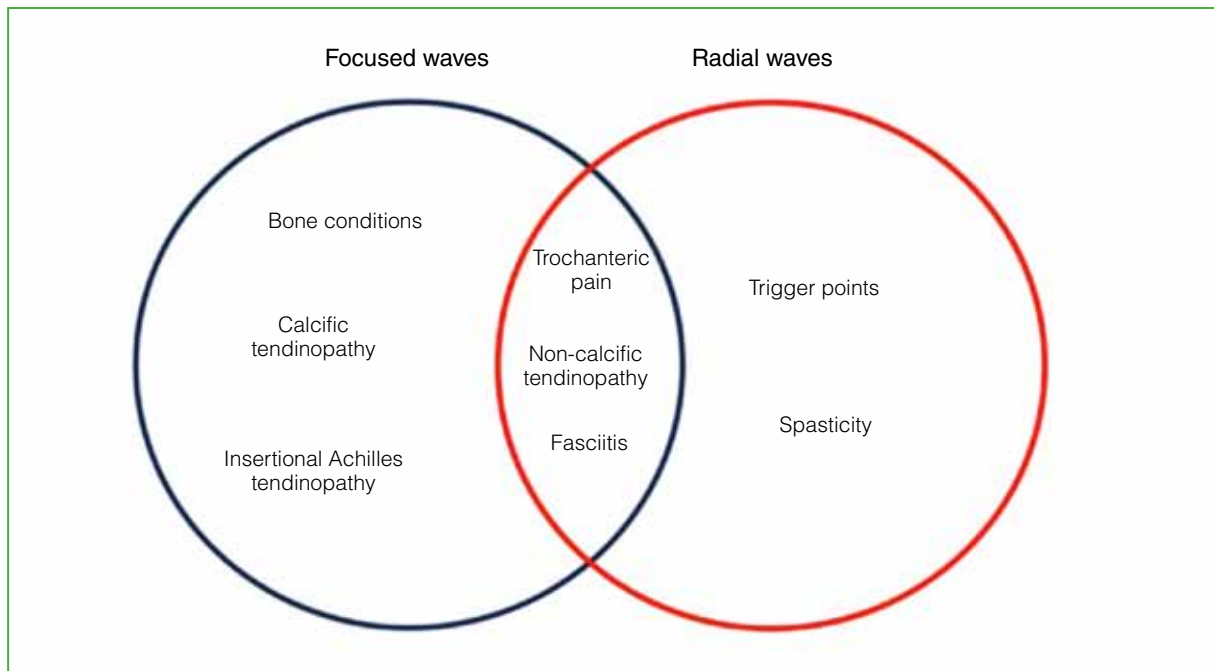


Figure 2. Indications for focused shock waves, indications for radial waves, and indications shared by both.

Modified from: Loske AM, Moya D. Shock waves and radial pressure waves: time to put a clear nomenclature into practice. *J Reg Sci* 2021;1(1):4-8. <https://doi.org/10.13107/jrs.2021.v01.i01.005>

Radial waves have a more superficial effect and pose less risk when applied in areas close to organs with gaseous content;^{11,12,15} therefore, they can be used, for example, on trigger points in the dorsal region. They have also been advised for childhood spasticity due to their higher treatment tolerance.²⁸

Radial waves allow for greater coverage of treatment areas than focused waves.

Both methods can be used interchangeably in most noncalcified tendinopathies¹² and plantar fasciitis.^{12,13,16} In insertional Achilles tendinopathies, this author prefers focused waves.

Truth: there is solid scientific evidence of their efficacy

The majority of surgical methods used in Orthopedics and Traumatology are supported by a poor level of scientific evidence.^{29,30} Stephen Burkhart, in his keynote address at the 2019 World Congress on Shoulder and Elbow Surgery in Buenos Aires, wondered whether shoulder arthroscopy could have been developed during the 21st century era of evidence-based medicine and *Food and Drug Administration* restriction policies.^{31,32}

Shock waves arose a decade after arthroscopy, and they had to deal with the more demanding and critical context of new therapeutic alternatives.³¹ This led to the generation of many studies and publications, not always with the utmost scientific rigor.³¹

In 2018, we published a study on the most frequent indications for radial and focused waves in the *Journal of Bone and Joint Surgery*.¹² We used the grades of recommendation based on scientific evidence according to the system proposed by the aforementioned publication³³ (Table 1).

The result, based on the evidence found in the literature at that time, can be seen in Table 2.

Table 1. Grades of recommendation based on scientific evidence.

| Grade of recommendation | Type of study | Behavior |
|-------------------------|--|----------------------------------|
| A | Level of Evidence: I | Definitively change the practice |
| B | Level of evidence: II and III | Probably change the practice |
| C | Level of evidence: IV and V or controversial | Define according to experience |
| I | Insufficient evidence | Cannot be recommended |

Adapted from Wright JG, Einhorn TA, Heckman JD. Grades of recommendation. *J Bone Joint Surg Am* 2005;87(9):1909-10. <https://doi.org/10.2106/JBJS.8709.edit>

Table 2. Grades of recommendation for the most common indications for radial and focused waves in musculoskeletal disease.

| Condition | Technology | Grade of recommendation |
|---|--------------------|-------------------------|
| Calcific tendinopathy of the shoulder | Focused | A |
| Calcific tendinopathy of the shoulder | Radial | I |
| Non-calcific tendinopathy of the shoulder | Focused and radial | C |
| Epicondylar muscle tendinopathy | Focused and radial | B |
| Trochanteric pain syndrome | Radial | B |
| Patellar tendinopathy | Focused and radial | B |
| Achilles tendinopathy | Focused and radial | B |
| Plantar fasciitis | Focused and radial | A |
| Nonunion | Focused | B |

Adapted from Moya D, Ramón S, Schaden W, Wang CJ, Guiloff L, Cheng JH. The role of extracorporeal shockwave treatment in musculoskeletal disorders. *J Bone Joint Surg Am* 2018;100(3):251-63. <https://doi.org/10.2106/JBJS.17.00661>

The highest level of evidence for rotator cuff calcifications is for focused waves and, in plantar fasciitis, for both focused and radial waves.¹² The *American College of Foot and Ankle Surgeons* incorporated the use of waves into its treatment algorithm for plantar fasciitis more than 10 years ago.³⁴

The scientific evidence is moderate for most tendinopathies, except for non-calcific rotator cuff tendinopathy¹² and pseudarthrosis.¹²

The degree of evidence is low for non-calcified tendinopathies of the shoulder,¹² knee osteoarthritis,³⁵ wrist and hand tenosynovitis, and many other conditions. However, based on this author's experience, the empirical results in the non-advanced stages of knee osteoarthritis are very encouraging.

In conclusion, there is an acceptable degree of evidence for the use of focused shock waves and radial waves in most of their usual indications. In many of the cases, the level of evidence is similar to or greater than that of surgical procedures for the same conditions.

Doubt: what are their contraindications?

An important contraindication to the use of focused waves is if the patient is receiving intense anticoagulant therapy,^{15,36} especially if high energy levels are to be used.

The application of focused waves to tissues with gaseous content (lungs, viscera) can cause serious injury.^{15,37} Direct application to open physes, tumor areas, embryos, and fetuses is also contraindicated.^{15,37,38} The application of focused waves to large vessels and nerves is contraindicated.^{15,37,39}

The presence of a pacemaker is today a relative contraindication for focused waves due to changes in pacemaker design and focal equipment;⁴⁰ in any case, it is preferable to be in contact with the treating cardiologist.

As for radial waves, given their lower penetration, the possibility of complications is much lower. Absolute contraindications are the presence of tumors, embryos, or fetuses in the area to be treated.³⁷

Doubt: when is the ideal time to indicate them?

The ideal indication for both focused and radial waves is chronic tendinopathy and fasciitis. It is recommended to exhaust other therapeutic options, such as medication, rest, rehabilitation, changes in habits and exercises, before starting shockwave treatment. Therefore, they are not usually the initial therapeutic indication in most cases.^{12,16}

Confusion: are the results immediate?

Mechanical waves generate a biological process that includes modulation of inflammation and stimulation of healing.^{12,13,16,19} A succession of biological phenomena occurs that require time.^{12,16} The clinical response may not appear until three months in the case of tendinopathies.¹⁶ Follow-up protocols for pseudarthrosis extend the basic radiological control to three months, but changes may occur up to one year after treatment is completed (Figure 3).

For these reasons, it is key to keep in mind that immediate responses should not be expected in the vast majority of cases.

Doubt: How many sessions are necessary?

The lack of strict consensus regarding the number of sessions and doses has been criticized. In most indications of musculoskeletal pathology, the current consensus advises three sessions at a weekly interval.^{12,16,37} According to the generation source used, sessions may be added, but in general, no more than six in total. Additional sessions are added after a prudent wait to evaluate the effect of the initial dose. These additional doses are not necessary in most cases.

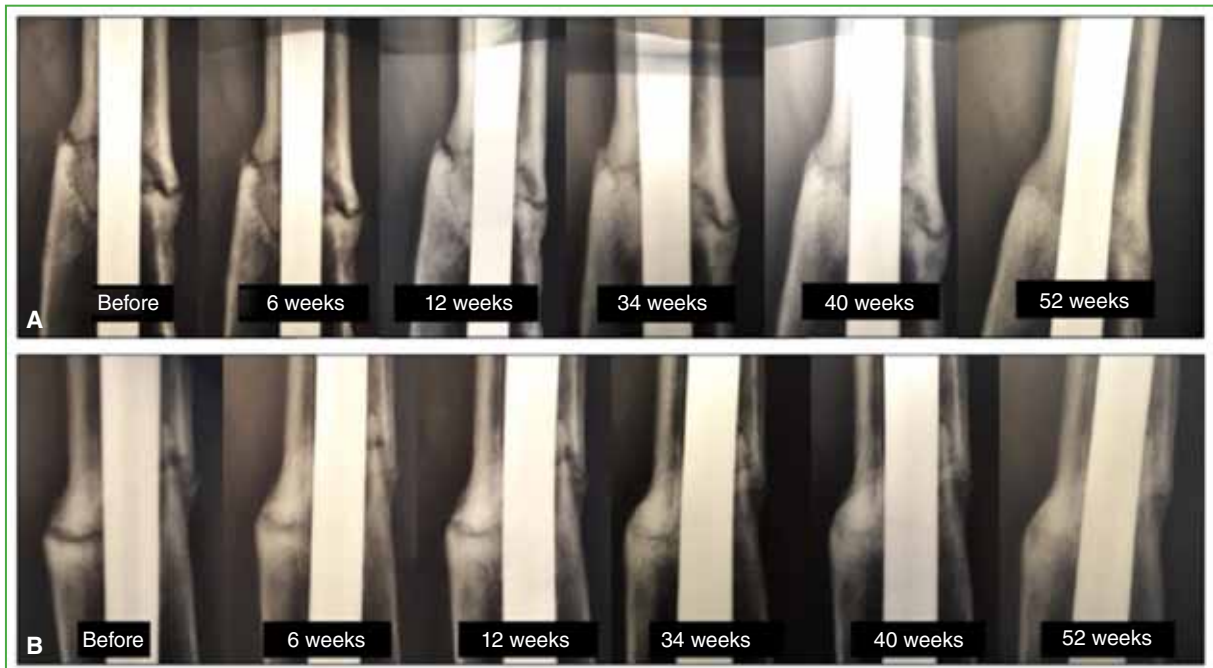


Figure 3. Progression of the consolidation process after applying a focused shockwave treatment plan in a patient with femoral pseudarthrosis of 20 months of evolution and two surgical procedures. The condition had progressed for ten months since the second surgery. **A.** Sequence of plain radiographs of the femur, AP view, with focus on the area of pseudarthrosis. **B.** Sequence of plain radiographs of the femur, lateral view, with focus on the area of pseudarthrosis.

Confusion: ossification versus calcification

A conceptual error is often made in practice, confusing calcification and ossification. Calcifications are mineral deposits in soft tissues. The best known case is hydroxyapatite crystal deposits in the rotator cuff tendons. In this case, shock waves are used to trigger a biological process that resorbs the mineral deposit (Figures 4A and B).

Heterotopic ossifications, on the other hand, are characterized by organized and structured bone tissue that shock waves are not able to “dissolve” and cannot stimulate its resorption. It is bone tissue, i.e., a calcified collagenous matrix that may or may not contain bone marrow elements.⁴¹

During the COVID-19 pandemic, we received patients referred with heterotopic hip ossifications after a stay in the intensive care unit (Figure 4C), with the aim of making the calcium deposit disappear, and unfortunately this is not possible. If it were, we would risk eliminating sections of normal bone, but focused waves do not have such an effect.

It is important to note that calcifications and ossifications are two different conditions in terms of histology, prognosis and treatment. Focused waves do not determine the disappearance of heterotopic ossifications.

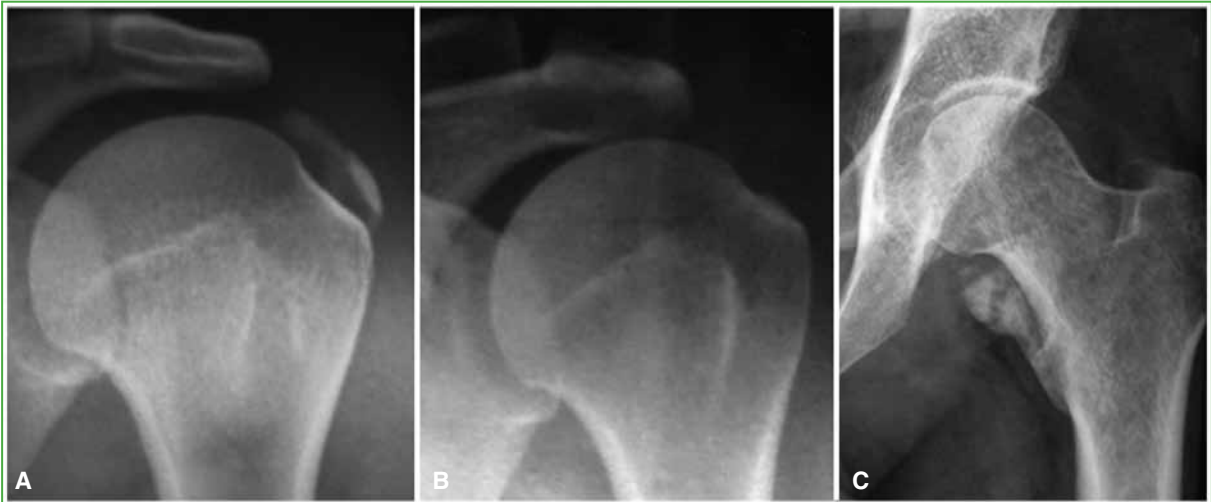

Figure 4. Plain radiographs of the shoulder, AP view, showing calcification of the supraspinatus tendon (A) and the same case after a focused shockwave treatment plan (B). C. Radiograph of the hip, AP view. Heterotopic ossification of the hip is seen after a stay in intensive care for COVID-19.

Doubt: can they be used in cases of pseudarthrosis?

Focused waves can be used to treat pseudarthrosis and delayed consolidation (Figures 3, 5 and 6). It is an absolute condition that the fracture site must be stable.^{12,16} The best results are obtained when the gap is <5 mm, in hypertrophic calluses, in patients with a short time of evolution and in non-infected patients.^{12,16} High energy levels must be used.^{12,16}

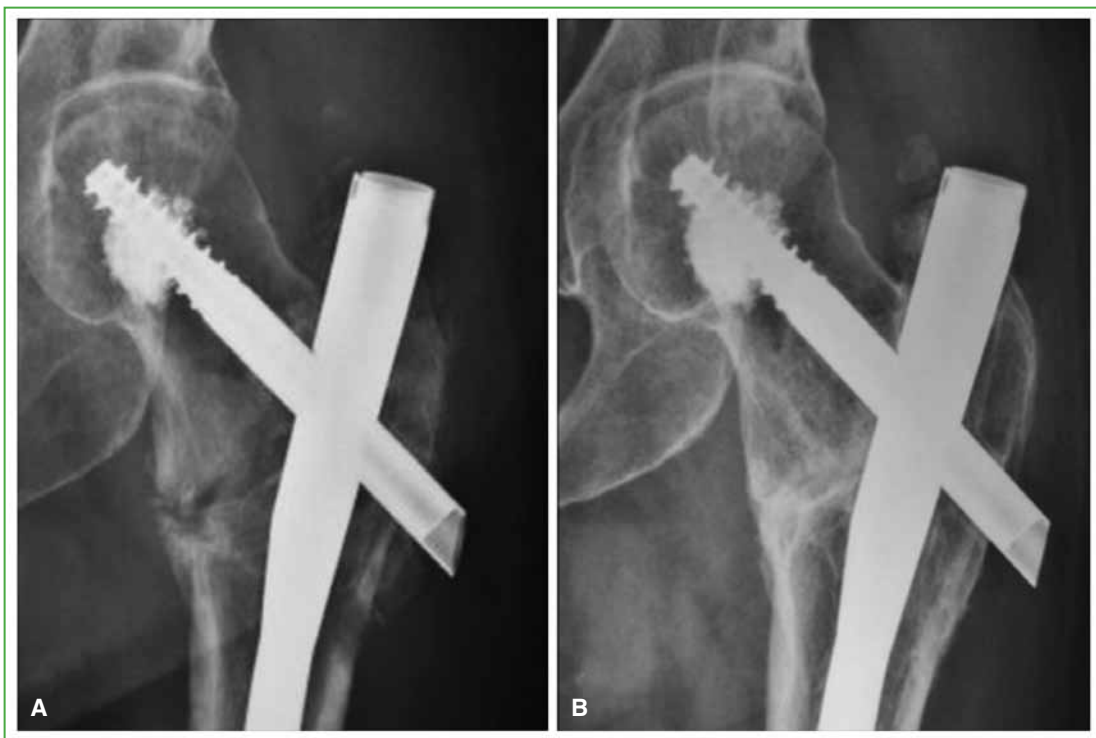


Figure 5. Plain radiographs of the hip, AP view. **A.** Revision surgery of a hip intertrochanteric fracture of one year of evolution, with no signs of consolidation. **B.** Results 5 months after the application of a focused shockwave treatment plan. The symptomatology disappeared. With permission from the Journal of Regenerative Science.

The rate of favorable outcomes is around 70% under the best conditions.^{12,13,16} Studies have been published comparing the results of focused waves and surgery in certain cases of pseudarthrosis, but no significant differences have been obtained.^{41,42}

Likewise, we have obtained favorable outcomes in cases of failed arthrodesis (Figure 6).

In conclusion, focused waves can be applied as an alternative to surgery when the conditions are right for their use.

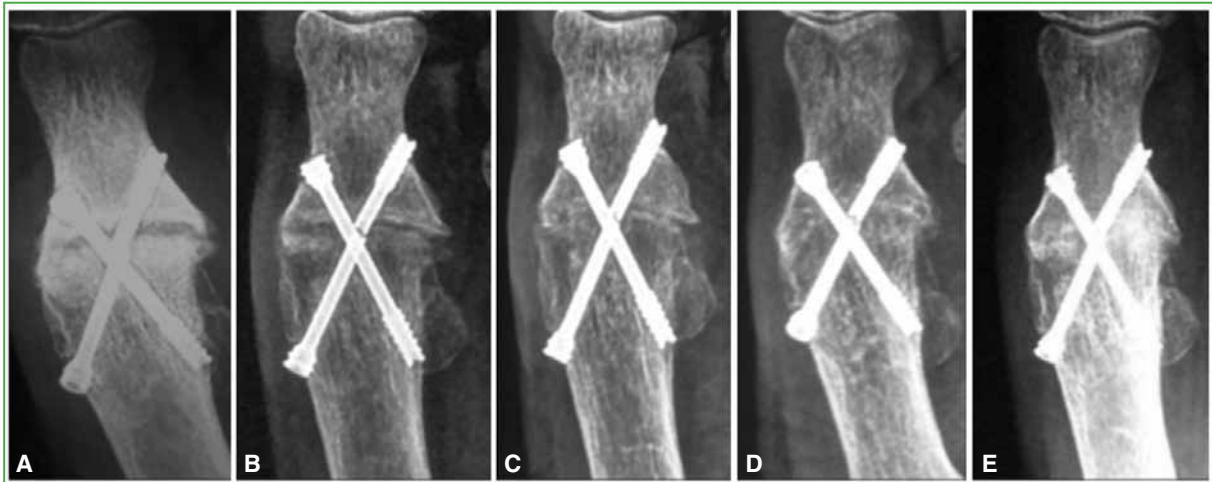


Figure 6. Sequence of plain radiographs of the forefoot with focus on the first metatarsophalangeal joint. **A.** Failed hallux arthrodesis of 18 months of evolution. **B.** Two months after three sessions of high-energy focused shockwaves. **C.** Three months after shock waves. **D.** Four months after shock waves. The arthrodesis has consolidated and the patient is asymptomatic. **E.** Radiographic control after 2 years.

Myth: they do not cause complications (false)

Like any therapeutic procedure, the outcome of shock waves can be poor.¹⁵ The most common poor outcome is failure to produce the intended biological response, but complications have also been reported.

The most frequent cause of poor outcomes is diagnostic error.¹⁵ The availability of shock wave or radial pressure wave equipment does not make the operator an expert in the disease being treated. For this reason, we emphasize the necessity of respecting the area of expertise¹⁶ and collaborating with the subspecialist in Orthopedics and Traumatology.

Inadequate application and failure to follow contraindications can cause serious complications.^{15,16,39} In Argentina, the equipment must be approved by the National Administration of Drugs, Food and Technology (ANMAT).

Reported complications range from episodes of lipothymia during application and a transient increase in pain after application, to complications such as isolated cases of humeral head necrosis.^{13,15,43} Fortunately, most complications are avoidable and infrequent.

Advantages

One of the main advantages of mechanical wave therapy is that it is a non-invasive method with a low rate of severe complications.

Initially, it was reserved for situations in which, having exhausted conservative treatment options, the possibility of surgery was evaluated.¹⁹ Over the years, the range of indications has increased.

An unsuccessful therapeutic attempt with focused waves has no bearing on the likelihood of success in subsequent surgery.⁴⁴

The cost-effectiveness ratio is also adequate. For example, the success rate of open and arthroscopic surgery has been compared with that of focused shock waves for rotator cuff calcifications, and the outcomes were similar.^{45,46} In addition to causing fewer and less severe complications,^{45,46} focused waves have a much lower cost.^{12,13,47,48}

Conflict of interest: The author declares no conflicts of interest.

REFERENCES

1. Chaussy C, Brendel W, Schmiedt E. Extracorporeally induced destruction of kidney stones by shock waves. *Lancet* 1980;2(8207):1265-8. [https://doi.org/10.1016/s0140-6736\(80\)92335-1](https://doi.org/10.1016/s0140-6736(80)92335-1)
2. Hiller SC, Ghani KR. Frontiers of stone management. *Curr Opin Urol* 2020;30(1):17-23. <https://doi.org/10.1097/MOU.0000000000000698>
3. Moya D, Loske AM, Hobrough P, Moya C. History of shock waves and radial pressure waves from Newton to our times. *J Reg Sci* 2023;3(1):9-14. <https://doi.org/10.13107/jrs.2023.v03.i01.70>
4. Haupt G, Chvapil M. Effect of shock waves on the healing of partial-thickness wounds in piglets. *J Surg Res* 1990;49(1):45-8. [https://doi.org/10.1016/0022-4804\(90\)90109-f](https://doi.org/10.1016/0022-4804(90)90109-f)
5. Haupt G, Haupt A, Ekkernkamp A, Gerety B, Chvapil M. Influence of shock waves on fracture healing. *Urology* 1992;39(6):529-32. [https://doi.org/10.1016/0090-4295\(92\)90009-1](https://doi.org/10.1016/0090-4295(92)90009-1)
5. Valchanov VD, Michailov P. High energy shock waves in the treatment of delayed and nonunion fractures. *Int Orthop* 1991;15(3):181-4. <https://doi.org/10.1007/BF00192289>
6. Loew M, Jurgowski W. [Initial experiences with extracorporeal shockwave lithotripsy (ESWL) in treatment of tendinosis calcarea of the shoulder]. *Z Orthop Ihre Grenzgeb* 1993;131(5):470-3. <https://doi.org/10.1055/s-2008-1040056>
7. Rompe JD, Hope C, Kullmer K, Heine J, Burger R. Analgesic effect of extracorporeal shock-wave therapy on chronic tennis elbow. *J Bone Joint Surg Br* 1996;78(2):233-7. PMID: 8666632
8. Perlick L, Boxberg W, Giebel G. [High energy shock wave treatment of the painful heel spur]. *Unfallchirurg* 1998;101(12):914-8. <https://doi.org/10.1007/s001130050358>
9. Loske AM. *Medical and biomedical applications of shock waves*. Cham, Switzerland: Springer International; 2017, p. 55.
10. Loske AM, Moya D. Shock waves and radial pressure waves: time to put a clear nomenclature into practice. *J Reg Sci* 2021;1(1):4-8. <https://doi.org/10.13107/jrs.2021.v01.i01.005>
11. Moya D, Ramón S, Schaden W, Wang CJ, Guiloff L, Cheng JH. The role of extracorporeal shockwave treatment in musculoskeletal disorders. *J Bone Joint Surg Am* 2018;100(3):251-63. <https://doi.org/10.2106/JBJS.17.00661>
12. Moya D. Terapia por onda de choque extracorpórea para el tratamiento de las lesiones musculoesqueléticas. *Rev Asoc Argent Ortop Traumatol* 2002;67(4):273-86. Available at: https://www.aaot.org.ar/revista/1993_2002/2002/2002_4/670408.pdf
13. Newton I. *Philosophiae Naturalis Principia Mathematica*; 2009. Available at: <https://www.gutenberg.org/files/28233/28233-pdf.pdf> [Consulted: October 2023]
14. Moya D, Ramón S, Guiloff L, Terán P, Eid J, Serrano E. Malos resultados y complicaciones en el uso de ondas de choque focales y ondas de presión radial en patología musculoesquelética. *Rehabilitación (Madr)* 2022;56(1):64-73. <https://doi.org/10.1016/j.rh.2021.02.007>
15. Ramon S, Español A, Yebra M, Morillas JM, Unzurrunzaga R, Freitag K, et al. Ondas de choque. Evidencias y recomendaciones SETOC (Sociedad Española de Tratamientos con Ondas de Choque). *Rehabilitación (Madr)* 2021;55(4):291-300. <https://doi.org/10.1016/j.rh.2021.02.002>
16. Cyteval C, Baron-Sarrabère MP, Jorgensen C, Cottin A, Benis J, Sany J, et al. Etude IRM avant et apres lithotritie des tendinopathies calcifiantes de l'épaule [MRI study before and after extracorporeal shock wave therapy in calcifying tendinitis of the shoulder]. *J Radiol* 2003;84(6):681-4. PMID: 12910173
7. Maier M, Milz S, Tischer T, Münzing W, Manthey N, Stäbler A, et al. Influence of extracorporeal shock-wave application on normal bone in an animal model in vivo. Scintigraphy, MRI and histopathology. *J Bone Joint Surg Br* 2002;84(4):592-9. <https://doi.org/10.1302/0301-620x.84b4.11621>
18. d'Agostino MC, Craig K, Tibalt E, Respizzi S. Shock wave as biological therapeutic tool: From mechanical stimulation to recovery and healing, through mechanotransduction. *Int J Surg* 2015;24(Pt B):147-53. <https://doi.org/10.1016/j.ijssu.2015.11.030>
19. Gollmann-Tepeköylü C, Pözl L, Graber M, Hirsch J, Nägele F, Lobenwein D, et al. miR-19a-3p containing exosomes improve function of ischaemic myocardium upon shock wave therapy. *Cardiovasc Res* 2020;116(6):1226-36. <https://doi.org/10.1093/cvr/cvz209>

20. Wang CJ, Huang HY, Pai CH. Shock wave-enhanced neovascularization at the tendon-bone junction: An experiment in dogs. *J Foot Ankle Surg* 2002;41(1):16-22. [https://doi.org/10.1016/s1067-2516\(02\)80005-9](https://doi.org/10.1016/s1067-2516(02)80005-9)
21. Wang CJ. An overview of shock wave therapy in musculoskeletal disorders. *Chang Gung Med J* 2003;26(4):220-32. PMID: 12846521
22. Brañes J, Contreras HR, Cabello P, Antonic V, Guiloff LJ, Brañes M. Shoulder rotator cuff responses to extracorporeal shockwave therapy: Morphological and immunohistochemical analysis. *Shoulder & Elbow* 2012;4(3):163-8. <https://doi.org/10.1111/j.1758-5740.2012.00178.x>
23. Vavken P, Holinka J, Rompe JD, Dorotka R. Focused extracorporeal shock wave therapy in calcifying tendinitis of the shoulder: a meta-analysis. *Sports Health* 2009;1(2):137-44. <https://doi.org/10.1177/1941738108331197>
24. Verstraelen FU, In den Kleef NJ, Jansen L, Morrenhof JW. High-energy versus low-energy extracorporeal shock wave therapy for calcifying tendinitis of the shoulder: which is superior? A meta-analysis. *Clin Orthop Relat Res* 2014;472(9):2816-25. <https://doi.org/10.1007/s11999-014-3680-0>
25. Zhang L, Cui Y, Liang D, Guan J, Liu Y, Chen X. High-energy focused extracorporeal shock wave therapy for bone marrow edema syndrome of the hip: A retrospective study. *Medicine (Baltimore)* 2020;99(16):e19747. <https://doi.org/10.1097/MD.00000000000019747>
26. Cleveland RO, Chitnis PV, McClure SR. Acoustic field of a ballistic shock wave therapy device. *Ultrasound Med Biol* 2007;33(8):1327-35. <https://doi.org/10.1016/j.ultrasmedbio.2007.02.014>
27. Gonkova MI, Ilieva EM, Ferriero G, Chavdarov I. Effect of radial shock wave therapy on muscle spasticity in children with cerebral palsy. *Int J Rehabil Res* 2013;36(3):284-90. <https://doi.org/10.1097/MRR.0b013e328360e51d>
28. Reddy AK, Scott J, Checketts JX, Fishbeck K, Boose M, Stalling L, et al. Levels of evidence backing the AAOS clinical practice guidelines. *J Orthop Trauma Rehab* 2021. <https://doi.org/10.1177/2210491721992533>
29. Blom AW, Donovan RL, Beswick AD, Whitehouse MR, Kunutsor SK. Common elective orthopaedic procedures and their clinical effectiveness: umbrella review of level 1 evidence. *BMJ* 2021;374(1):n1511. <https://doi.org/10.1136/bmj.n1511>
30. Moya D, Wei S, Simplicio C, Guiloff L, Kwangsun P, Di Giorno A, et al. Scientific evidence of shock waves in Orthopedics and Traumatology: It is time to set the record straight. *Journal of Regenerative Science* 2023;3(1):1-6. <https://doi.org/10.13107/jrs.2023.v03.i01.67>
31. Burkhart SS. Shoulder arthroscopy: a bridge from the past to the future. *J Shoulder Elbow Surg* 2020;29(8):e287-e296. <https://doi.org/10.1016/j.jse.2020.04.011>
32. Wright JG, Einhorn TA, Heckman JD. Grades of recommendation. *J Bone Joint Surg Am* 2005;87(9):1909-10. <https://doi.org/10.2106/JBJS.8709.edit>
33. Thomas JL, Christensen JC, Kravitz SR, Mendicino RW, Schuberth JM, Vanore JV, et al. The diagnosis and treatment of heel pain: a clinical practice guideline-revision 2010. *J Foot Ankle Surg* 2010;49(3 Suppl):S1-19. <https://doi.org/10.1053/j.jfas.2010.01.00>
34. Chen L, Ye L, Liu H, Liu P, Yang B. Extracorporeal shock wave therapy for the treatment of osteoarthritis: A systematic review and meta-analysis. *Biomed Res Int* 2020;18;2020:1907821. <https://doi.org/10.1155/2020/1907821>
35. Alsaikhan B, Andonian S. Shock wave lithotripsy in patients requiring anticoagulation or antiplatelet agents. *Can Urol Assoc J* 2011;5(1):53-7. <https://doi.org/10.5489/cuaj.09140>
36. Eid J, Moya D. Quality standards and techniques for the application of focused shockwaves and radial pressure waves in musculoskeletal disorders. *Journal of Regenerative Science* 2021;1(1):9-12. <https://doi.org/10.13107/jrs.2021.v01.i01.007>
37. Smith DP, Graham JB, Prystowsky JB, Dalkin BL, Nemcek AA Jr. The effects of ultrasound-guided shock waves during early pregnancy in Sprague-Dawley rats. *J Urol* 1992;147(1):231-4. [https://doi.org/10.1016/s0022-5347\(17\)37203-8](https://doi.org/10.1016/s0022-5347(17)37203-8)
38. Wang CJ, Huang HY, Yang K, Wang FS, Wong M. Pathomechanism of shock wave injuries on femoral artery, vein and nerve. An experimental study in dogs. *Injury* 2002;33(5):439-46. [https://doi.org/10.1016/s0020-1383\(02\)00005-0](https://doi.org/10.1016/s0020-1383(02)00005-0)
39. Ubee SS, Kasi VS, Bello D, Manikandan R. Implications of pacemakers and implantable cardioverter defibrillators in urological practice. *J Urol* 2011;186(4):1198-205. <https://doi.org/10.1016/j.juro.2011.02.2697>
40. Furia JP, Juliano PJ, Wade AM, Schaden W, Mittermayr R. Shock wave therapy compared with intramedullary screw fixation for nonunion of proximal fifth metatarsal metaphyseal-diaphyseal fractures. *J Bone Joint Surg Am* 2010;92(4):846-54. <https://doi.org/10.2106/JBJS.I.00653>
41. Notarnicola A, Moretti L, Tafuri S, Gigliotti S, Russo S, Musci L, et al. Extracorporeal shockwaves versus surgery in the treatment of pseudoarthrosis of the carpal scaphoid. *Ultrasound Med Biol* 2010;36(8):1306-13. <https://doi.org/10.1016/j.ultrasmedbio.2010.05.004>

42. Liu HM, Chao CM, Hsieh JY, Jiang CC. Humeral head osteonecrosis after extracorporeal shock-wave treatment for rotator cuff tendinopathy. A case report. *J Bone Joint Surg Am* 2006;88(6):1353-6. <https://doi.org/10.2106/JBJS.E.00868>
43. Lorbach O, Kusma M, Pape D, Kohn D, Dienst M. Influence of deposit stage and failed ESWT on the surgical results of arthroscopic treatment of calcifying tendonitis of the shoulder. *Knee Surg Sports Traumatol Arthrosc* 2008;16(5):516-21. <https://doi.org/10.1007/s00167-008-0507-0>
44. Rompe JD, Zoellner J, Nafe B. Shock wave therapy versus conventional surgery in the treatment of calcifying tendinitis of the shoulder. *Clin Orthop Relat Res* 2001;(387):72-82. <https://doi.org/10.1097/00003086-200106000-00010>
45. Rebuzzi E, Coletti N, Schiavetti S, Giusto F. Arthroscopy surgery versus shock wave therapy for chronic calcifying tendinitis of the shoulder. *J Orthop Traumatol* 2008;9(4):179-85. <https://doi.org/10.1007/s10195-008-0024-4>
46. Haake M, Rautmann M, Wirth T. Assessment of the treatment costs of extracorporeal shock wave therapy versus surgical treatment for shoulder diseases. *Int J Technol Assess Health Care* 2001;17(4):612-7. PMID: 11758305
47. Moya D, Gómez D, Velóz Serrano D, Bernáldez Domínguez P, Dallo Lazzarini I, Gómez G. Treatment protocol for rotator cuff calcific tendinitis using a single-crystal piezoelectric focused shock wave source. *J Vis Exp* 2022;(190). <https://doi.org/10.3791/64426>