

# Solitary Calcaneal Osteochondroma with Growth After Skeletal Maturity. Case Report and Literature Review

Juan Manuel Trebino Molteni,\* Leticia I. Rodríguez,\*\* Pablo Paitampoma Álvarez,\* Francel Campoverde Imbaquingo\*

\*Leg and Foot Sector, Orthopedics and Traumatology Service, Hospital Provincial "Gobernador Domingo Mercante", Buenos Aires, Argentina.

\*\*Leg and Foot Sector, Orthopedics and Traumatology Service, Clínica Modelo de Lanús, Buenos Aires, Argentina.

## ABSTRACT

Osteochondroma is the most common benign bone tumor, accounting for 35% of benign bone tumors and 8% of bone tumors. It is formed by an exostosis of trabecular bone covered with cartilage that affects the metaphyseal region of long bones, from the growth plate, around the knee, in the shoulder or wrist, and it is extremely rare in the phalanges of the hand or foot. It grows during childhood and adolescence until skeletal maturity. Therefore, its growth in an adult suggests a malignant transformation into chondrosarcoma, although there are also reports without malignancy. Furthermore, the calcaneus is a short bone, so the appearance of this type of injury would be pathophysiologically unexpected. Our objective is to present a case of solitary calcaneal osteochondroma with growth after skeletal maturity, its diagnosis and treatment, as well as a review of the literature. Its relevance stems from the scarcity of literature, its uncommon location, and the possibility of malignancy.

**Keywords:** Calcaneus; osteochondroma.

**Level of Evidence:** IV

## Osteocondroma de calcáneo solitario con crecimiento después de la madurez esquelética. Reporte de un caso y revisión bibliográfica

## RESUMEN

El osteocondroma es el tumor óseo benigno más frecuente, representa el 35% de los tumores óseos benignos y el 8% de los tumores óseos. Está formado por una exostosis de hueso trabecular recubierta de cartílago que afecta la región metafisaria de los huesos largos, a partir del cartílago de crecimiento, alrededor de la rodilla, en el hombro o la muñeca, y es extremadamente raro en las falanges de la mano o el pie. Crece durante la niñez y la adolescencia hasta alcanzar la madurez esquelética; por lo tanto, su crecimiento en un adulto sugiere la transformación maligna en condrosarcoma, aunque también existen reportes sin malignización. Además, el calcáneo es un hueso corto, por lo que, desde el punto de vista fisiopatológico, sería inesperada la aparición de este tipo de lesión. El objetivo de este artículo es presentar un caso de osteocondroma de calcáneo solitario con crecimiento después de la madurez esquelética, su diagnóstico, tratamiento, así como una revisión bibliográfica. Esta presentación de caso es importante, dados la localización infrecuente y el potencial de transformación maligna del osteocondroma, y la escasa bibliografía sobre el tema.

**Palabras clave:** Osteocondroma; calcáneo.

**Nivel de Evidencia:** IV

## INTRODUCTION

Osteochondroma is the most common benign bone tumor, accounting for 35% of benign bone tumors and 8% of bone tumors.<sup>1,2</sup> It is formed by an exostosis of cartilage-covered trabecular bone that affects the metaphyseal region of the long bones, starting from the growth plate, around the knee, in the shoulder or wrist, and is extremely rare in the phalanges of the hand or foot.<sup>3,4</sup>

Received on November 26<sup>th</sup>, 2023 Accepted after evaluation on February 15<sup>th</sup>, 2024 • Dr. JUAN MANUEL TREBINO MOLTENI • mtrebino@gmail.com  <https://orcid.org/0009-0001-0643-8391>

**How to cite this article:** Trebino Molteni JM, Rodríguez LI, Paitampoma Álvarez P, Campoverde Imbaquingo F. Solitary Calcaneal Osteochondroma with Growth After Skeletal Maturity. Case Report and Literature Review. *Rev Asoc Argent Ortop Traumatol* 2024;89(2):176-189. <https://doi.org/10.15417/issn.1852-7434.2024.89.2.1855>

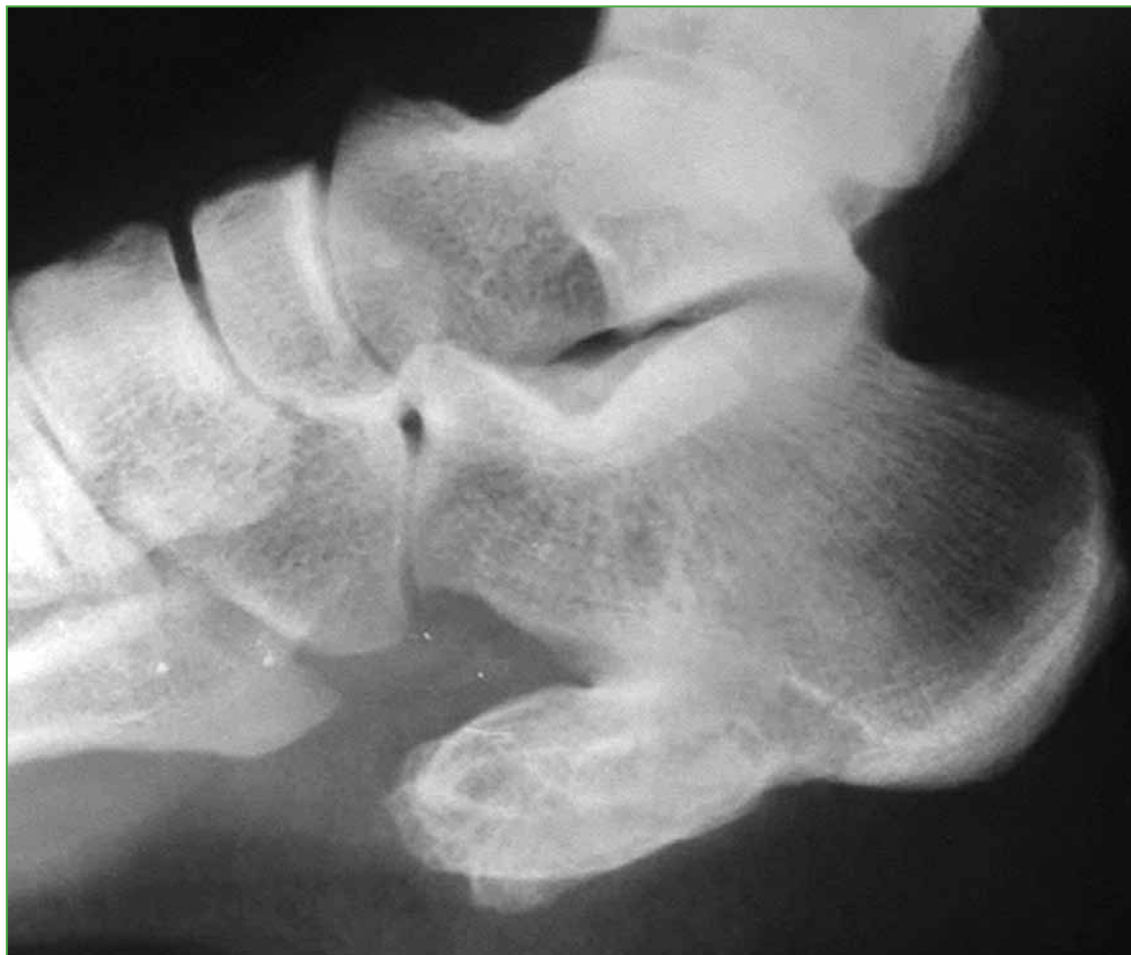Most osteochondromas are asymptomatic, but may cause mechanical symptoms depending on size and location.<sup>5</sup> They grow during childhood and adolescence until skeletal maturity is reached. Therefore, their growth in adults suggests malignant transformation to chondrosarcoma.<sup>1</sup> However, cases without malignant transformation have also been published.<sup>6-21</sup>

Osteochondromas in the ankle and foot are infrequent (10%), and the calcaneus is an extremely unusual site.<sup>12</sup> Moreover, it is a short bone and, in the context of skeletal maturity, the occurrence of this type of lesion is unexpected from a pathophysiological point of view.

The aim of this article is to present a case of solitary calcaneal osteochondroma with growth after skeletal maturity, including its diagnosis, treatment, and a literature review. The relevance of this publication lies in the scarce literature on this condition, and the infrequent location and malignant potential of osteochondroma.

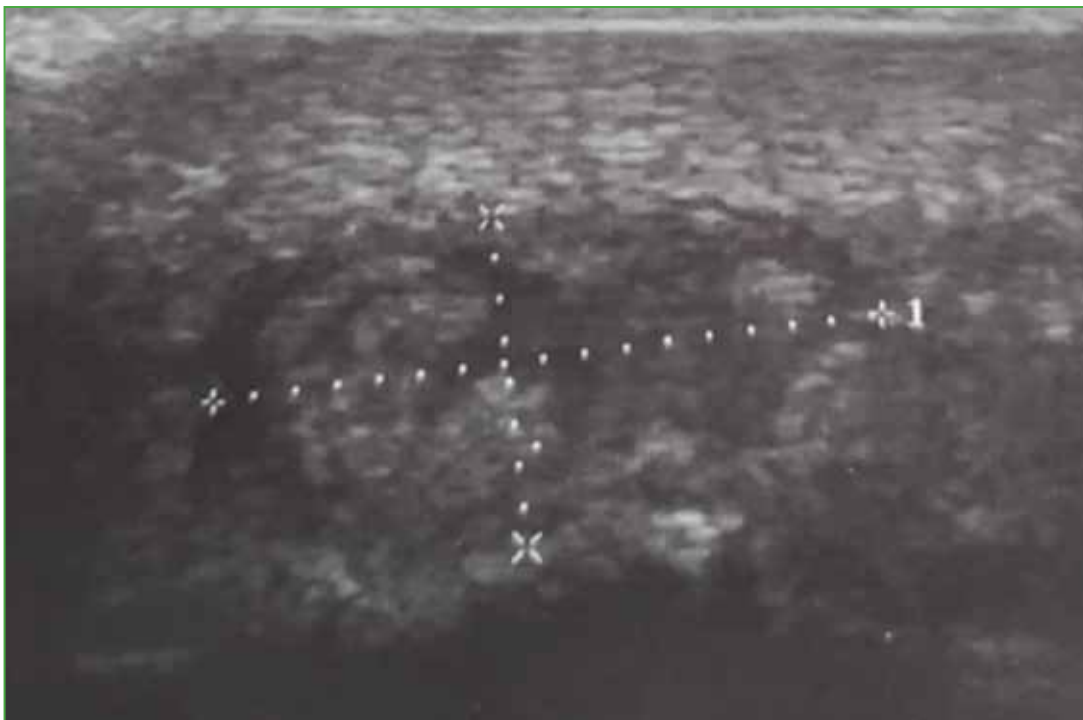
## CLINICAL CASE

A 24-year-old man consulted the Orthopedics and Traumatology Department of our institution for the first time in June 2022, due to discomfort and a palpable tumor in the plantar region, with no significant history of trauma. Physical examination revealed a hard, immobile tumor that had evolved over three years, with significant growth in the last few months, and was accompanied by difficulty standing, walking, and putting on shoes. The ankle and hindfoot joints had full range of motion, with no stiffness. Radiographs were requested and showed an isolated, large, pedunculated, radiopaque image arising from the plantar aspect of the calcaneus and extending towards the metatarsals (Figure 1).



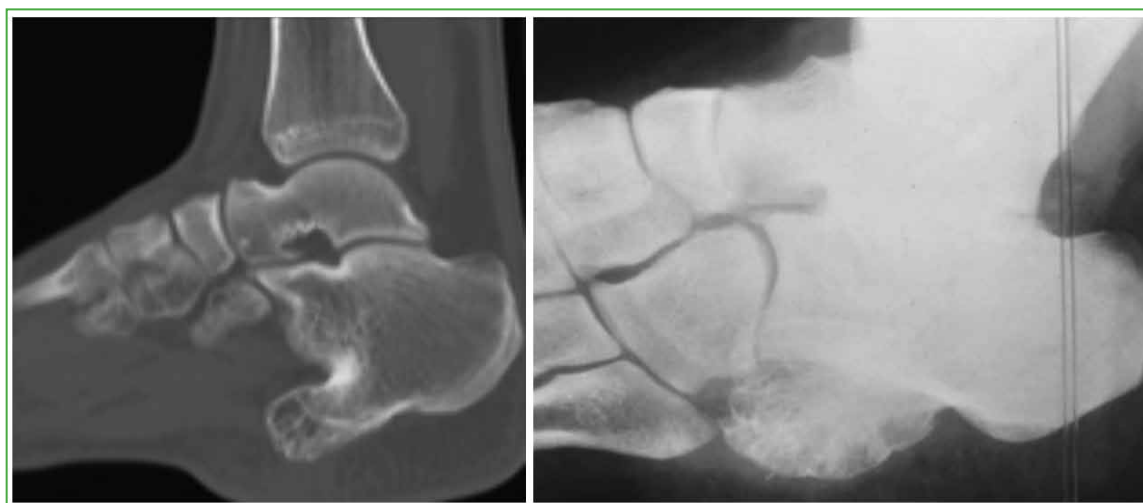**Figure 1.** Preoperative foot radiograph, lateral view. A large, pedunculated tumor with clear borders is observed, emerging from the plantar base of the calcaneus.

In addition, radiographs of all long bones, pelvis and spine were obtained, revealing the absence of other osteochondromas, and ruling out the diagnosis of hereditary multiple exostoses. Ultrasonography showed plantar fascia enthesitis with a calcaneal spur (Figure 2).



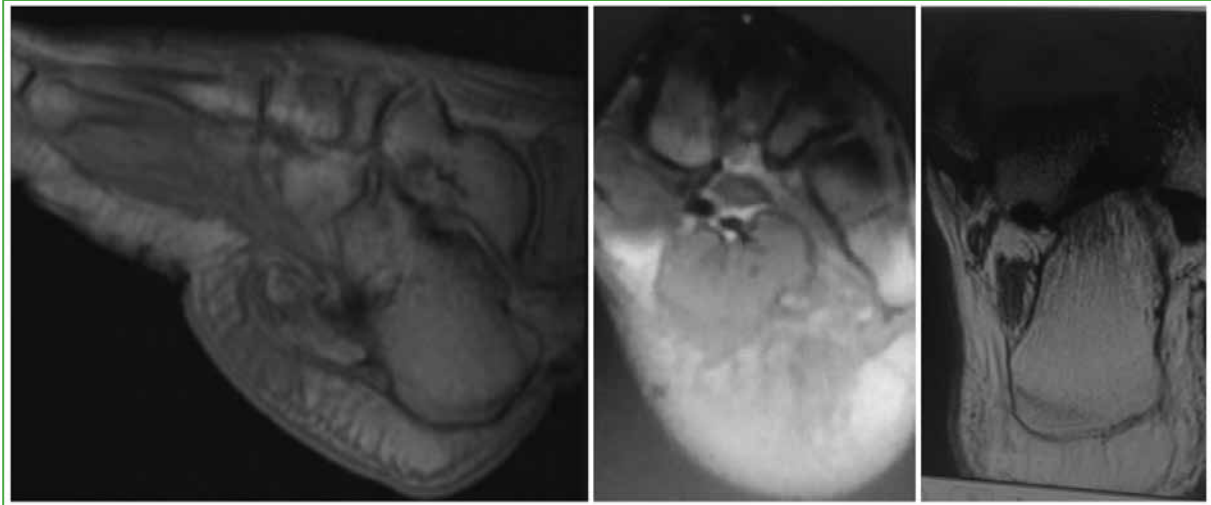
**Figure 2.** Soft tissue ultrasound of the sole of the left foot. An echogenic image compatible with enthesitis and chronic plantar fasciitis with a calcaneal spur is visualized.

The computed tomography revealed an isolated exostosis with defined borders, medullary and cortical continuity with normal bone, images consistent with an osteochondroma, and complete closure of the epiphyseal plate (Figure 3).



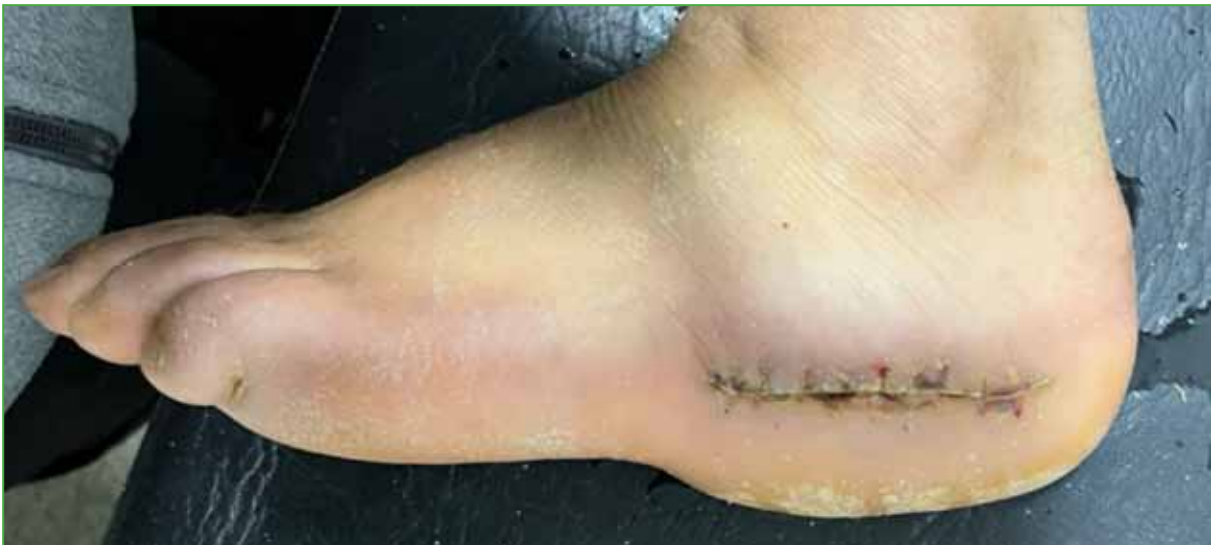**Figure 3.** Multislice computed tomography of the left ankle. Complete closure of the epiphyseal plate and a sharp-edged lesion emerging from the plantar aspect of the calcaneus are observed.

Magnetic resonance imaging revealed that the tumor was not connected to soft tissues (Figure 4).



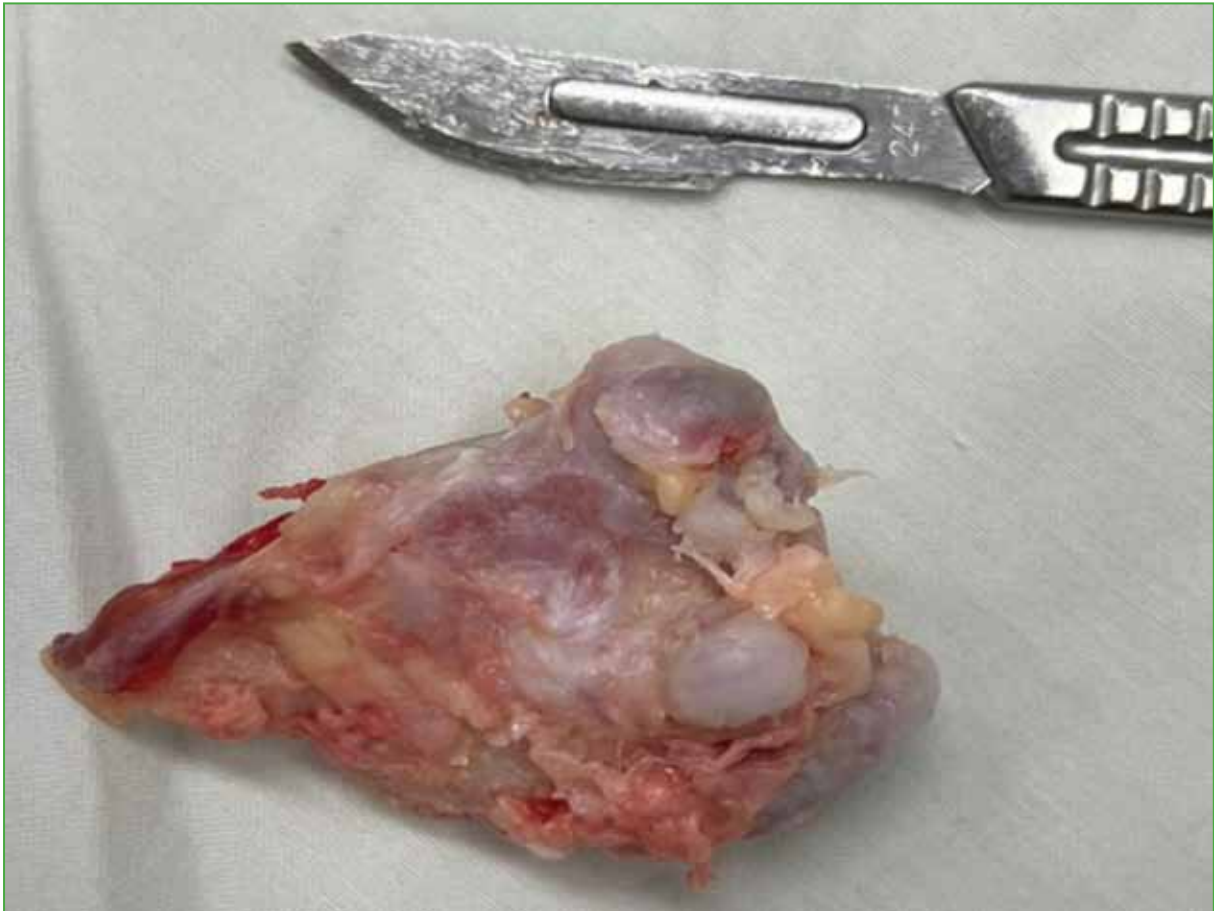
**Figure 4.** MRI of the left ankle. The tumor emerging from the plantar aspect of the calcaneus is not attached to the soft tissues.

Considering the symptoms and that the images showed a single, encapsulated tumor with benign characteristics, it was decided to perform an excisional biopsy by lateral approach (horizontal branch of Benirschke's extended lateral approach) (Figure 5) on August 30, 2022.



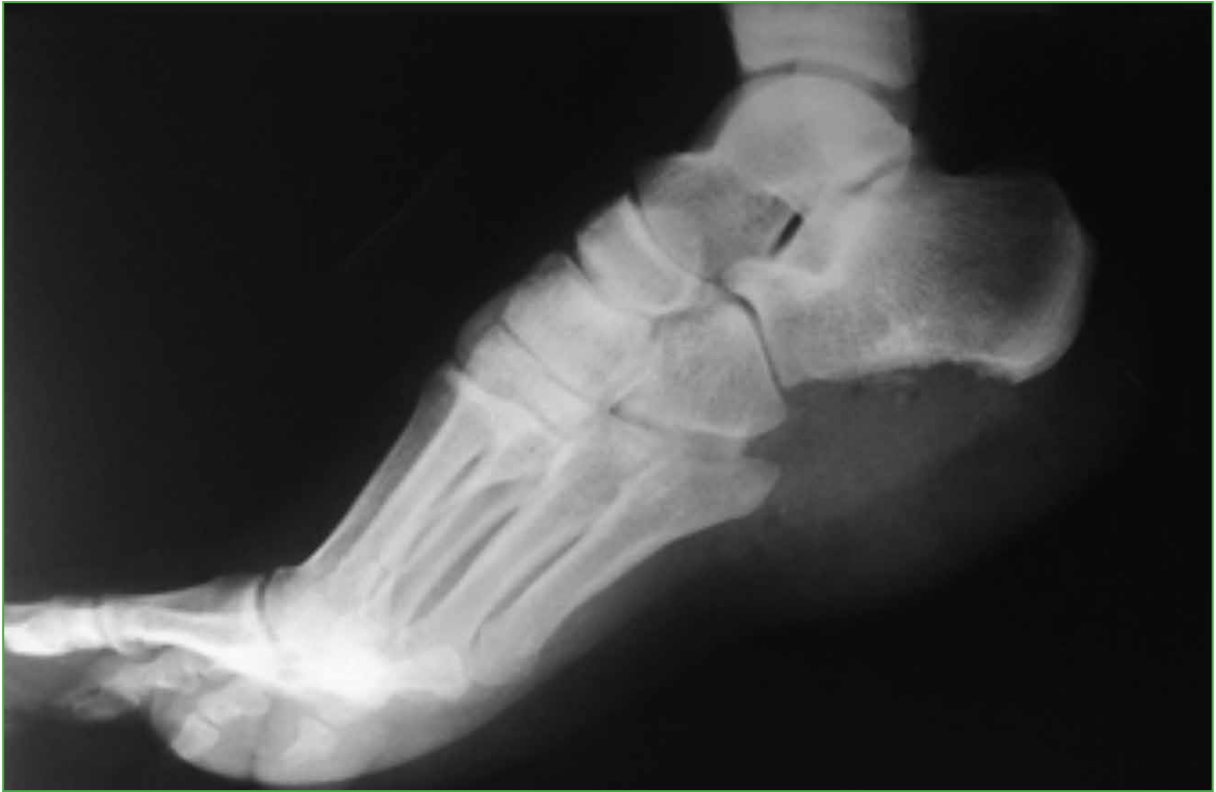**Figure 5.** Surgical approach used.

The patient was placed in the right lateral decubitus position, under spinal anesthesia and with a homolateral supramalleolar tourniquet. Given that the tumor was not attached to the soft tissues and had the macroscopic appearance of osteochondroma, it was completely resected in one piece (70 mm x 50 mm x 30 mm, [Figure 6](#)) with a safety margin via an osteotomy from the base using a laminar spreader. Finally, the entire specimen was sent for a pathology report.



**Figure 6.** Tumor resected in one piece.

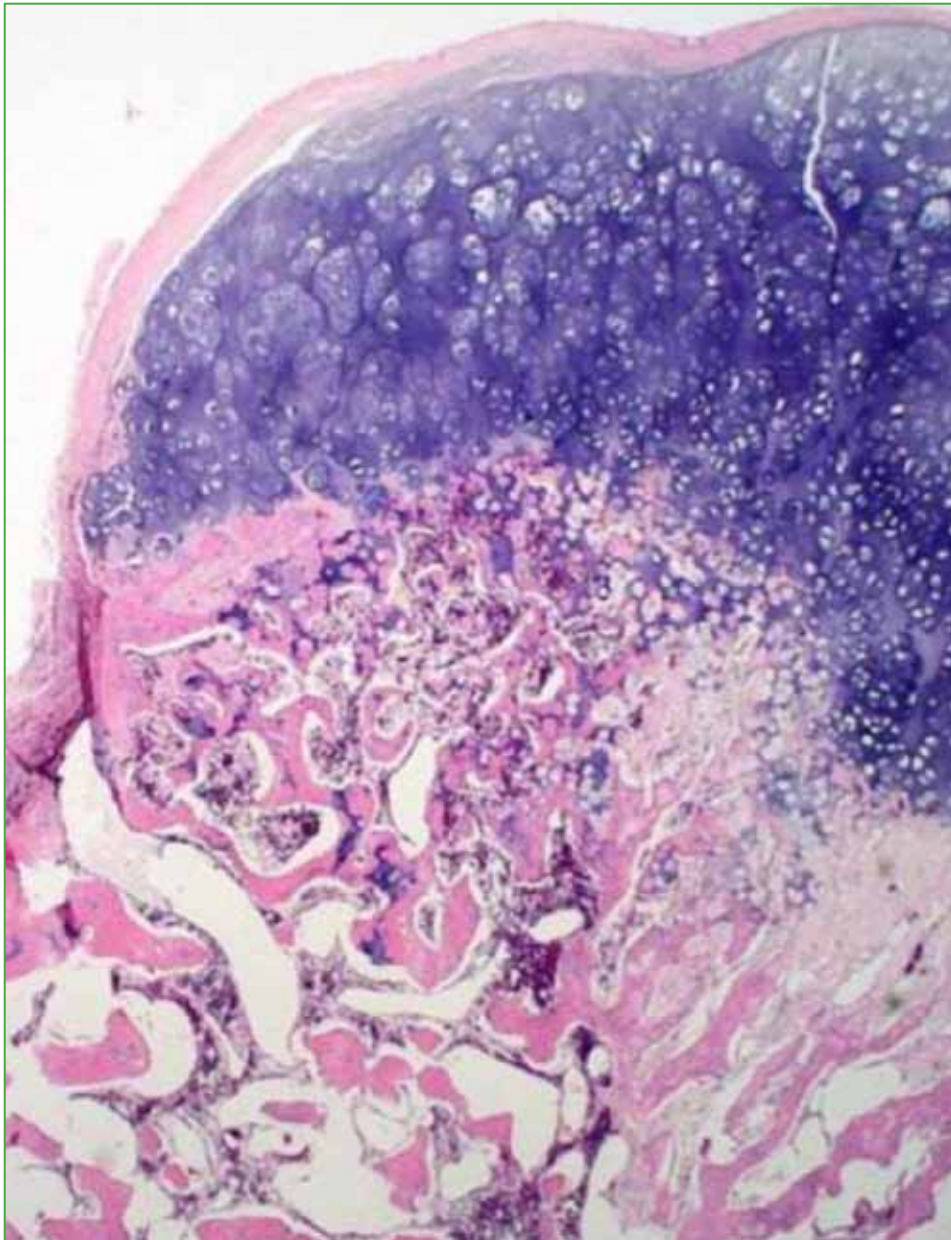
The patient's postoperative recovery progressed well, and radiographs showed that the tumor had been completely removed (Figure 7).



**Figure 7.** Postoperative radiograph of the left ankle, lateral view, showing complete tumor resection.

Five weeks later, the pathology report confirmed an osteochondroma of typical architecture (Figure 8), with chondrocytes arranged in groups and no morphological evidence of secondary malignant transformation.

Although the follow-up period is only one year, the clinical evolution will be monitored.



**Figure 8.** Pathology analysis compatible with osteochondroma.

## DISCUSSION

Osteochondroma is the most frequent benign bone tumor, accounting for 35% of benign bone tumors and 8% of bone tumors; however, because many cases are asymptomatic, the incidence is likely higher than reported.<sup>1,2</sup> It is a developmental anomaly that grows from the physis and is composed of bone covered by a thin layer of growth plate that retains all of its histologic characteristics.<sup>3,4</sup> The majority (85%) manifest as solitary, non-inherited lesions, while 15% occur in the context of hereditary multiple exostoses, a genetic disorder inherited in an autosomal dominant manner and associated with germline mutations in the *EXT1* or *EXT2* tumor suppressor genes in nearly 90% of cases.<sup>1</sup> It is more common in males (1.5:1), and in the first and second decades of life.<sup>5</sup>

It is usually located in the long bones and exceptionally in the bones of the hands and feet (usually in the phalanges). It appears during adolescence, during the period of greatest growth of the long bones, causing symptoms around the knee, shoulder or wrist, where the greatest activity of these cartilages occurs. Its expansion stops with the cessation of growth and closure of the epiphyseal plates, and the lesion remains inactive.<sup>3,4</sup> For this reason, the appearance of pain in a previously stable lesion, as well as accelerated or new growth, growth beyond skeletal maturity, or large lesions may indicate malignant transformation to chondrosarcoma,<sup>14,22-24</sup> which occurs in 1% of solitary osteochondromas and up to 10% of cases of hereditary multiple exostoses.<sup>12,14</sup> Willms et al. included a case of malignant transformation of a calcaneal osteochondroma in a literature review of 50 cases.<sup>23</sup> Malik et al. reported a solitary osteochondroma of the calcaneus that transformed into chondrosarcoma.<sup>24</sup> In a review of 75 cases of chondrosarcoma secondary to osteochondroma, Garrison et al. identified chondrosarcoma of the calcaneus in a patient with hereditary multiple exostoses.<sup>22</sup>

Chondrosarcoma secondary to an osteochondroma is often a well-differentiated tumor that is histologically close to the cartilage layer with increased chondrocyte cellularity and significant cytologic atypia, without extensive myxoid changes. For this reason, its diagnosis is based first on the architectural appearance of the cartilaginous layer and not on its thickness. Malignant transformation alters the cap's architecture, which is destroyed by thin fibrous septa, resulting in a lobulated architecture at low magnification, and some may detach and penetrate the peripheral soft tissues.<sup>12</sup>

The characteristic clinical presentation of this tumor is a palpable, hard, immobile mass. Some patients suffer from symptoms, especially pain due to bursitis, tendon or muscle inflammation due to friction, or vascular or nerve compression.<sup>5</sup>

Plain radiographs (which are frequently diagnostic on their own) and further imaging procedures such as a CT scan, MRI, or bone scan are used for surgical planning or to rule out sarcomatous degeneration in osteochondromas.<sup>14</sup>

Radiography is the main diagnostic method, allowing visualization of classic features such as orientation, medullary continuity, and whether the tumor is pedunculated or sessile.<sup>14</sup> On the other hand, ultrasonography can be used to measure the thickness of the hyaline cartilage layer. However, ultrasonography is an operator-dependent study with limited utility in obese patients and minimal relevance to the tumor's bone components.<sup>15</sup> Computed tomography, especially with multiplanar reconstruction, is useful for localizing the tumor and planning its resection,<sup>12</sup> and can determine whether the growth plates are closed.<sup>12</sup> Magnetic resonance imaging shows the extent of the lesion, the possible involvement of soft tissues, and the thickness and location of the cartilage layer. A thick cartilage layer that has a high signal intensity on the T2-weighted sequence may suggest malignant transformation.<sup>5,12,14,15</sup> On bone scans, osteochondromas may appear as focal uptake adjacent to the growth plate, especially in patients whose skeleton has not yet reached maturity. Stable tumors in adults may not show uptake. Bone scintigraphy is useful for detecting asymptomatic deep tumors, especially in the context of hereditary multiple exostoses, but is not specific for distinguishing between osteochondromas and malignant chondrosarcomas.<sup>14</sup>

The differential diagnosis includes benign and malignant primary bone tumors, as well as a spectrum of reactive bone disorders, such as Turret's exostosis, bizarre parosteal osteochondromatous proliferation, and florid reactive periostitis.<sup>14</sup> On the other hand, calcaneal spurs are traction lesions located at the insertion site of the plantar aponeurosis and are not true osteochondromas.<sup>14</sup>

When lesions are asymptomatic, the behavior is expectant, with clinical and radiographic follow-up. However, symptomatic lesions or lesions that grow after skeletal maturity require complete surgical excision with a tumor-free resection margin, as any remnant may lead to recurrence.<sup>14,15,22</sup>

There are only a few reports of calcaneal osteochondroma with growth after skeletal maturity.<sup>6-21</sup>

In 1992, Techner and DeCarlo reported a case of osteochondroma in a unilateral peroneal tubercle with symptoms in association with peroneal tenosynovitis in a runner, suggesting microtrauma and long-term repetitive stress as possible etiological factors.<sup>6</sup>

Martin et al. presented two patients with stenosing tenosynovitis of the peroneal tendons caused by an osteochondroma of the peroneal tubercle of several years' evolution. One 25-year-old woman and one 48-year-old woman improved after resection. The histologic report reported a benign osteochondroma. Clinical and radiological follow-up at 10 and 2 years, respectively, showed no recurrence.<sup>7</sup>



Sella and Chrostowski reported two cases of calcaneal osteochondromas with accelerated growth from the plantar region that were treated with excision via a plantar approach: one in a 6-year-old child and the other in a 71-year-old woman, with no histological evidence of malignancy.<sup>8</sup>

Karakurum et al. reported a case of bilateral symmetric solitary osteochondroma of the peroneal tubercle in a 24-year-old woman. The osteochondroma was discovered when the lesion on the left side became symptomatic and was resected through a lateral approach. Pathologists confirmed the disease, but it is unclear whether it is a real osteochondroma or tubercle hypertrophy.<sup>9</sup>

Sánchez-Mariscal Díaz et al. published the case of a 69-year-old patient with stenosing tenosynovitis of the peroneal tendons caused by osteochondroma of the peroneal tubercle of two years' evolution. The histological report confirmed the diagnosis of benign osteochondroma. No recurrence was observed three years after surgery.<sup>10</sup>

Akmaz et al. described a case of calcaneal plantar osteochondroma, approximately 5 cm in diameter, in a 21-year-old man, with progressive pain (10 months), especially with excessive weight bearing during military training. The diagnosis was corroborated histologically and symptoms resolved within two months of resection by a lateral approach.<sup>11</sup>

Nogier et al. reported an osteochondroma in a 36-year-old man who, after nine years of follow-up, had extensive growth (60 mm x 55 mm x 30 mm; cartilage thickness 12 mm) on the inferolateral aspect of the calcaneus. Histological analysis confirmed the presumptive diagnosis, although without signs of malignancy, and there was no recurrence throughout the four-year follow-up period after surgical excision.<sup>12</sup>

Uğurlu et al. published the first case of bilateral peroneal tendon stenosing tenosynovitis secondary to osteochondroma of the peroneal tubercles and bilateral os peroneum. The 23-year-old woman made a full recovery after the operation. The pathology diagnosis was osteochondroma of the calcaneus without malignant degeneration.<sup>13</sup>

Blitz and Lopez reported a large osteochondroma (80 mm x 42 mm x 21 mm) of the medial inferior calcaneal tubercle in a 40-year-old woman with a history of painful mass of six months' evolution. A biopsy of the tumor confirmed its benign nature, so, two months later, a complete excision was performed through a medial incision. At 3.5 years of follow-up, no recurrences were observed, but the patient never recovered her initial level of activity and was unable to return to work.<sup>14</sup>

Koplay et al. described the case of an osteochondroma of one year of evolution, located in the posteromedial region of the calcaneus, in a 25-year-old woman. There was transient improvement after surgical excision, but it subsequently manifested with pain and rapid growth (18 mm x 12 mm; cartilage thickness 6 mm), so it was reoperated six months later. The pathology report again revealed a benign osteochondroma. No tumor recurrence was detected during the nine months following the second excision.<sup>15</sup>

Jung et al. reported a case of an exceptionally large Haglund's deformity (32 mm x 23 mm x 21 mm) in a 22-year-old woman, which had developed over the previous decade. Surgical resection of the prominence and retrocalcaneal bursa was performed, as well as reinsertion of the Achilles using 3.5 mm harpoons. Histopathological analysis confirmed the diagnosis of calcaneal osteochondroma, this is the first time this situation has been reported. There was no recurrence 18 months after surgery.<sup>16</sup>

Kumar et al. presented a case of symptomatic retrocalcaneal bursitis in a 58-year-old farmer due to the late growth of a posteromedial osteochondroma of the calcaneus. The tumor (31 mm x 17 mm; cartilage thickness 4 mm) and the bursa were removed through a posterolateral approach. After six months of follow-up, there was no sign of malignancy on histological testing and no recurrence, however the ankle joint's range of motion remained limited.<sup>17</sup>

Koh et al. published the case of a 41-year-old obese patient with long-standing left heel pain. He was treated for plantar fasciitis and gastrocnemius contracture, but both conservative and surgical treatments proved ineffective. MRI revealed a plantar, posterolateral osteochondroma (11 mm x 9 mm) that was removed en bloc and confirmed by histology. No recurrence was detected within nine months after resection.<sup>18</sup>

Raviraj et al. reported a case of bilateral Haglund's syndrome secondary to calcaneal osteochondroma, a situation never reported in the English literature. After resection of the tumor and retrocalcaneal bursa, histopathological study revealed no malignancy. The condition had not recurred at the two-year follow-up.<sup>19</sup>

Bilekli presented the first case of bilateral peroneal tendon tear, together with edema of the calcaneal bone marrow, secondary to osteochondroma of the peroneal tubercle. The 50-year-old patient underwent surgery (resection and tubularization) in the lateral decubitus position. The pathology report confirmed a benign osteochondroma. No recurrences were detected after a year of follow-up.<sup>20</sup>

Avramidis et al. reported an osteochondroma (45 mm x 30 mm x 25 mm) in the lateral process of the calcaneal tuberosity, of seven years of evolution, in a 27-year-old patient. After surgical removal of the tumor, the histological study showed no malignancy, and there were no recurrences during the three years of follow-up.<sup>21</sup>

Our report is another case of extensive growth of a calcaneal osteochondroma after epiphyseal plate closure that, after excision, was confirmed as benign on histopathologic examination. The patient quickly recovered his previous level of activity shortly after surgery, and no recurrences were observed during one year of follow-up.

In this presentation, we report one of the largest solitary calcaneal osteochondromas (70 mm x 50 mm x 30 mm) described in the literature, along with those of Blitz and Lopez<sup>14</sup> and Nogier et al.<sup>12</sup>

The Table summarizes the 18 reports to date, including ours. No differences were found in the distribution by sex (9 men vs. 9 women), the mean age was 38.7 years (range 21-71), and the most affected side was the right (12 of 18 cases), although on three occasions, it occurred bilaterally. The most frequent location was in the peroneal tubercle (7 of 18 cases), followed by the inferior region of the calcaneus (2 of 18 cases), the inferolateral region of the calcaneus (2 of 18 cases), the dorsum of the protuberance (2 of 18 cases), the posteromedial region (2 of 18 cases), the inferior medial tubercle (1 of 18 cases), and the lateral process of the calcaneal tuberosity (1 of 18 cases). Its manifestations included a painful mass in the heel (8 of 18 cases), peroneus longus lateralis tendonitis (5 of 18 cases), Haglund's deformity (2 of 18 cases), a tear of both peroneal tendons (1 of 18 cases), and plantar fasciitis with gastrocnemius contracture (1 of 18 cases). Treatment was always excision, sometimes accompanied by tenosynovectomy (4 of 18 cases), bursectomy (3 of 18 cases), Achilles reinsertion (1 of 18 cases) and tubularization (1 of 18 cases). The most commonly used approach was lateral (6 of 18 cases), followed by posterolateral (3 of 18 cases), curvilinear, posterior to the lateral malleolus (1 of 18 cases), plantar (1 of 18 cases), medial (1 of 18 cases), and medial to the Achilles tendon (1 of 18 cases). Only eight reports indicated the size of the tumor, with the largest measuring 80 mm x 42 mm x 21 mm,<sup>14</sup> in this present report (70 mm x 50 mm x 30 mm), 60 mm x 55 mm x 30 mm,<sup>12</sup> 45 mm x 30 mm x 25 mm,<sup>21</sup> 32 mm x 23 mm x 21 mm,<sup>16</sup> 31 mm x 17 mm,<sup>17</sup> 18 mm x 12 mm,<sup>15</sup> 11 mm x 9 mm.<sup>18</sup> Of these, only four specified cartilage thickness at 12 mm,<sup>12</sup> two at 18 mm,<sup>14</sup> 6 mm,<sup>15</sup> and 4 mm.<sup>17</sup> There were no recurrences of the lesion and only one patient had postoperative complications requiring surgical drainage of a large hematoma, four days after surgery and 40 days after the second surgery. *Escherichia coli* was isolated, and amoxicillin with clavulanic acid was indicated for 20 days.<sup>12</sup> The average follow-up was 2.4 years (range 6 months-10 years), no clinical or radiological recurrences were observed, although one patient was left with a permanent work disability.<sup>14</sup> The location in the peroneal tubercle is the most frequent and this may attract attention, but it would be difficult to generate future lines of research due to the infrequency of the lesion.

## CONCLUSIONS

Calcaneal osteochondromas are extremely rare, and most are asymptomatic. They should be treated conservatively unless they cause symptoms such as pain, have rapid or new growth, increase in size after skeletal maturity or show signs of malignant transformation. In these cases, imaging studies and an extensive resection with healthy bone margins are necessary. Inadequate excision of the remaining cartilage layer can lead to tumor recurrence.

However, benign osteochondromas can grow and become symptomatic in skeletally mature patients without malignant transformation. We present a case of giant solitary osteochondroma of the calcaneus in a skeletally mature patient. This is one of the few and largest osteochondromas reported in the international literature.

**Table.** Published cases of solitary calcaneal osteochondroma with growth after skeletal maturity.

Author	Year	Gender	Age (years)	Side	Trauma/History	Preoperative symptoms	Duration of preoperative symptoms	Intraoperative findings	Tumor size (mm)	Cartilage thickness (mm)	Surgery	Anesthesia	Position	Approach	Complications	Follow-up	Outcomes (clinical and radiographic)
Teichler and DeCarlo <sup>6</sup>	1992	M	NR	NR	Runner (microtrauma and long-term repetitive stress)	Peroneal tendon impingement	NR	Osteochondroma in peroneal tubercle	NR	NR	NR	NR	NR	NR	NR	NR	NR
Martin et al. <sup>7</sup>	1995	F	48	R	NR	Distal peroneal tendonitis	10 years	Osteochondroma in peroneal tubercle, peroneus longus tenosynovitis	NR	NR	Excision, tenosynovectomy	NR	NR	NR	NR	2 years	Asymptomatic
Martin et al. <sup>7</sup>	1995	F	25	R	Recurrent sprains	Distal peroneal tendonitis	5 years	Osteochondroma in peroneal tubercle (negative pathology), peroneus longus tenosynovitis	NR	NR	Excision, tenosynovectomy	NR	NR	NR	NR	10 years	No recurrence
Sella and Chrostowski <sup>8</sup>	1995	F	71	L	NR	Heel pain and mass	NR	Osteochondroma in the inferior region of the calcaneum	NR	NR	Excision	NR	NR	Plantar	NR	1 year	No recurrence
Karaburum et al. <sup>9</sup>	1998	F	24	R and L	No	Pain and mass in lateral region of both ankles	4 months	Osteochondroma in peroneal tubercle	NR	NR	Excision	Root block	NR	Longitudinal, parallel to plantar, 2 cm inferior to fibula	No	NR	
Sánchez-Mariscal Díaz et al. <sup>10</sup>	2001	M	69	R	No	Distal peroneal tendonitis	2 years	Osteochondroma in peroneal tubercle, peroneus longus tenosynovitis	NR	NR	Excision, tenosynovectomy	NR	Curvilinear, posterior to lateral malleolus	No	3 years	Asymptomatic	
Akmar et al. <sup>11</sup>	2004	M	21	L	No	Pain and mass (5 cm) in the plantar-lateral region of the ankle	10 months	Osteochondroma in the inferior region of the calcaneum	NR	NR	Excision	Root block	Lateral	Longitudinal, parallel to plantar, 2 cm inferior to fibula	No	NR	NR
Nogier et al. <sup>12</sup>	2006	M	36	R	No	Heel pain	9 years	Inferolateral osteochondroma of the calcaneum	60 x 55 x 30	12	Excision	NR	NR	NR	Infection ( <i>E. coli</i> ; required 2 other surgeries)	4 years	No recurrence
Uğurlu et al. <sup>13</sup>	2007	F	23	R and L	Repetitive bilateral ankle sprains	Bilateral stenosing tendonitis of peroneal tendons	5 weeks	Osteochondroma in peroneal tubercle, peroneus longus tenosynovitis, os peroneum	NR	NR	Excision, tenosynovectomy	Root block	NR	Over the prominence	NR	Asymptomatic	
Blitz and Lopez <sup>14</sup>	2008	F	40	L	No	Heel pain and mass	6 months	Osteochondroma in the inferior medial tubercle	80 x 42 x 21	2-18	Biopsy and excision	NR	NR	Medial	NR	3.5 years	No recurrence. Permanent work disability

(Continues.)

Table. (Cont.)

Author	Year	Gender	Age (years)	Side	Trauma/History	Preoperative symptoms	Duration of preoperative symptoms	Intraoperative findings	Tumor size (mm)	Cartilage thickness (mm)	Surgery	Anesthesia	Position	Approach	Complications	Follow-up	Outcomes (clinical and radiographic)
Koploy et al. <sup>15</sup>	2009	F	25	R	No	Pain and mass in the posteromedial region of the ankle	1 year	Posteromedial osteochondroma of the calcaneum	18 x 12	6	Excision	NR	NR	NR	Reoperated 6 months later due to painful regrowth	9 months	No recurrence
Jung et al. <sup>16</sup>	2011	F	22	R		Haglund's deformity and distal Achilles tendinopathy	12 years	Osteochondroma on the dorsum of the calcaneal protuberance	32 x 23 x 21	Excision, bursectomy, Achilles reinsertion	General	NR	NR	Medial to the Achilles tendon	No	18 months	No recurrence
Kumar et al. <sup>17</sup>	2016	M	58	R	No	Pain and mass in the posterior region of the ankle	years	Posteromedial osteochondroma of the calcaneum	31 x 17	4	Excision, bursectomy	NR	NR	Posterolateral	No	6 months	No recurrence
Okoh et al. <sup>18</sup>	2019	M	41	L	No	Plantar fasciitis and gastrocnemius contracture	years	Plantar, posterolateral calcaneus osteochondroma	11 x 9	NR	Excision	NR	NR	Posterolateral	No	9 months	No recurrence
Raviraj et al. <sup>19</sup>	2021	F	56	R and L	No	Haglund's deformity	6 months	Osteochondroma on the dorsum of the calcaneal protuberance	NR	NR	Excision, bursectomy	NR	NR	Posterolateral	No	2 years	No recurrence
Bilekci <sup>20</sup>	2022	M	50	R	No	Tearing of both peroneal tendons		Osteochondroma in peroneal tubercle	NR	NR	Excision, tubularization		Lateral	Over the prominence	No	1 year	No recurrence
Avramidis et al. <sup>21</sup>	2023	M	27	R	No	Pain and mass in the plantar-lateral region of the ankle	7 years	Osteochondroma in the lateral process of the calcaneal tuberosity	45 x 30 x 25	NR	Excision	NR	Lateral	Lateral	No	3 years	No recurrence
Trebino Molteni et al.	2023	M	22	L	No	Pain and mass in the plantar-lateral region of the ankle	3 years	Osteochondroma in the inferior region of the calcaneum	70 x 50 x 30	NR	Excision	Root block	Lateral	Lateral	No	1 year	No recurrence

M = male; F = female; NR = not reported; R = right; L = left.

Conflict of interest: The authors declare no conflicts of interest.

L. I. Rodríguez ORCID ID: <https://orcid.org/0009-0006-3990-579X>

P. Paitampoma Álvarez ORCID ID: <https://orcid.org/0009-0007-8068-1721>

F. Campoverde Imbaquingo ORCID ID: <https://orcid.org/0009-0004-5146-6801X>

## REFERENCES

1. Unni KK, Carrie Y. *Dahlin's bone tumors*, 6<sup>th</sup> ed. Philadelphia, PA: Lippincott, Williams and Wilkins; 2010:9-14.
2. Porter DE, Simpson AH. The neoplastic pathogenesis of solitary and multiple osteochondromas. *J Pathol* 1999;188:119-25. [https://doi.org/10.1002/\(SICI\)1096-9896\(199906\)188:2<119::AID-PATH321>3.0.CO;2-N](https://doi.org/10.1002/(SICI)1096-9896(199906)188:2<119::AID-PATH321>3.0.CO;2-N)
3. Walling AK. Tumores óseos y de partes blandas. In: *Coughlin, Mann, Saltzman. Pie y tobillo*, 8<sup>a</sup>. ed. Madrid: Marbán; 2021, vol. 2, p. 606-31.
4. Parizzia W, Saá FL. Tumores músculo esqueléticos de pierna, tobillo y pie. In: Amor RT. *Pierna, Tobillo y Pie*. Buenos Aires: Atlante; 2009:474-508.
5. Woertler K, Lindner N, Gosheger G, Brinkschmidt C, Heindel W. Osteochondroma: MR imaging of tumor-related complications. *Eur Radiol* 2000;10:832-40. <https://doi.org/10.1007/s003300051014>
6. Techner LM, DeCarlo RL. Peroneal tubercle osteochondroma. *J Foot Surg* 1992;31(3):234-7. PMID: 1619220
7. Martin MA, Garcia L, Hijazi H, Sanchez MM. Osteochondroma of the peroneal tubercle. A report of two cases. *Int Orthop* 1995;19(6):405-7. <https://doi.org/10.1007/BF00178360>
8. Sella EJ, Chrostowski JH. Calcaneal osteochondromas. *Orthopedics* 1995;18(6):573-5. <https://doi.org/10.3928/0147-7447-19950601-12>
9. Karakurum G, Oznur A, Atilla B. Bilateral peroneal tubercle osteochondroma of the calcaneus: case report. *Foot Ankle Int* 1998;19(4):259-61. <https://doi.org/10.1177/107110079801900415>
10. Sánchez-Mariscal Díaz F, Pizones Arce J, Martín Guinea JE, Nieva Navarro F. Peroneal tenosynovitis caused by peroneal tubercle osteochondroma. *Foot Ankle Surg* 2001;7(4):249-52. <https://doi.org/10.1046/j.1460-9584.2001.00276.x>
11. Akmaz I, Arpacioğlu MO, Pehlivan O, Solakoglu C, Kiral A, Kaplan H, et al. Calcaneal osteochondroma. *J Am Podiatr Med Assoc* 2004;94(4):409-11. <https://doi.org/10.7547/0940409>
12. Nogier A, De Pinieux G, Hottya G, Anract P. Case reports: Enlargement of a calcaneal osteochondroma after skeletal maturity. *Clin Orthop Relat Res* 2006;447:260-6. <https://doi.org/10.1097/01.blo.0000203474.96549.80>
13. Uğurlu M, Demirkale I, Bozkurt M, Doğan M, Tosun N. Osteochondroma: an unusual cause of stenosing tenosynovitis of peroneus longus tendon associated with osperoneum. *Turk Med J* 2007;1:96-9. Disponible en: <https://acikerisim.aybu.edu.tr:8443/server/api/core/bitstreams/fb79eefa-1718-42cf-babb-9e9c8dd2237f/content>. [Consulta: 25 de noviembre, 2023]
14. Blitz NM, Lopez KT. Giant solitary osteochondroma of the inferior medial calcaneal tubercle: a case report and review of the literature. *J Foot Ankle Surg* 2008;47(3):206-12. <https://doi.org/10.1053/j.jfas.2007.12.006>
15. Koplay M, Toker S, Sahin L, Kilincoglu V. A calcaneal osteochondroma with recurrence in a skeletally mature patient: a case report. *Cases J* 2009;23(2):7013. <https://doi.org/10.4076/1757-1627-2-7013>
16. Jung HG, Carag JA, Park JY, Bae EJ, Lim SD, Kim HS. Osteochondroma of the calcaneus presenting as Haglund's deformity. *Foot Ankle Surg* 2011;17(2):e20-2. <https://doi.org/10.1016/j.fas.2010.08.007>
17. Kumar R, Anjana, Kundan M. Retrocalcaneal bursitis due to rare calcaneal osteochondroma in adult male: Excision and outcome. *J Orthop Case Rep* 2016;6(2):16-9. <https://doi.org/10.13107/jocr.2250-0685.410>
18. Koh D, Goh Y, Yeo N. Calcaneal osteochondroma masquerading as plantar fasciitis: An approach to plantar heel pain - A case report and literature review. *World J Orthop* 2019;10(9):339-47. <https://doi.org/10.5312/wjo.v10.i9.339>
19. Raviraj A, Samson M, Sugumar K, Maalepati V. Unusual adult bilateral osteochondroma of the talus with severe peroneal tendinitis and adult bilateral osteochondroma of calcaneum with Haglund syndrome – A report of two cases and review of literature. *J Adv Medicine Medical Res* 2021;33(10):84-9. <https://doi.org/10.9734/jammr/2021/v33i1030912>

20. Bilekli AB. Stenosing peroneal tubercle osteochondroma associated with calcaneal bone marrow edema and tear of both peroneal tendons: A rare case report and review of the literature. *Foot Ankle Surg Tech Rep Cases* 2022;2(1):100109. <https://doi.org/10.1016/j.fastrc.2021.100109>
21. Avramidis K, Katounis C, Krikis P, Skoufogiannis P. A solitary, large calcaneal osteochondroma growing extensively after skeletal maturity: A case report and review of the literature. *Cureus* 2023;15(7):e42570. <https://doi.org/10.7759/cureus.42570>
22. Garrison RC, Unni KK, McLeod RA, Pritchard DJ, Dahlin DC. Chondrosarcoma arising in osteochondroma. *Cancer* 1982;49(9):1890-7. [https://doi.org/10.1002/1097-0142\(19820501\)49:9<1890::aid-cnrcr2820490923>3.0.co;2-u](https://doi.org/10.1002/1097-0142(19820501)49:9<1890::aid-cnrcr2820490923>3.0.co;2-u)
23. Willms R, Hartwig CH, Böhm P, Sell S. Malignant transformation of a multiple cartilaginous exostosis -- a case report. *Int Orthop* 1997;21(2):133-6. <https://doi.org/10.1007/s002640050136>
24. Malik R, Kapoor N, Malik R. Transformation of solitary osteochondromacalcaneum to chondrosarcoma--a case report. *Indian J Pathol Microbiol* 2004;47(1):42-3. PMID: 15471126