

Case Resolution

Florencio P. Segura,^{*,**,#} María Paz Lucero Zudaire,^{**} Roberto C. Quiroz,[#] Paul Briggen,[#] Silvana V. Preisz,[#] Joaquín A. Álvarez Castillo[#]

^{*}Private Orthopedics and Traumatology Center, Córdoba, Argentina.

^{**}Instituto Modelo de Cardiología, Córdoba, Argentina

[#]Orthopedics and Traumatology Service, Nuevo Hospital San Roque, Córdoba, Argentina.

Case presentation on page 93.

DIAGNOSIS: Fracture of the lateral process of the talus.

DISCUSSION

Given the suspicion of a talar bone injury with joint involvement and the possibility of surgical resolution, it was decided to order a multiplanar computed tomography of the ankle and rearfoot with 3D reconstruction. The images show a fracture of the lateral process of the talus with fragmentation and displacement of the subtalar joint (Figure 4).

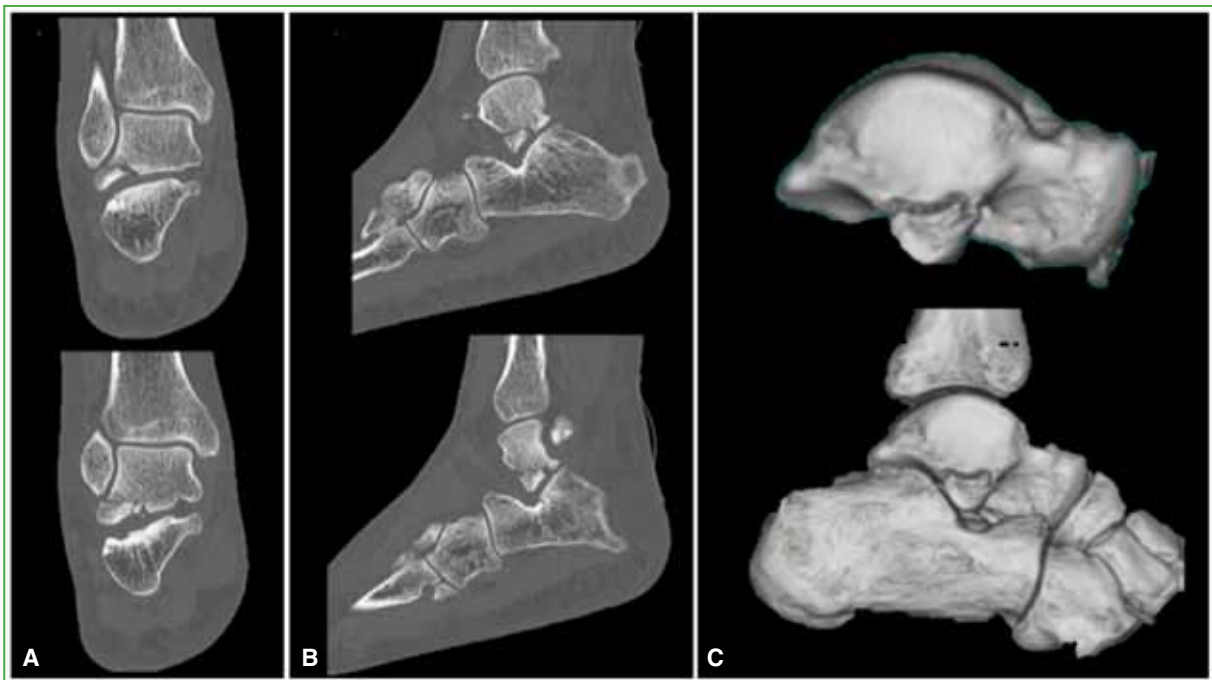


Figure 4. Computed tomography of the ankle and rearfoot requested in the outpatient consultation, 20 days after the accident. **A.** Coronal slices. **B.** Sagittal slices. **C.** 3D reconstruction.

Dr. FLORENCIO P. SEGURA • fpablosegura@gmail.com  <https://orcid.org/0000-0002-2376-4834>

How to cite this article: Segura FP, Lucero Zudaire MP, Quiroz RC, Briggen P, Preisz SV, Álvarez Castillo JA. Postgraduate Orthopedic Instruction – Imaging. Case Resolution. *Rev Asoc Argent Ortop Traumatol* 2024;89(2):210-213. <https://doi.org/10.15417/issn.1852-7434.2024.89.2.1926>

The patient underwent open reduction and lateral internal fixation 30 days after the initial trauma (Figure 5).

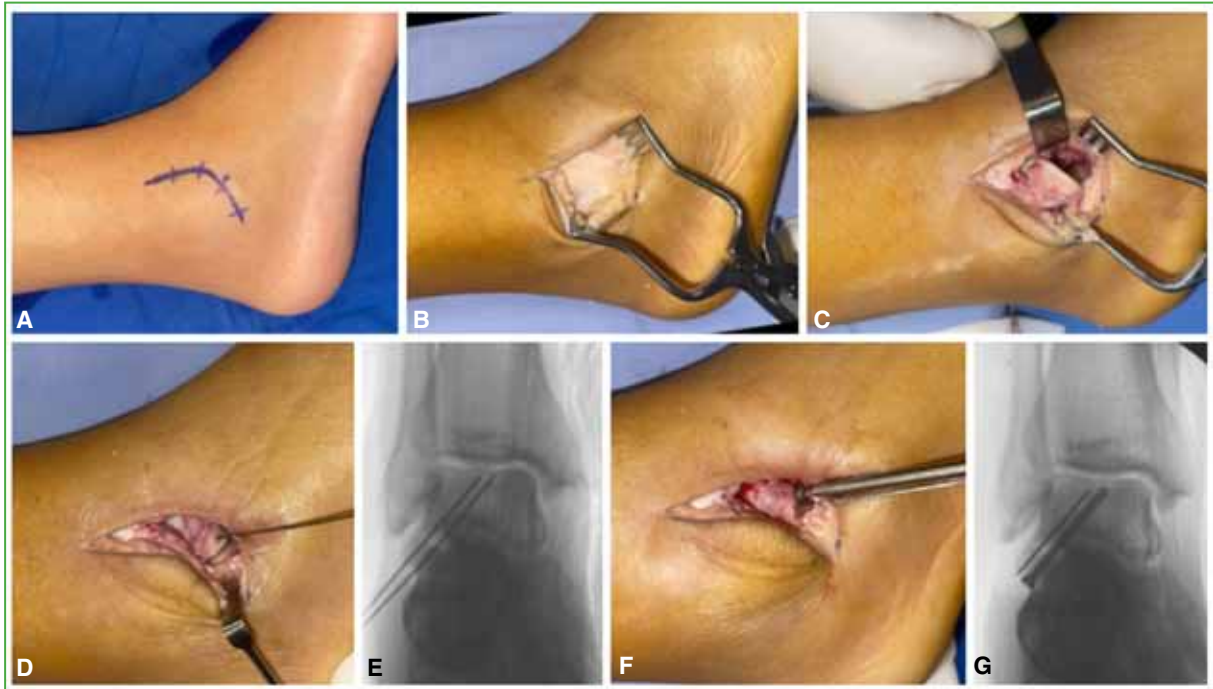


Figure 5. Open reduction and internal fixation by curved lateral approach. **A.** Cutaneous incision. **B.** Superficial dissection and visualization of the anterolateral ankle capsule. **C.** Deep dissection and individualization of the displaced fracture fragment. **D and E.** Transient reduction and fixation. **F and G.** Definitive fixation with 3.5 mm cannulated screw and anti-rotation pin.

Fractures of the lateral process of the talus are very rare, accounting for no more than 0.4-1% of all traumatic ankle injuries.¹⁻³ The mechanism of injury is axial loading or a forward fall on a foot in forced dorsiflexion and external rotation or eversion. It occurs in the context of certain sporting activities where this situation is common, such as snowboarding (“snowboarder’s fracture”).⁴

They may go undetected in 15-60% of cases because they have a clinical appearance similar to acute lateral instability and are difficult to see on radiographs in conventional projections.^{4,5} Delayed treatment or an inadequate therapeutic decision can lead to considerable morbidity given the eminently articular nature of these injuries: the lateral talar process presents a double sliding surface for the distal fibula and for the lateral end of the posterior facet of the calcaneus and is the site of insertion of ligamentous structures involved in ankle and hindfoot stability.¹⁻⁵ Computed tomography is the study of choice for correct interpretation and decision making. Multiplanar slices every 1-2 mm are especially useful to define fragment size, degree of displacement, presence of comminution and percentage of subtalar or tibiotalar joint involvement.^{5,6}

The therapeutic decision is based on the anatomical morphology of the injury, which is taken into account by all classifications attempting to standardize its treatment.⁷⁻⁹ The one suggested by Macklin Vadell recognizes four main types: type 1, a small chip or avulsion fracture of the anteroinferior portion of the process; type 2, a simple fracture, with an intermediate or large fragment, no displacement, or displacement >2 mm; type 3, a comminuted fracture with an intermediate or large fragment that might be articular, metaphyseal, or affect the entire process; and type 4, a variant associated with subtalar instability or subtalar subluxation (Figure 6).¹⁰

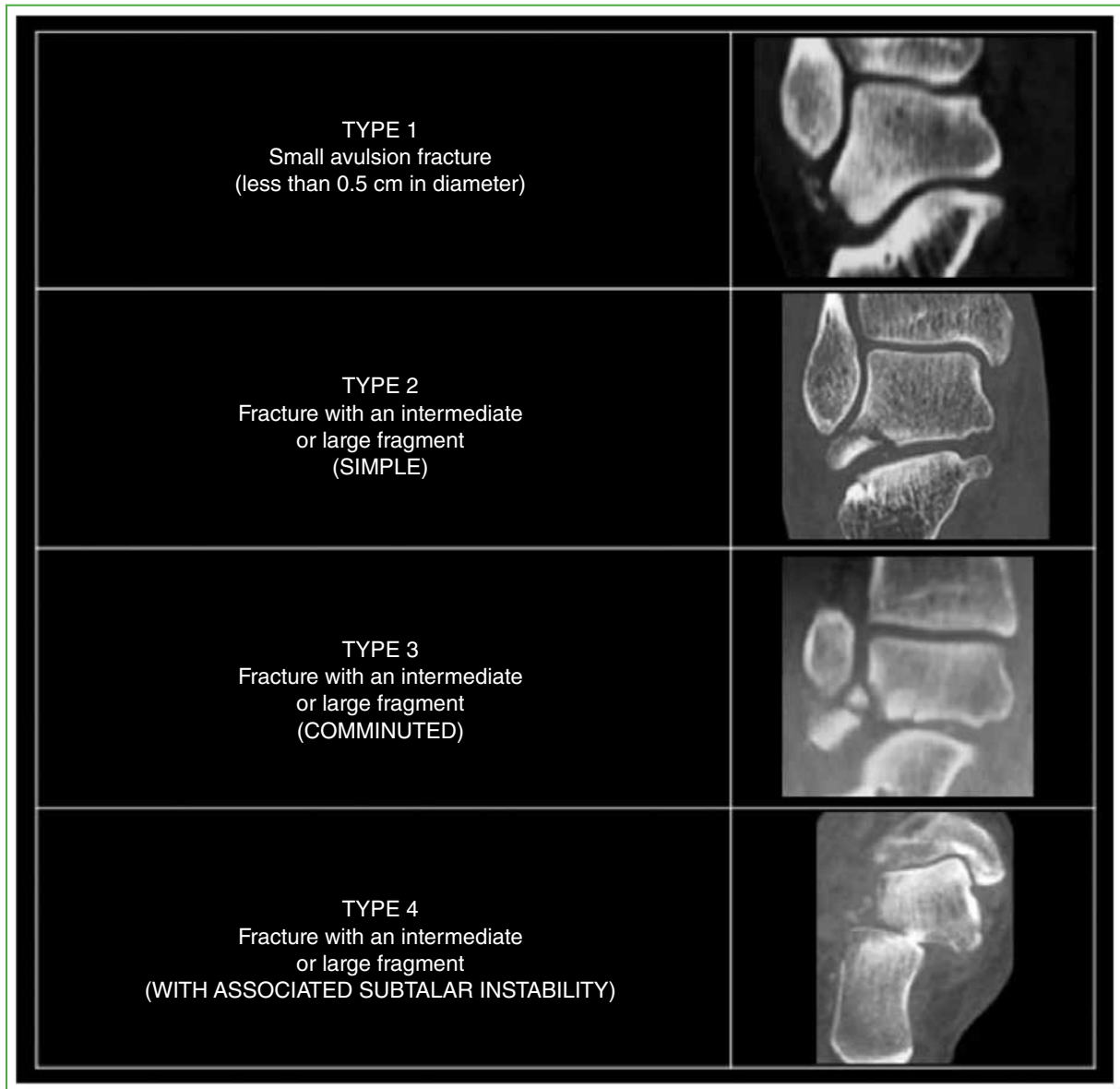


Figure 6. Macklin Vadell's morphological classification of fractures of the lateral process of the talus (2005).

Conservative management is reserved only for small avulsions without joint involvement or for simple fractures without displacement, with a protocol that includes non-weight bearing for at least six weeks, and active and passive range of motion exercises from the third week onwards. In all other situations, and because displacement is usually the rule, treatment is surgical.⁷⁻¹⁰ Arthroscopic access through two ventral and dorsal anterolateral portals may be an option for both resection and debridement of small intra-articular injuries, and for fixation of intermediate or large fragments with minimal initial displacement.⁷ Open surgery is the preferred technique for larger displaced injuries through a transverse Ollier access or a lateral longitudinal access slightly curved inwards toward the cuboid, as in the case presented. Single-line patterns can be fixed only with screws, since there is a uniform surface of bone contact between the main fragment and the fracture bed. The minimum size of a potentially 'fixable' fragment corresponds to three times the diameter of the screw head to be placed, which can be 2.0, 2.4 or 2.7 mm ('rule of thirds'). It is advisable to associate a second fixation with an anti-rotation

pin whenever possible. Patterns with intercalary fragmentation require plate augmentation, usually with a 2.0 mm T-plate for support.⁸⁻¹⁰ If residual subtalar instability is detected, temporary transarticular stabilization with two pins, maintained for at least 21 days, is suggested.¹⁰ Finally, in large injuries with complete fragmentation, excision of the process can be considered if the resected volume does not exceed 5-10 cm³,¹¹ or primary subtalar arthrodesis if the involvement is greater.⁷⁻⁹

Early diagnosis and early treatment achieve the best long-term outcomes, because they allow a rapid normalization of subtalar function. When treated promptly with open reduction and internal fixation, 80% of patients with large simple fractures regain their pre-trauma level of function. The most frequently reported complication is osteoarthritis with subtalar stiffness, which may be associated with any subtype of injury even with appropriate treatment and requires subtalar arthrodesis as a salvage procedure.⁶⁻¹⁰

CONCLUSIONS

Fractures of the lateral process of the talus are rare but potentially disabling injuries if the diagnosis is missed and treatment is delayed. Surgical fixation of simple, large fragment patterns is the most recommended therapeutic approach and should be performed as soon as possible to avoid sequelae.

M. P. Lucero Zudaire ORCID ID: <https://orcid.org/0009-0009-8632-480X>
 R. C. Quiroz ORCID ID: <https://orcid.org/0009-0003-8569-8021>
 P. Brigggen ORCID ID: <https://orcid.org/0000-0002-9016-1718>

S. V Preisz ORCID ID: <https://orcid.org/0000-0002-1438-0900>
 J. A. Álvarez Castillo ORCID ID: <https://orcid.org/0009-0007-5445-3143>

REFERENCES

1. Rammelt S, Zwipp H. Talar neck and body fractures. *Injury* 2009;40(2):120-35. <https://doi.org/10.1016/j.injury.2008.01.021>
2. Sanders R. Fractures and fracture-dislocations of the talus. En: Saltzman CL, Anderson RB, Coughlin MJ. *Mann's surgery of the foot and ankle*. 9th ed. Philadelphia: Elsevier; 2014.
3. Zwipp H. Severe foot trauma in combination with talar injuries. En: Tscherne H, Schatzker J (eds). *Major fractures of the pilon, the talus and the calcaneus*. New York: Springer-Verlag; 1993, p. 123-35.
4. Kirkpatrick DP, Hunter RE, Janes PC, Mastrangelo J, Nicholas RA. The snowboarder's foot and ankle. *Am J Sports Med* 1998;26:271-7. <https://doi.org/10.1177/03635465980260021901>
5. Ebraheim NA, Skie MC, Podeszwa DA, Jackson WT. Evaluation of process fractures of the talus using computed tomography. *J Orthop Trauma* 1994;8:332-7. <https://doi.org/10.1097/00005131-199408000-00010>
6. Rammelt S, Bartoniček J, Park KH. Traumatic injury to the subtalar joint. *Foot Ankle Clin* 2018;23:353-74. <https://doi.org/10.1016/j.fcl.2018.04.004>
7. Boack D-H, Manegold S. Peripheral talar fractures. *Injury* 2004;35:S-B23-S-B35. <https://doi.org/10.1016/j.injury.2004.07.019>
8. Valderrabano V, Perren T, Ryf C, Rillmann P, Hintermann B. Snowboarder's talus fracture treatment outcome of 20 cases after 3.5 years. *Am J Sport Med* 2005;33:871-80. <https://doi.org/10.1177/0363546504271001>
9. Tinner C, Sommer C. Fractures of the lateral process of the talus. *Foot Ankle Clin* 2018;23(3):375-95. <https://doi.org/10.1016/j.fcl.2018.04.009>
10. Macklin Vadell A. Fracturas del proceso lateral del astrágalo. *Rev Asoc Argent Ortop Traumatol* 2005;70(2):175-9. Disponible en: https://aaot.org.ar/wp-content/uploads/2021/10/Rev-Asoc-Argent-Ortop-Traumatol-2005-70-2-175-9_Macklin.pdf
11. Sands A, White C, Blankstein M, Zderic I, Wahl D, Ernst M, et al. Assessment of ankle and hindfoot stability and joint pressures using a human cadaveric model of a large lateral talar process excision: a biomechanical study. *Medicine (Baltimore)* 2015;94(11):e606. <https://doi.org/10.1097/MD.0000000000000606>