

Arthroscopic “Glider” Interposition with Associated Stabilization in Distal Radioulnar Joint Osteoarthritis: Preliminary Results

Juan Matías Sala, Aldo D. Ledesma

Servicio de Cirugía de Mano Patagónica (CIMAP), OTI, Clínica del Valle S.R.L., Comodoro Rivadavia, Chubut, Argentina.

ABSTRACT

Objectives: To describe an arthroscopic technique for treating distal radioulnar joint (DRUJ) osteoarthritis involving the interposition of a woven polyester cylinder and the palmaris longus, and to present preliminary results. **Materials and Methods:** A retrospective analysis was conducted on five patients with DRUJ osteoarthritis, classified clinically and confirmed by arthroscopy. The patients underwent treatment using the author’s “glider” interposition technique. The average follow-up period was 11 months. Outcomes were evaluated using range of motion (ROM), grip strength, the Mayo Wrist Score, and the Disabilities of the Arm, Shoulder, and Hand (DASH) questionnaire. **Results:** The study included five patients (four with secondary osteoarthritis and one with primary osteoarthritis). Pain and grip strength showed improvement. The average ROM post-surgery was: 75° pronation, 70° supination, 80° extension, and 70° flexion. According to the Mayo Wrist Score, results were excellent in 83% of cases and good in 17%, with no poor outcomes. The average DASH score improved from 56 preoperatively to 20 postoperatively. Grip strength compared to the contralateral side averaged 70%. **Conclusions:** The arthroscopic glider interposition technique shows promise as a minimally invasive alternative to current joint salvage procedures. This approach preserves soft tissue structures, is reproducible, stabilizes the DRUJ, and prevents proximal radioulnar impingement.

Keywords: osteoarthritis; arthroscopy; interposition; distal radioulnar joint.

Level of Evidence: IV

Interposición ósea en parapente para la artrosis radiocubital distal: resultados preliminares

RESUMEN

Objetivos: Presentar una técnica artroscópica para el tratamiento de la artrosis radiocubital distal que consiste en la interposición de un cilindro de poliéster tejido y de palmar menor, y los resultados preliminares. **Materiales y Métodos:** Se analizaron, en forma retrospectiva, los resultados de esta técnica en 5 pacientes con artrosis radiocubital distal clasificada clínicamente y por vía artroscópica, en un seguimiento promedio de 11 meses. Todas las lesiones se repararon por vía artroscópica mediante una técnica de autor denominada técnica de interposición en parapente. Se evaluaron los rangos de movilidad, la fuerza de agarre con el *Mayo Wrist Score* y el cuestionario DASH. **Resultados:** Se incluyó a 5 pacientes (4 artrosis secundarias y 1 artrosis primaria). Los resultados de las pruebas de dolor y fuerza mejoraron. El rango de movilidad promedio fue: 75° de pronación, 70° de supinación, 80° de extensión y 70° de flexión. Los resultados, según el *Mayo Wrist Score*, fueron excelentes (83%) y buenos (17%), no hubo resultados malos. El puntaje promedio del cuestionario DASH era 56 antes de la cirugía y 20 en el posoperatorio. El promedio de la fuerza comparativa contralateral fue del 70%. **Conclusiones:** La técnica de interposición artroscópica en parapente propone ser una alternativa a las técnicas de salvataje articular utilizadas hoy, ya que es mínimamente invasiva, conserva estructuras de las partes blandas, es reproducible, permite la estabilización de la articulación radiocubital distal y evita el pinzamiento radiocubital proximal.

Palabras clave: Artrosis; artroscopia; interposición; articulación radiocubital distal.

Nivel de Evidencia: IV

Received on June 5th, 2024. Accepted after evaluation on October 9th, 2024 • Dr. JUAN MATÍAS SALA • salajuanmatias@icloud.com  <https://orcid.org/0000-0001-5542-5004>

How to cite this article: Sala JM, Ledesma AD. Arthroscopic “Glider” Interposition with Associated Stabilization in Distal Radioulnar Joint Osteoarthritis: Preliminary Results. *Rev Asoc Asoc Argent Ortop Traumatol* 2024;89(6):606-625. <https://doi.org/10.15417/issn.1852-7434.2024.89.6.1983>

INTRODUCTION

The distal radioulnar joint (DRUJ) is a trochlear joint involved in forearm pronation and is essential for daily activities requiring elbow flexion with the forearm in intermediate pronation. In this position, the ulnar head acts as a fulcrum against the radial sigmoid notch, absorbing loads from the hand, carpus, and forearm.¹⁻⁸ The DRUJ exhibits four anatomical variants of the radial sigmoid notch in the transverse plane: flat, C-shaped, S-shaped, and ski slope. Additionally, it presents three anatomical variants in the horizontal plane: parallel, oblique, and reverse oblique.^{1,2,9}

The ulnar head has two distinct angulations contributing to the DRUJ: the distal articular angle and the radial angle.⁹ The oblique surface of the radius and the increased inclination of the radial angle are associated with the DRUJ, providing a larger contact area with higher pressure.⁹⁻¹¹

Osteoarthritis of the DRUJ can be primary or secondary to poorly consolidated radius fractures, tumors, Madelung’s deformity, rheumatoid arthritis, infections, or fracture-dislocations. Atzei developed an arthroscopic classification of triangular fibrocartilage complex (TFCC) lesions, which includes DRUJ osteoarthritis as the most severe stage (Table).

Table. Atzei classification for ulnar injuries of the triangular fibrocartilage complex based on their stability, ligamentous structures, potential for repair, and suggested treatment.

Type	DRU Inestability	Appearance of the distal TFCC	Appearance of the proximal TFCC	TFCC repair potential	Appearance of the DRU cartilage	Suggested treatment
1	Mild/No	Broken	Intact	Good	Good	Capsule repair
2	Moderate/ Severe	Broken	Broken	Good	Good	Foveal repair
3	Moderate/ Severe	Intacto	Broken	Good	Good	Foveal repair
4	Severe	Broken	Broken	Poor	Good	Graft reconstruction
5	Moderate/ Severe	Variable	Variable	Variable	Poor	Arthroplasty or salvage

DRUJ = distal radioulnar joint; TFCC = triangular fibrocartilage complex.

Taken from: Sala M, Daroda S. Results of the Knotless Arthroscopic Foveal

Anchorage of the Triangular Fibrocartilage Complex in Atzei 2/3 Lesions. *Rev Asoc Argent Ortop Traumatol* 2021;86(5):581-594. <https://doi.org/10.15417/issn.1852-7434.2021.86.5.1374>

Osteoarthritis of the DRUJ leads to pain, loss of strength, and functional limitations that affect quality of life by restricting painful pronation. This condition may also coexist with ulnar impaction syndrome.^{1-5,12}

Historically, DRUJ osteoarthritis has been treated with resection or fusion of the distal ulna. These are ablative procedures that do not restore biomechanics but are widely accepted, albeit with variable outcomes. They relieve pain and improve mobility; however, radioulnar impingement is a common complication.¹⁻⁷ These procedures include the Darrach, Bowers, and Sauvé-Kapandji techniques, among others. While the Darrach and Sauvé-Kapandji procedures are effective in managing this condition, they often result in a proximal ulnar stump with dynamic instability.¹⁻⁴

Partial and total arthroplasties of the DRUJ are not available in Argentina and thus are not a viable option in our country.

The advancement of arthroscopy has enabled many open procedures to be performed arthroscopically, minimizing soft tissue damage. Building on the concepts of Bowers’ open technique, we developed an arthroscopic DRUJ interposition technique combined with ulnar osteotomy and joint stabilization. This involves an oblique subtraction osteotomy of the ulna and anchoring a woven polyester cylinder in the radial sigmoid notch, with a palmaris longus tendon graft inside. The woven polyester cylinder, an inert prosthetic material commonly used in vascular surgery, generates minimal fibrosis, allowing adequate joint mobility without adhesions or excessive fibrosis.

We termed this technique “glider interposition” because the insertion of the graft into the joint, along with the sutures, resembles a paragliding wing with its harness. This technique facilitates DRUJ interposition with joint stabilization through the tendon graft.

The objective of this study was to evaluate the preliminary outcomes of the glider arthroscopic interposition technique for managing DRUJ osteoarthritis, focusing on achieving pain-free mobility and joint stability.

MATERIALS AND METHODS

A retrospective study was conducted to analyze surgical outcomes in five consecutive adult patients with DRUJ osteoarthritis who underwent surgery between June 1, 2021, and June 1, 2023.

Inclusion criteria were: Age >18 years, no history of prior osteoarthritis surgery or wrist arthroscopy, pain consistent with DRUJ osteoarthritis that limited daily activities, sports, or work, positive Nakamura and screwdriver tests, Atzei stage 5 lesions confirmed by radiography, MRI, and arthroscopy, and a minimum postoperative follow-up of 6 months.

The exclusion criterion was history of DRUJ surgery or wrist arthroscopy.

The study included five patients (three women and two men; four dominant hands and one non-dominant hand) with DRUJ osteoarthritis.

Wrist range of motion in flexion, extension, ulnar deviation, and radial deviation was measured using a standard PVS hand goniometer, while grip strength was assessed with a standard hydraulic dynamometer (Baseline-Orthowell®).²

Subjective evaluation included the Visual Analog Scale (VAS) for pain, the Mayo Clinic Wrist Score (MWS), and the Disabilities of the Arm, Shoulder, and Hand (DASH) questionnaire.^{1,2}

The treatment protocol was as follows: During the first consultation for wrist pain attributed to DRUJ osteoarthritis, anamnesis was performed to identify the initial trauma or degenerative mechanism, followed by a clinical examination. The Nakamura test and screwdriver test were performed, and an AP wrist radiograph was obtained (Figure 1).

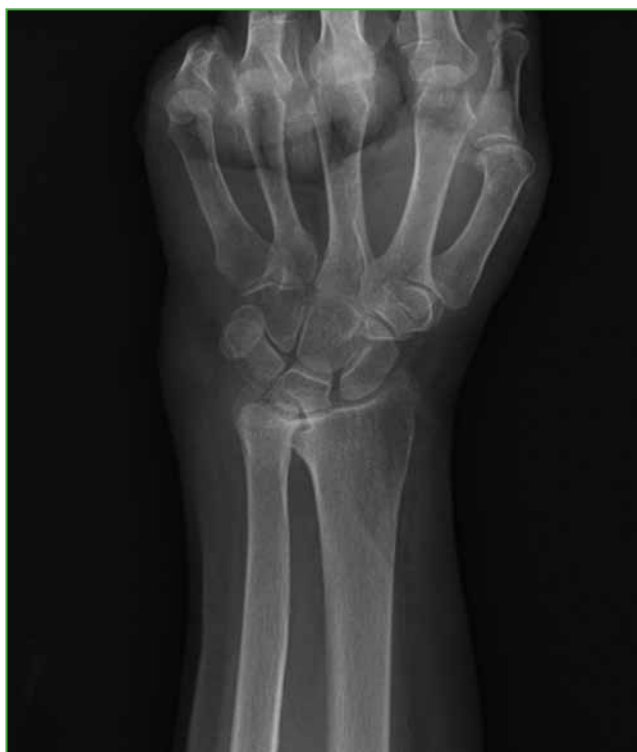

Figure 1. Wrist radiograph, AP view, showing distal radioulnar osteoarthritis.

The Nakamura test involves the patient resting their elbow on a desk while the examiner stabilizes the radius with one hand and performs volar and dorsal translations in pronation, supination, and neutral positions (Figure 2).¹⁰

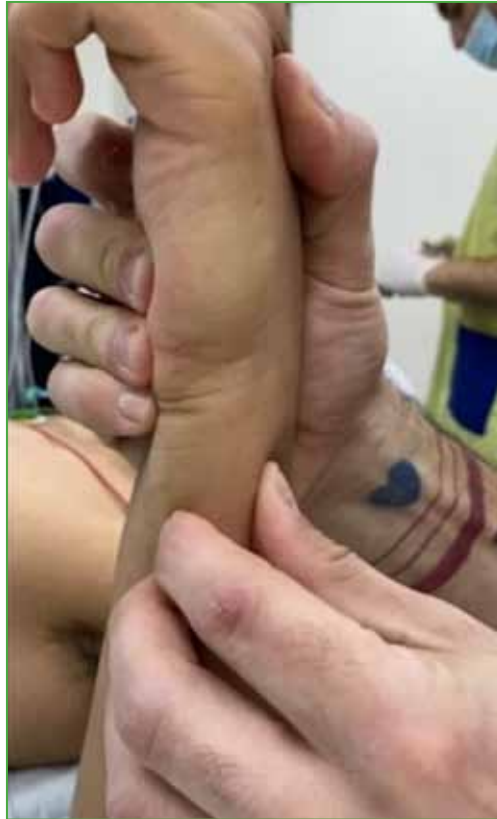

Figure 2. Nakamura maneuver.

The screwdriver test simulates a handshake, during which the examiner passively moves the forearm into full pronation and supination. A positive test elicits pain or a mechanical block that halts the movement (Figure 3).¹⁰ If these tests were positive, an MRI was performed to assess TFCC soft tissue integrity.



Figure 3. Screwdriver test in pronation and supination.

Patients with confirmed diagnoses underwent glider interposition arthroplasty via arthroscopy.

Surgical Technique

The glider interposition technique with DRUJ stabilization involves performing an oblique subtraction osteotomy of the ulnar head in its articular segment and reaming the sigmoid cavity of the radius. This is combined with the radial anchoring of a woven polyester cylinder containing a palmaris longus graft. The palmaris longus graft is intended to extend into the distal ulna to enhance DRUJ stability (Figure 4).

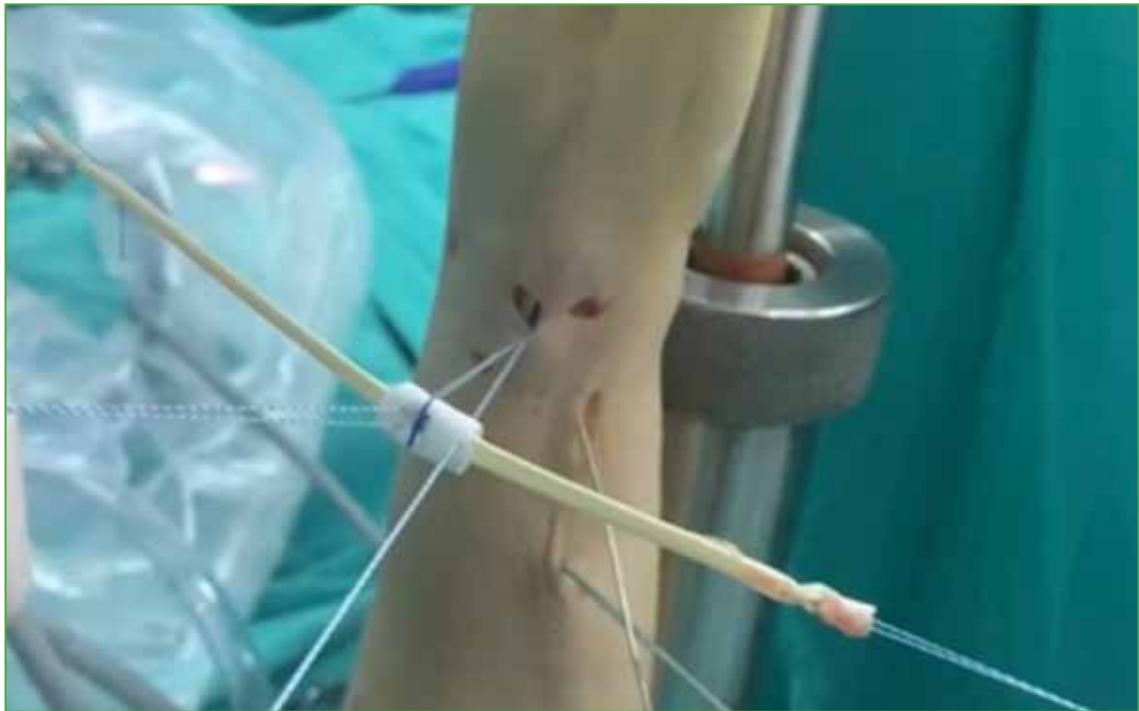

Figure 4. Woven polyester cylinder with the palmaris longus sutured at its ends, inside the cylinder.

The goal of this technique is to alleviate DRUJ friction pain associated with increased joint mobility by promoting interpositional fibrosis between the radius and ulna while stabilizing the DRUJ.

Step-by-Step Surgical Technique

Plexus block anesthesia is administered, and an ischemia-preventive cuff is placed at 250 mmHg. Portals 3-4, 6R, and the distal dorsal portal distal to the DRUJ joint (dd-DRUJ) are used. For this technique, routine midcarpal portals are not utilized.

The radiocarpal joint is accessed via portal 3-4, with instrumentation through portal 6R. The TFCC is examined, revealing chronic lesions with ligament retractions. These remnants are excised.

Optics are positioned through the dd-DRUJ portal, and work is performed through portal 6R. The DRUJ joint is inspected, and pronosupination is performed to evaluate the congruency of the radius over the ulnar head. DRUJ osteoarthritis is confirmed at this stage (Figure 5, Scheme 1).

A 3 cm incision is made on the ulna, beginning 1.5 cm distal to the ulnar styloid for guidewire placement. The ulnar approach is carefully dissected to avoid injury to the ulnar sensory branch.

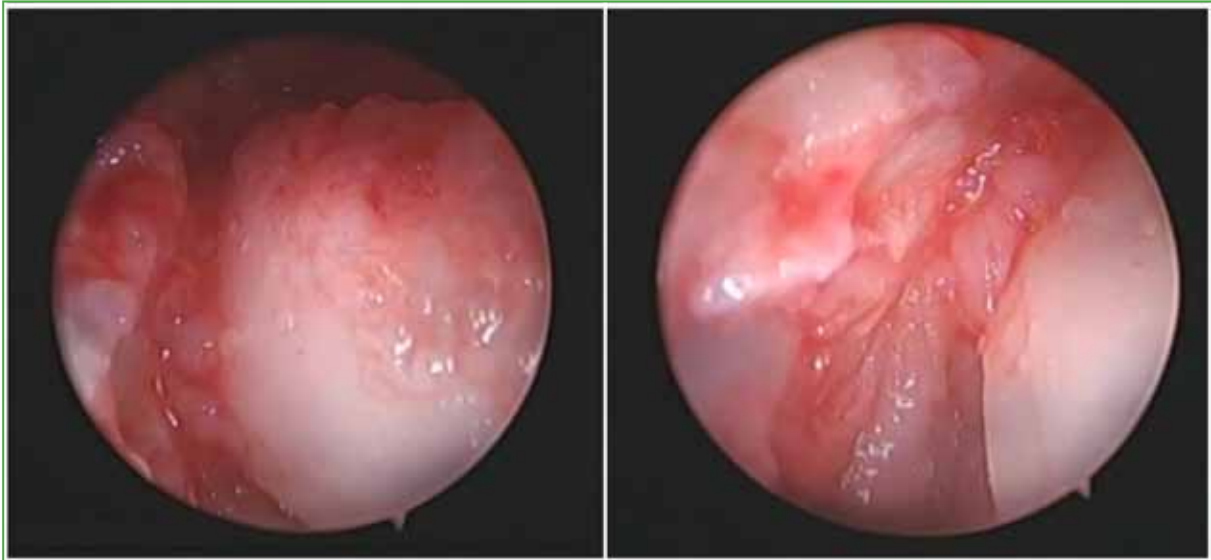
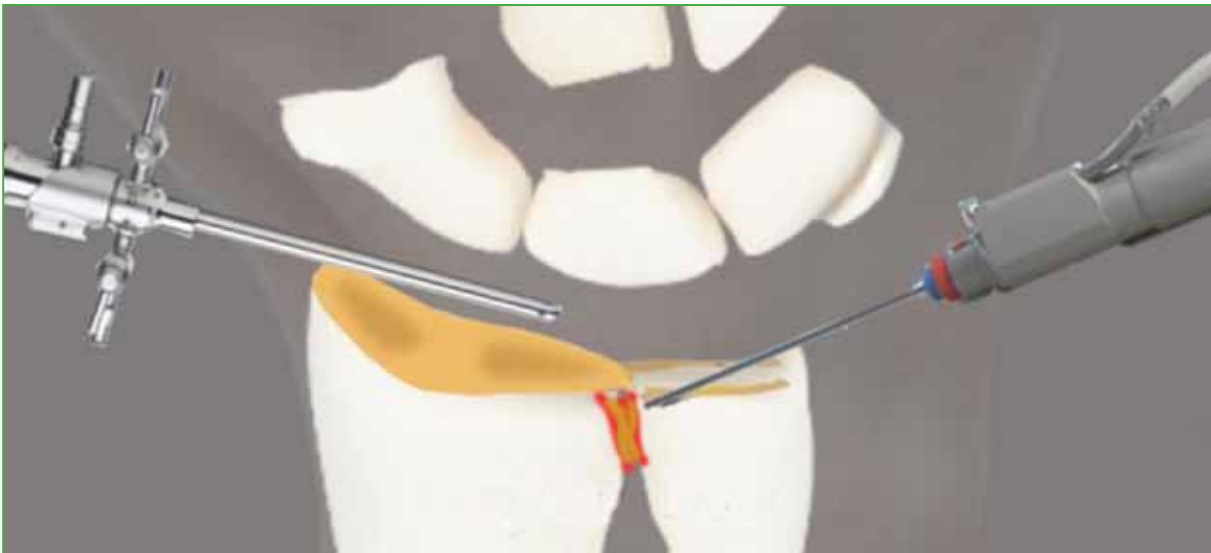

Figure 5. Radio-ulnar osteoarthritis is seen through the distal dorsal portal of the distal radioulnar joint.



Scheme 1. Debridement of ligamentous debris and the distal radioulnar joint.

The guide, which is located 1.5 cm from the ulnar styloid, has a 45° inclination with a hole to place the pin. It is necessary to respect the inclination and the distance to exit in the right area, in the ulna.

After proper positioning of the guide, a pin is inserted through it and the ulnar tunnel is created. The pin penetrates the ulna and exits through the metaphysis of the osteotomy performed.

The next step is the reaming of the bone tunnel with a 3.5 mm guide, which is performed using a drill stop so as not to damage the sensory branch of the ulnar nerve. It is reamed from the ulnar cortex toward the DRUJ joint. This ulnar hole is created for the passage of the ends of the palmaris longus (**Figure 6**).

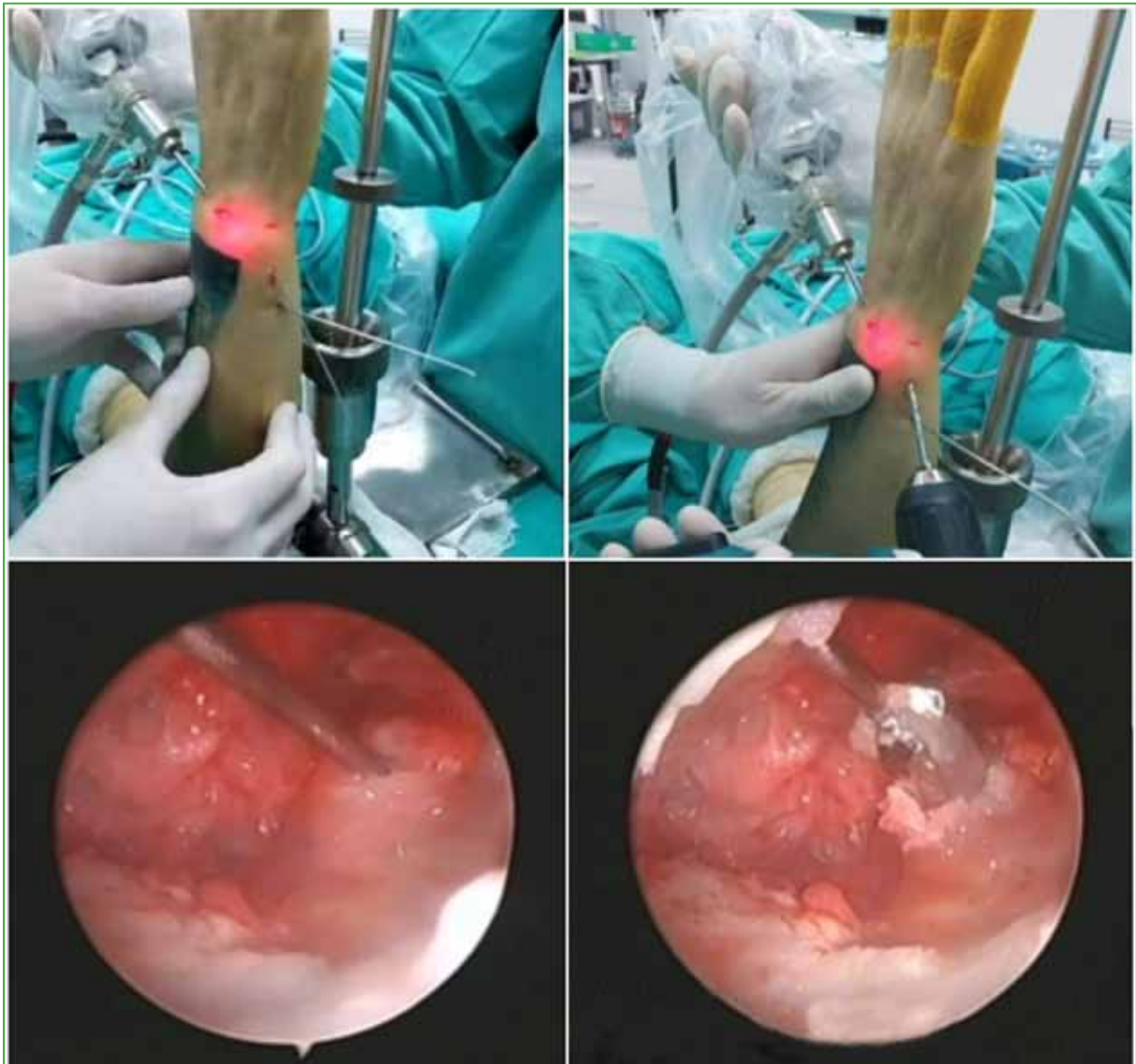


Figure 6. Placement of the pin and wick through the ulna.

The glider technique begins with a wide resection of the TFCC articular disc and an oblique subtraction osteotomy from ulnar to radial, and dorsal and volar of the ulnar head. It is performed with visualization through portal 3-4 and working through portal 6R.

The osteotomy will be approximately 4 to 6 mm according to demand, until an adequate space of the lesser sigmoid cavity is obtained (Figure 7, Scheme 2).

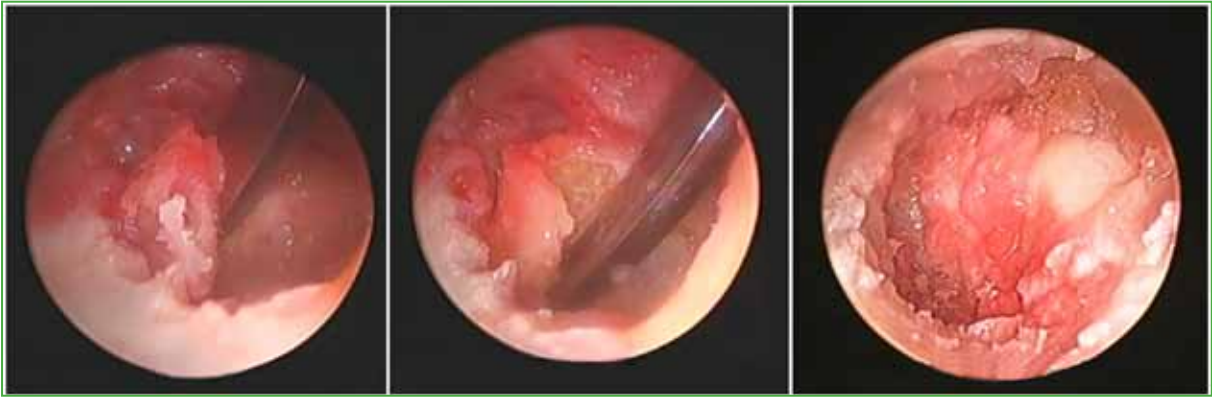
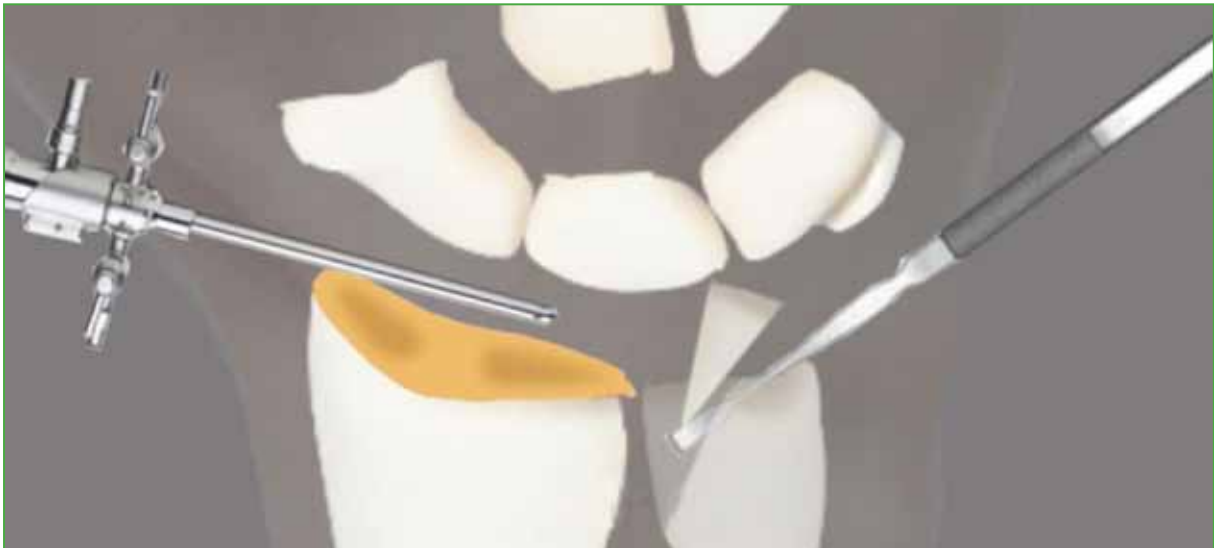
Figure 7. Images of ulnar osteotomy.



Scheme 2. Oblique osteotomy of the ulna.

It is important to verify that the ulna is not dislocated in chronic injuries; if there is a dislocation, before osteotomy, the ulna must be reduced over the sigmoid cavity of the radius and fixed to the reduced radius by means of a metaphyseal pin from ulna to radius.

After the osteotomy, the probe is placed through the dd-DRUJ portal and, through the 6R portal, a reamer is placed oriented to the lesser sigmoid cavity to regularize it with excision of the cartilage remnants leaving a C-shaped cavity to achieve greater containment (Figure 8). At this point, pronosupination is performed to evaluate the joint with the probe through the dd-DRUJ portal and confirm that the ulnar osteotomy is adequate. If bony debris remains, the ulna is reamed to regularize the surface. Intraoperative fluoroscopy confirms that osteotomy is correct (Scheme 3).

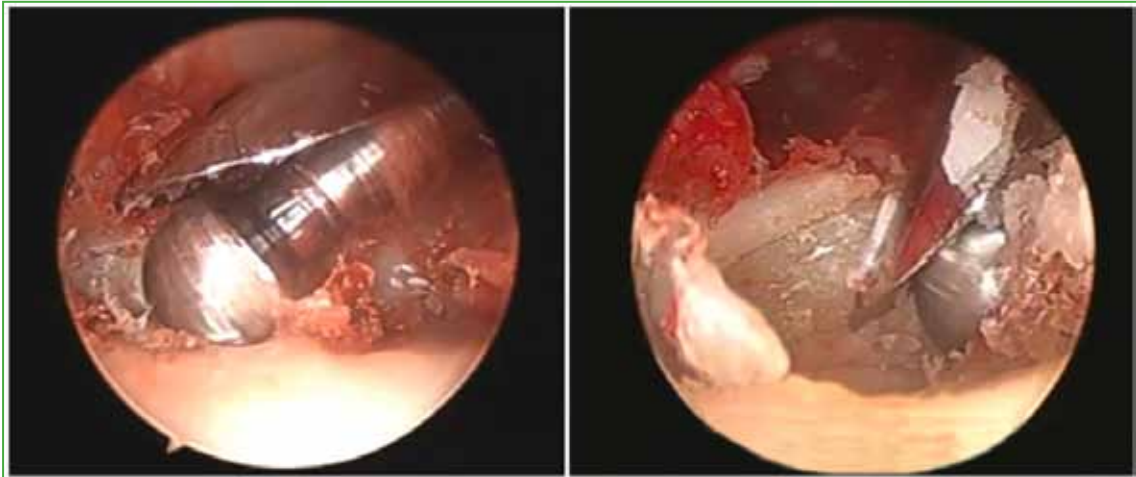
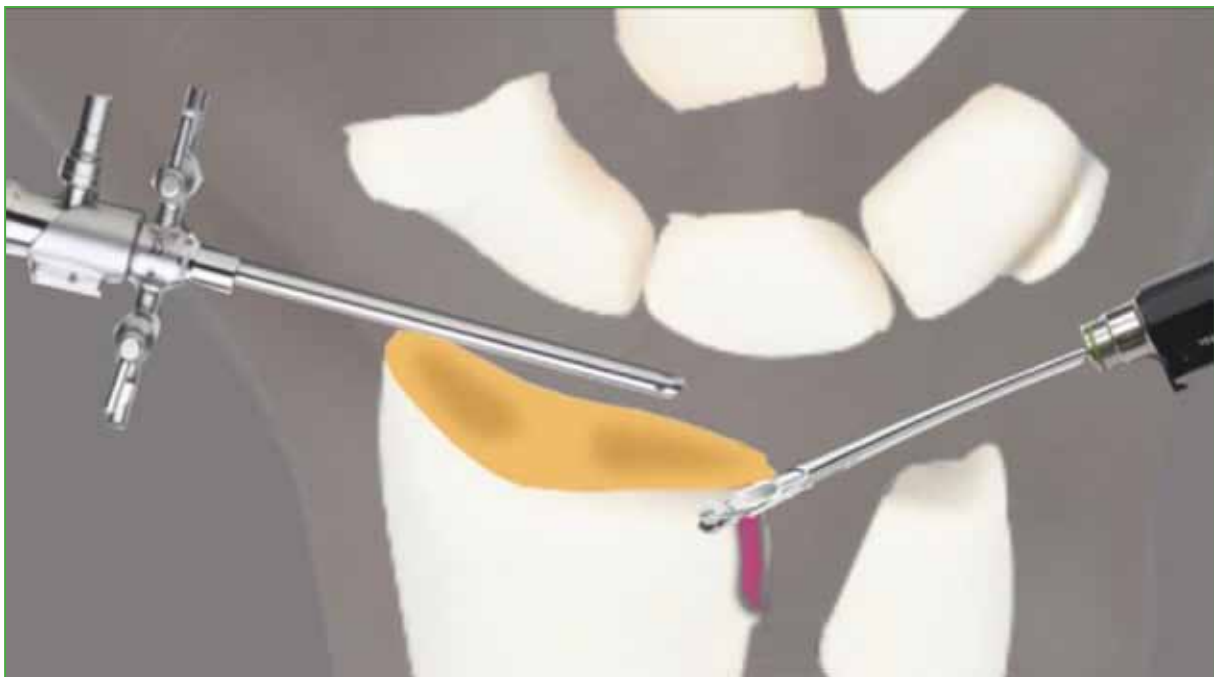

Figure 8. Ulnar reaming.



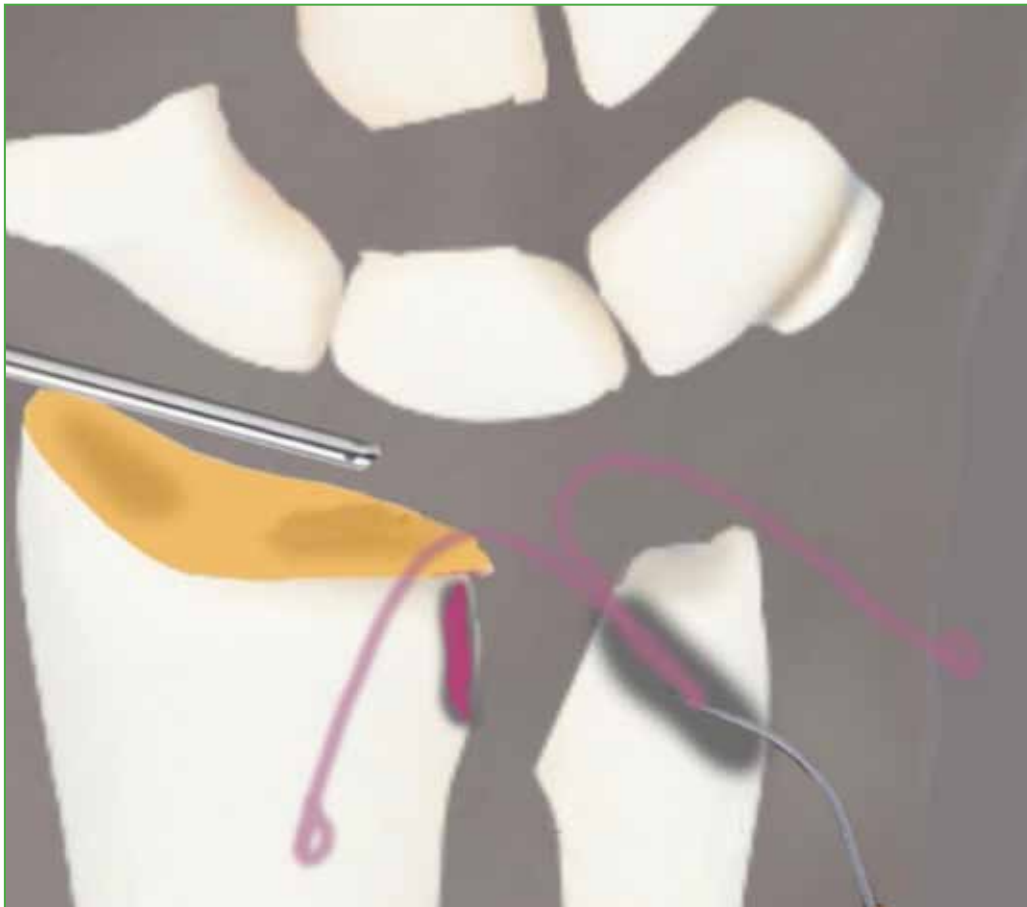
Scheme 3. Reaming of the lesser sigmoid cavity through the 6R portal.

Next, the width and length of the space created in the joint (**Figure 9**) are measured using the probe through portal 3-4 and through portal 6R. Having the measurements of the space created, the custom woven polyester cylinder is designed. In general, it is 4 mm long.

A 6U portal is created. Two suture retrievers are passed through the ulnar incision into the ulnar tunnel and out through the DRUJ joint. One suture is retrieved via portal 6R and the other via the 6U portal (**Scheme 4**).

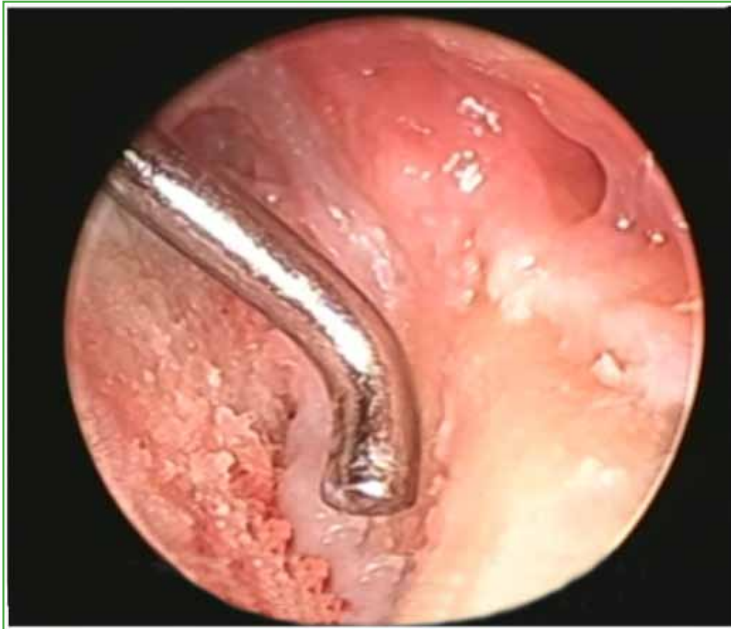

Figure 9. Space for graft placement.



Scheme 4. Suture retrievers passing through the ulnar tunnel.

Two harpoons are then placed toward the sigmoid cavity. These two harpoons are placed slightly obliquely at approximately 5 mm from the radiocarpal joint. We use harpoons with needles 2.2 mm wide and 8 mm long. One harpoon is introduced through portal 6R and the other through portal 6U to obtain a good angle of placement (Figure 10, Scheme 5).

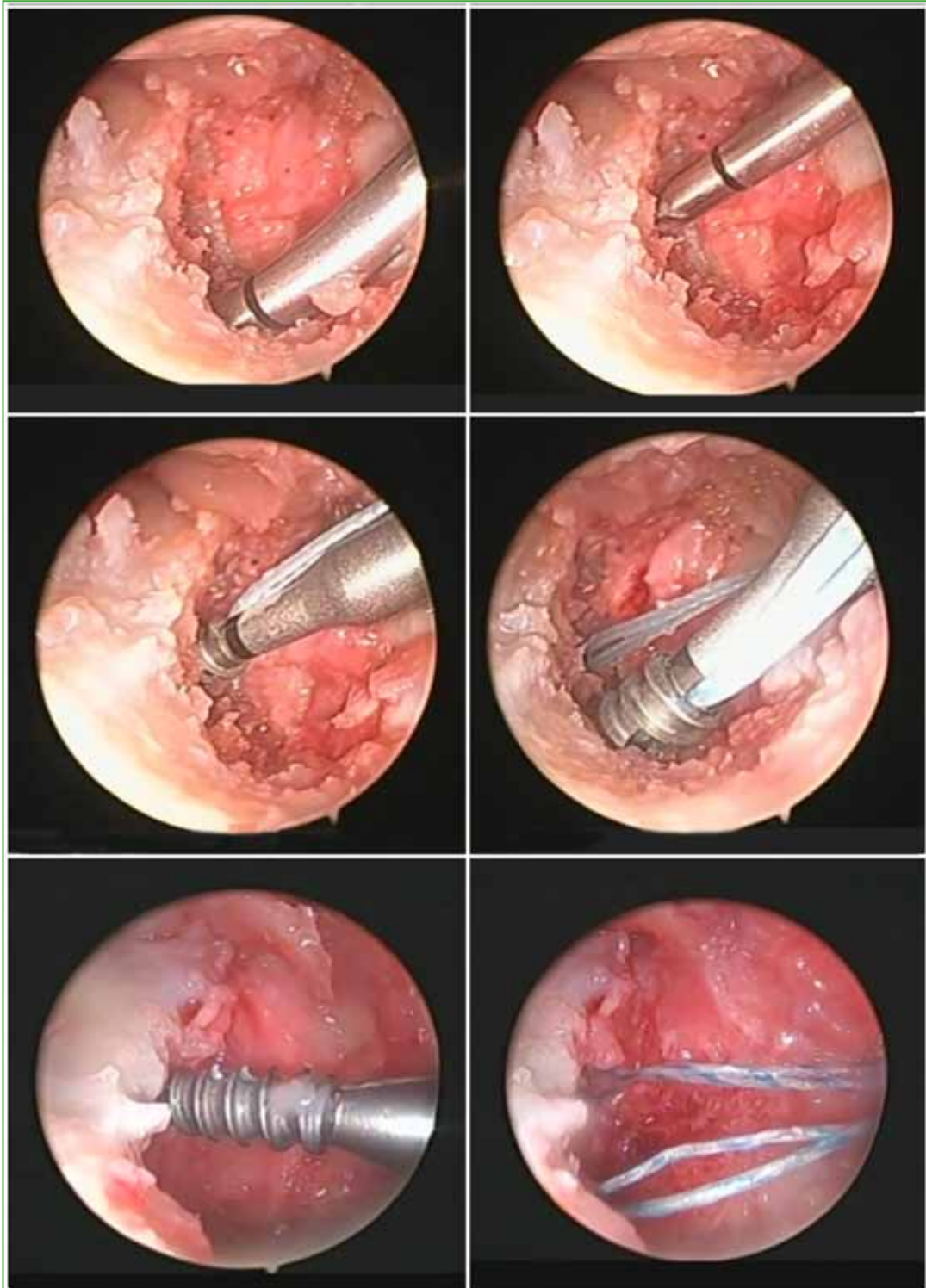
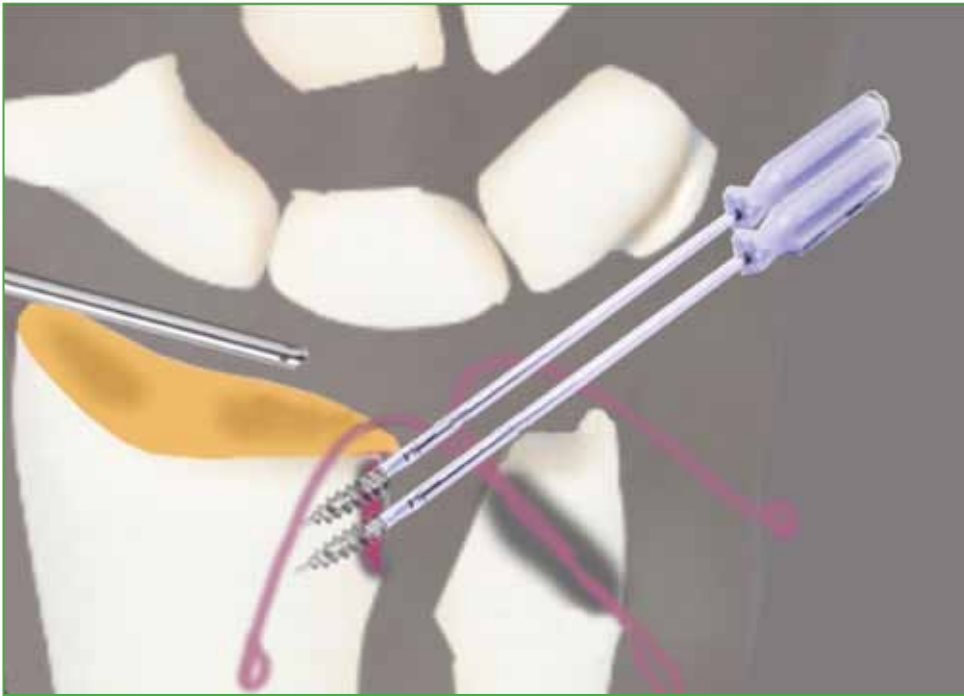

Figure 10. Placement of harpoons.



Scheme 5. Placement of two harpoons in the lesser sigmoid cavity.

The next step is the assembly of the woven polyester cylinder with the palmaris longus tendon inside. The tendon remains inside the cylinder with its ends even in length on both sides, with Krackow sutures at both ends of the tendon (**Figure 11**).

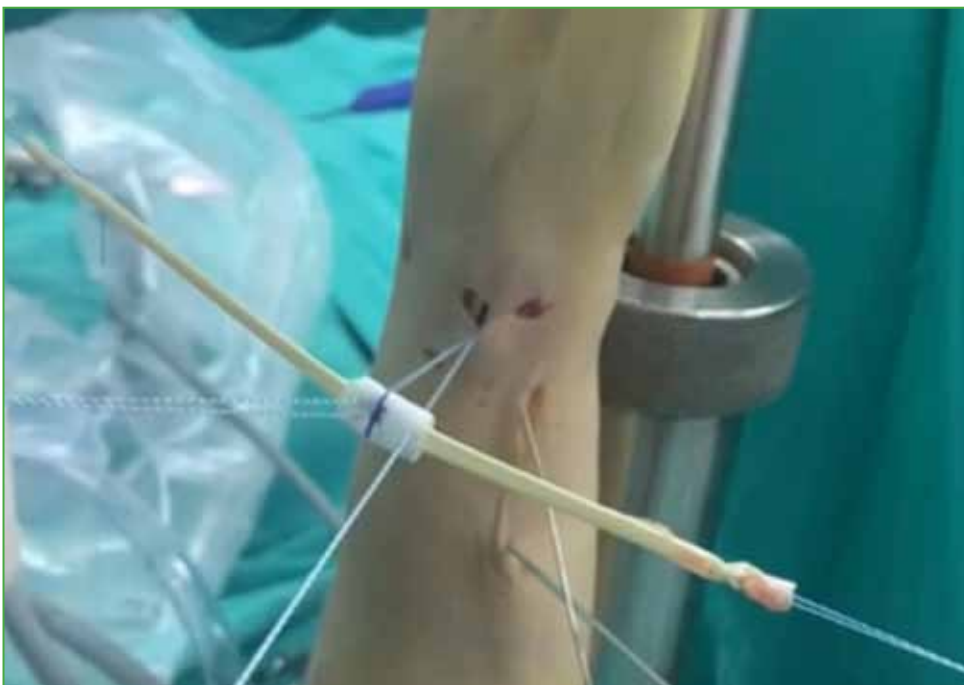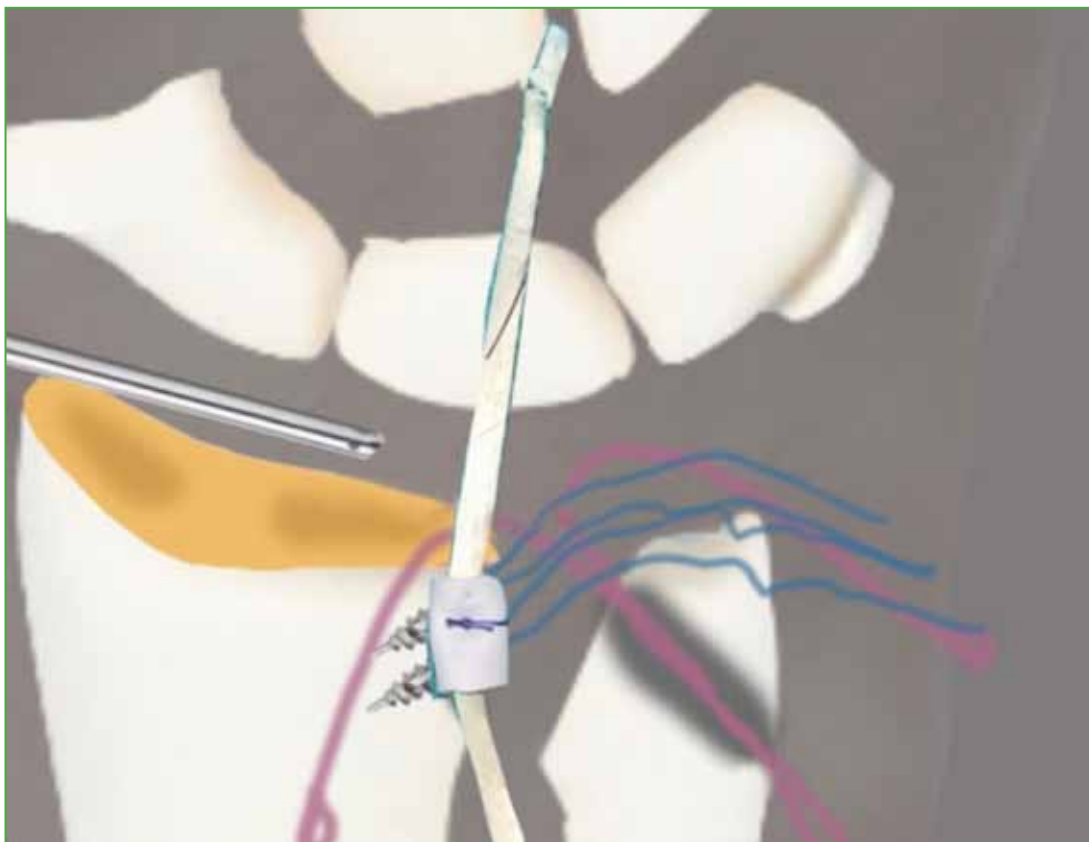


Figure 11. Graft prepared for entry through portal 6R.

Then the 4 threads of the harpoons are removed through the 6R portal and the threads of the harpoons are sutured to the cylinder and tendon graft. They are sutured taking part of the cylinder and the superior and inferior tendon in a symmetrical way. With the aid of the feeler, the cylinder and graft are entered through the 6R portal into the DRUJ joint and rested over the sigmoid cavity of the radius. At this point, the graft is held inside the joint with a feeler and the 4 wires are tensioned (Figure 12, Scheme 6).

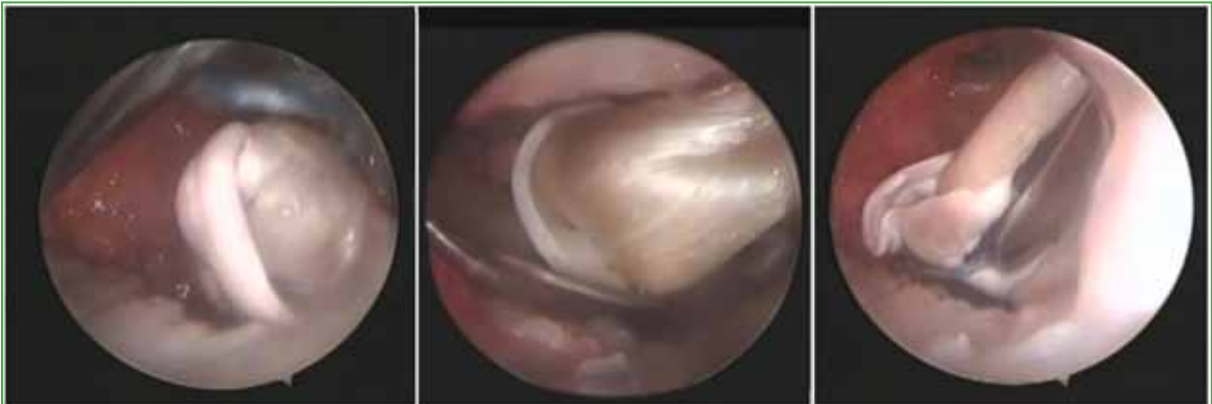

Figure 12. Woven polyester cylinder with the tendon inside the joint.

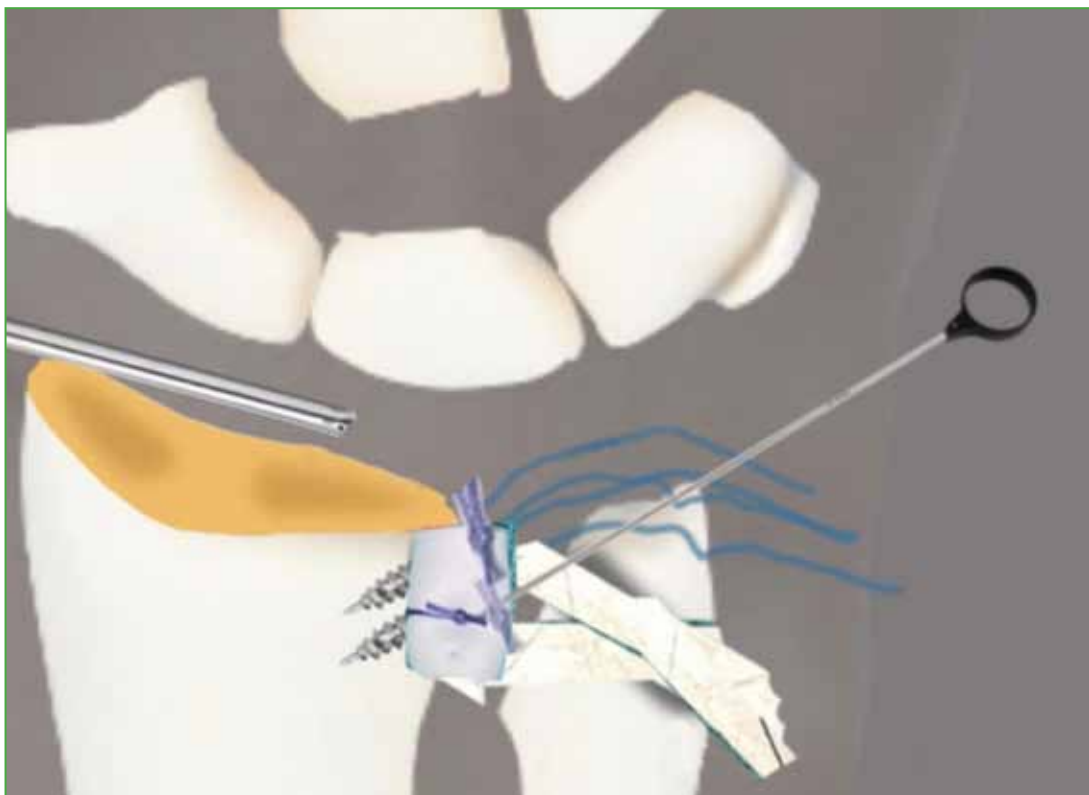


Scheme 6. Entry of the graft through portal 6R.

The volar strand is retrieved from the palmaris longus through the 6U portal and placed into the suture retriever. It is pulled from the proximal end of the suture retriever and the graft strand is passed through the ulnar tunnel. The procedure is repeated with the palmaris longus strand left through portal 6R. This is passed through the suture retriever outside the 6R portal and the retriever is pulled through the ulnar tunnel obtaining the passage of the dorsal strand of the graft. Two sliding knots are then tied with the harpoon sutures to fix the cylinder to the lesser sigmoid cavity. The threads are slid by means of a wrist knot through the 6R portal (Figure 13, Scheme 7).

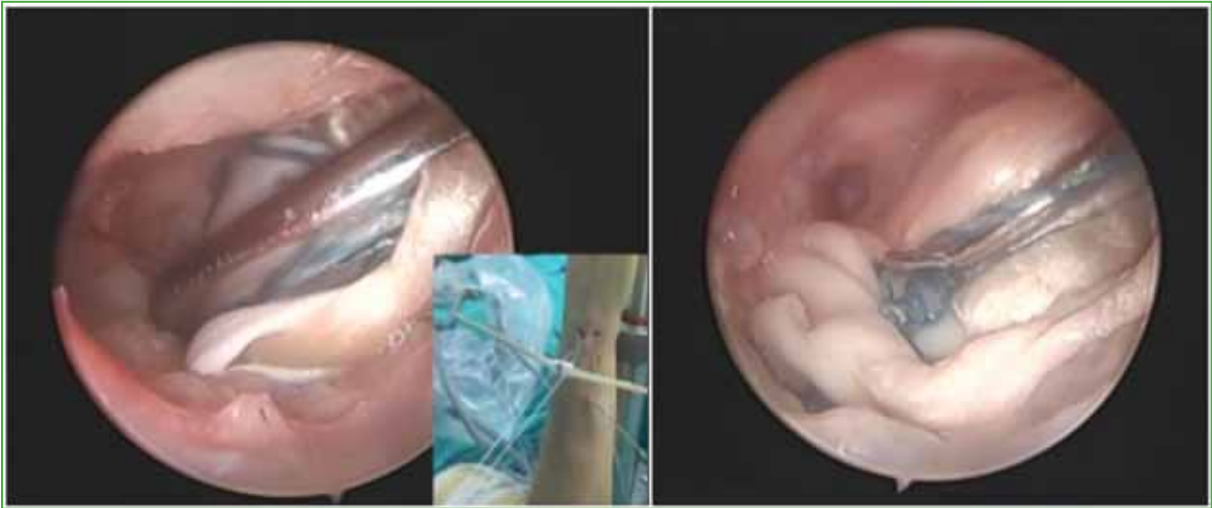

Figure 13. Fixation of the polyester cylinder by means of arthroscopic knots.



Scheme 7. Graft fixation by means of anchorage with sliding knots by 6R and 6U portals.

Correct placement and anchorage of the graft is verified by full pronosupination by traction with the proximal-to-distal probe to check the tension of the graft (Figure 14).

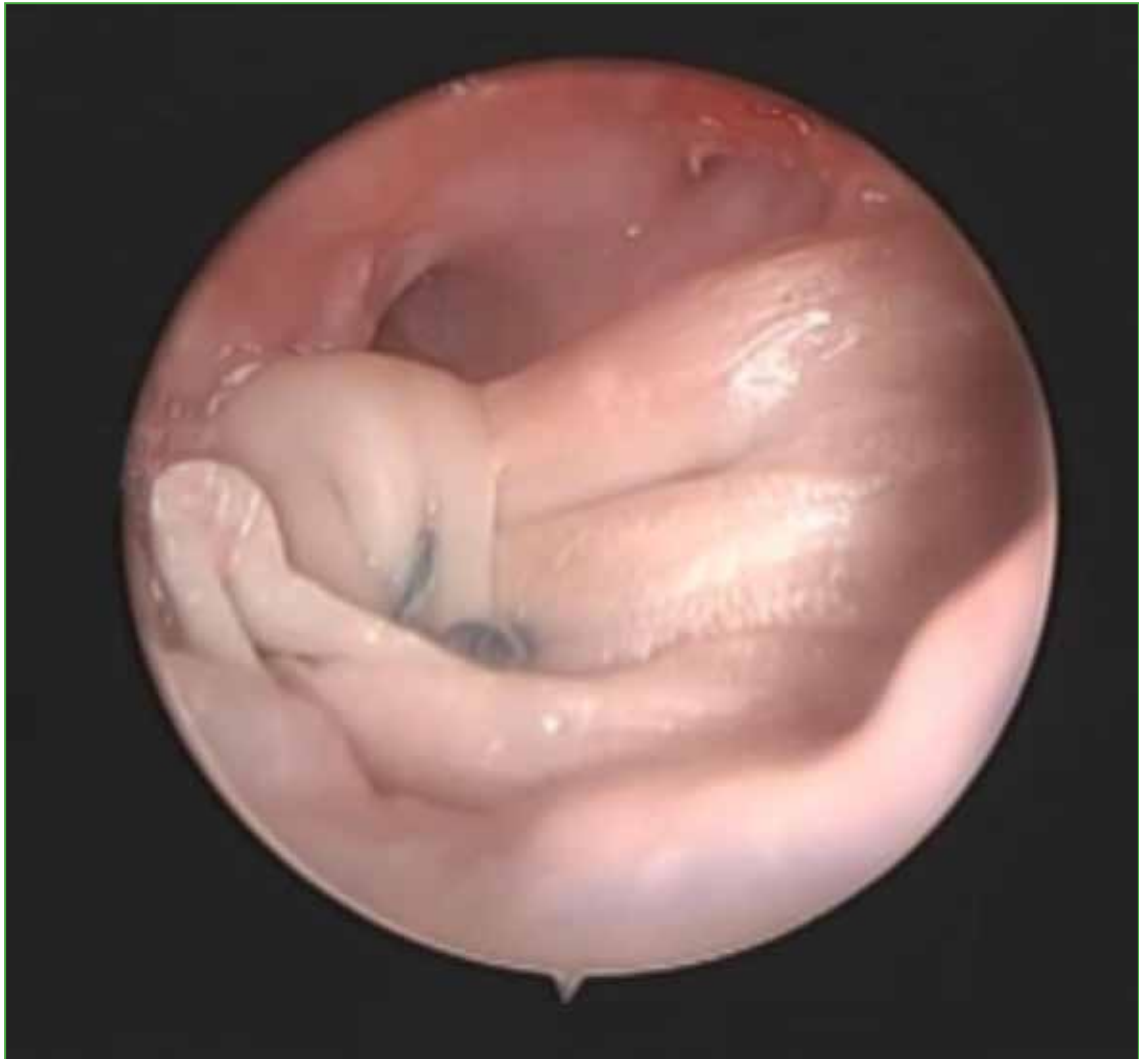
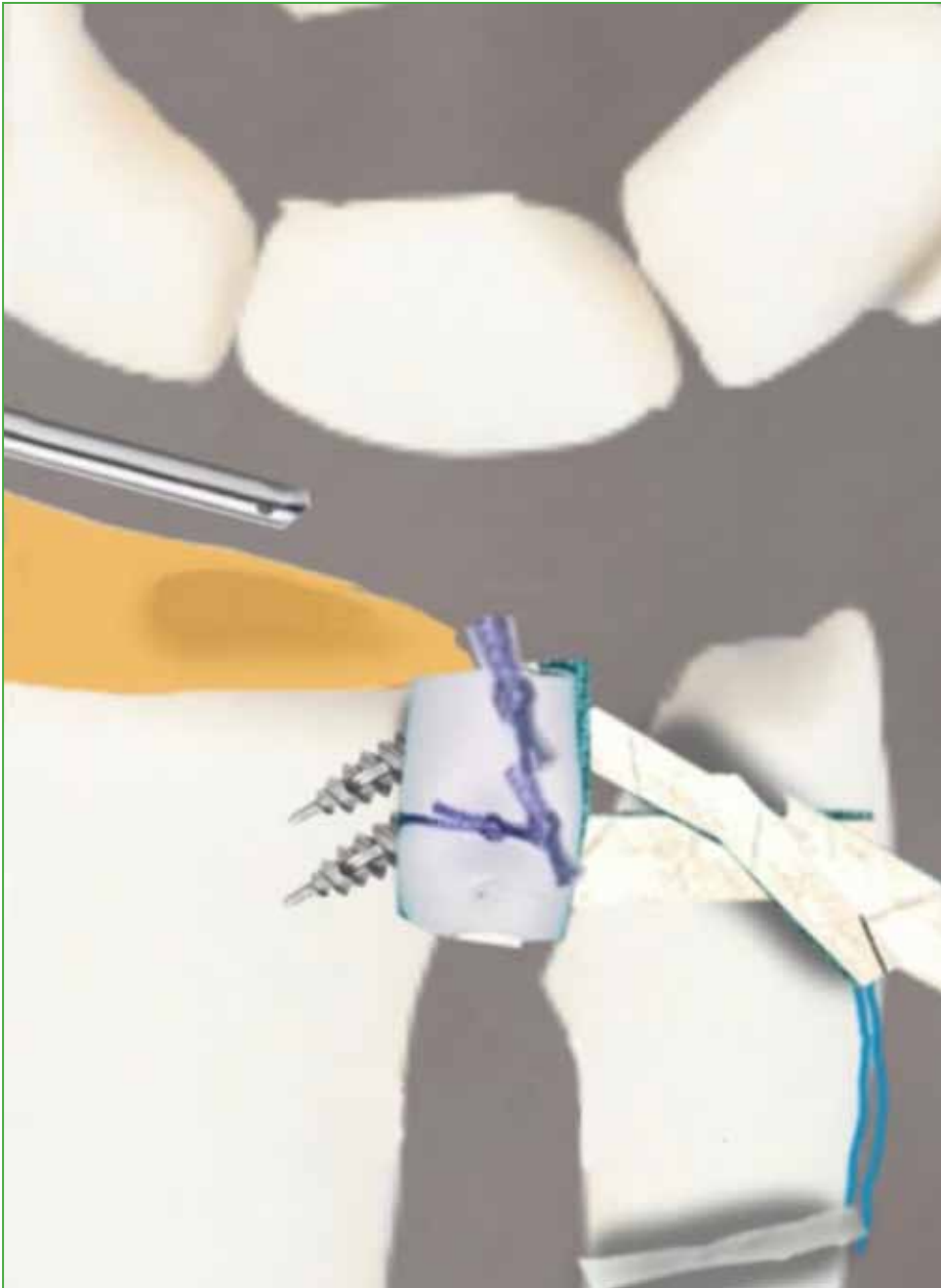
Figure 14. Fixed polyester cylinder at the distal radioulnar joint with the two tendon strands entering the ulna.

If the graft is taut, the excess threads are cut with arthroscopy scissors.

To finalize the technique, both strands of the graft previously passed through the ulnar tunnel are tensioned from the ends of their threads and fixed to the ulnar metaphysis with a knotless anchor. This step is performed with an impacted 2.5 mm knotless anchor device, which consists of a biodegradable screw inside a shaft with an eyelet at the end. The 4 ends of the sutures of the tendon strands are placed inside the eyelet of the fixation system. A 2.2 mm bone tunnel is created using a drill guide to avoid damage to the dorsal sensory branch of the ulnar nerve. This hole is made horizontally on the ulnar metaphysis 1 cm below the previously created ulnar tunnel (Scheme 8).



Scheme 8. Final fixation of the graft in the ulnar metaphysis by means of a knotless anchor.

The traction exerted on the wrist is removed and the fixation device with the sutures inside it is introduced, tightening the 4 ends of the sutures and impacting with a hammer. The shaft of the device is removed and the free ends of the sutures are pulled to make sure that the screw has been inserted correctly.

Finally, the wrist is placed in traction again and the stability and pronation of the joint are evaluated after fixed glider interposition. (Figure 15) (Video).

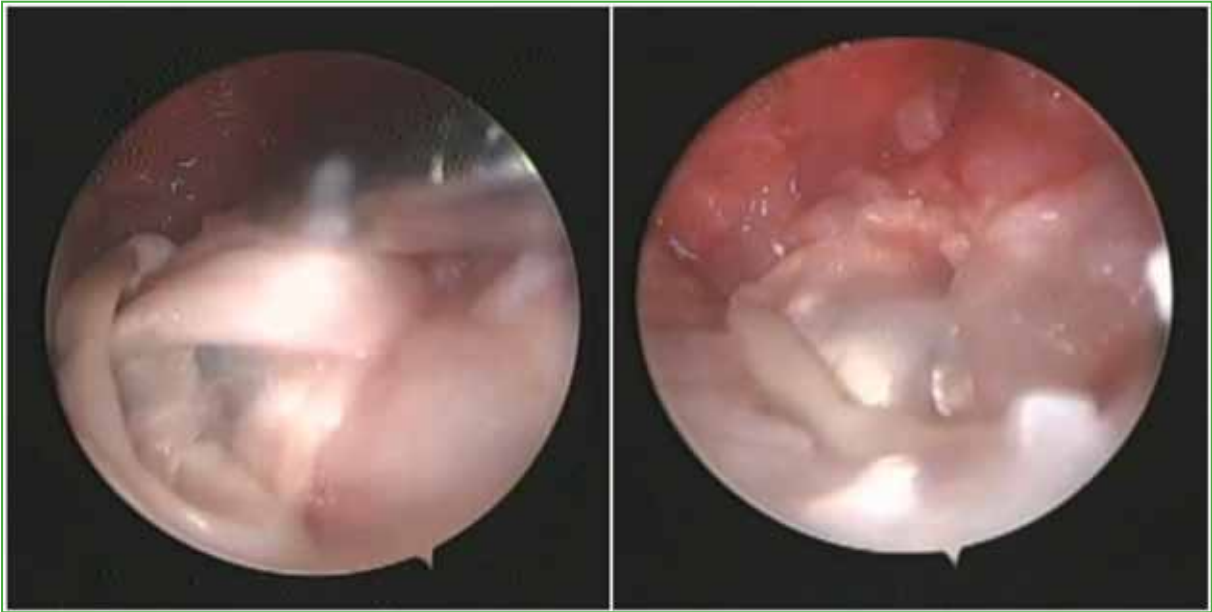

Figure 15. Fixation of the polyester cylinder with both strands entering the ulna stabilizing the distal radioulnar joint.

Figure 16 shows the preoperative and postoperative radiographs of one patient and **Figure 17** shows preoperative and postoperative images of another case in the series.

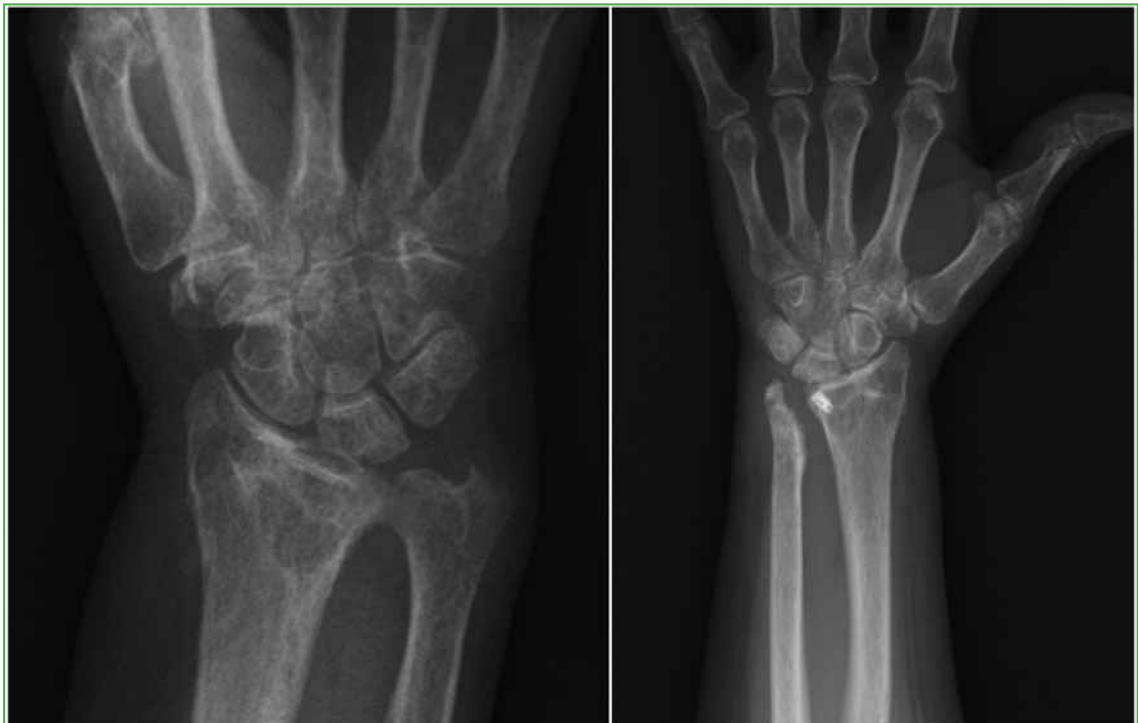

Figure 16. Wrist radiographs, AP view. **A.** Preoperative. **B.** Postoperative.

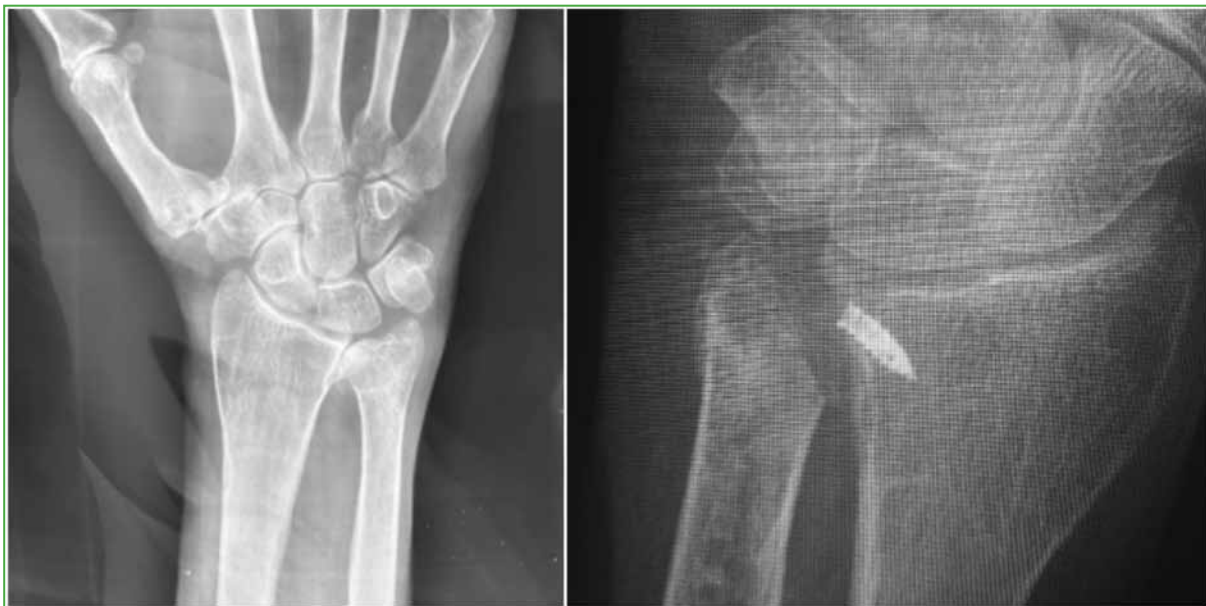

Figure 17. Wrist radiographs, AP view. A. Preoperative. B. Postoperative.

After the operation, the portals are closed with simple sutures, and a sugar-tong splint is applied for three weeks. Rehabilitation begins thereafter with the hand therapy team.

RESULTS

Five patients were evaluated retrospectively with follow-up periods ranging from 6 to 19 months (mean: 11 months). Four patients had osteoarthritis secondary to fractures, while one patient presented with primary osteoarthritis.

In all cases, the time between injury and surgery exceeded one year. Wrist arcs of motion were measured using a standard PVS hand goniometer, with the following results: 75° of pronation, 70° of supination, 80° of extension, and 70° of flexion.

Grip strength was assessed using a standard hydraulic dynamometer (Baseline-Orthowell®), revealing that patients achieved 70% of the grip strength of their contralateral hands. The mean DASH (Disabilities of the Arm, Shoulder, and Hand) questionnaire score improved from 56 preoperatively to 20 postoperatively. On the Mayo Wrist Score (MWS) scale, outcomes were rated as excellent in 83% of cases and good in 17%; no poor outcomes were observed. The visual analog scale (VAS) for pain decreased from 8 points before surgery to 3 points at the final follow-up. Screwdriver and Nakamura tests were negative in all patients.

No cases of infection, nerve paresthesia, or scarring complications were reported in the study population.

One complication occurred: a fracture of the ulnar styloid was identified in one patient through postoperative radiography. This fracture progressed to pseudoarthrosis but did not result in pain or functional impairments.

DISCUSSION

A retrospective study was conducted to analyze the surgical outcomes in five consecutive adult patients with DRUJ osteoarthritis treated using the glider arthroscopic interposition surgical technique. Good and excellent outcomes were achieved according to the MWS scale, with DASH scores improving postoperatively.

DRUJ osteoarthritis can arise from morphological or biomechanical changes. Certain morphological characteristics may predispose this joint to osteoarthritis. In wrists with a proximally oriented sigmoid notch, degenerative changes are more likely to develop in the DRUJ joint than in the ulnocarpal joint. Ulnar head morphology has been identified as the most statistically significant factor influencing the development of degenerative changes in the DRUJ. Bade et al. reported that the angle between the two facet joints of the ulnar head affects force transmission through the DRUJ. Greater inclination of the radial articular surface over the ulnar head increases force transmission.^{13,14}

Several surgical options have been proposed for treating DRUJ osteoarthritis. The Darrach procedure is relatively simple but results in an unstable joint with reduced strength, ulnar translocation, radioulnar impingement, and extensor tendon rupture. It is generally suitable only for elderly patients with low functional demands.⁶⁻⁸

In 2019, we described the Darrach technique performed arthroscopically, which resulted in complications similar to those of the open technique.¹⁵

The Sauvé-Kapandji procedure is another option for DRUJ osteoarthritis, particularly in young, active patients with TFCC tears but without instability. It restores wrist mobility, stability, and grip strength, although it carries complications similar to those of the Darrach technique.^{6-8,15}

In 2021, we presented case reports on the Sauvé-Kapandji technique performed arthroscopically. While the results were superior to the open approach, radioulnar impingement remained a complication.¹⁶

Ulnar and DRUJ prostheses are not available in our country and are therefore excluded from this discussion.⁶⁻⁸

DRUJ joint interposition techniques, such as the Bowers technique, preserve the soft tissue stabilizers around the DRUJ. These techniques use tendon interposition to maintain radioulnar separation and have shown favorable outcomes in preventing DRUJ impingement.¹⁷

Nawijn et al. evaluated 31 patients who underwent open Bowers interposition with an average follow-up of three years. The patients reported satisfaction with the technique.¹⁸

Similarly, Schober et al. studied 24 patients treated with the open Bowers technique between 1992 and 1997. They found improvements in mobility, strength, and pain scores, with good functional outcomes, although some patients experienced pain due to TFCC instability.¹⁹

The glider interposition surgical technique combines pain relief via ulnar osteotomy and DRUJ stabilization with a graft in a single procedure.

One advantage of this technique over the Bowers technique is its ability to stabilize the DRUJ joint through a graft with metaphyseal fixation in the ulna, achieving three objectives: pain relief, increased mobility, and joint stability.

Pillukat evaluated hemiresection interposition arthroplasty of the DRUJ and reported significant pain reduction, improved gross strength, and increased range of motion when preoperative turning motion was restricted. Although ulnar end instability may persist, it typically causes only minor symptoms. Patient satisfaction and functional outcomes were good.¹⁹ Our series yielded similar results despite the small sample size and short follow-up period.

As demonstrated in most soft tissue interposition studies, these techniques provide pain relief without the complications of proximal radioulnar impingement but may result in some degree of DRUJ instability.

The strength of the glider technique lies in its minimally invasive, arthroscopic approach, which avoids opening the dorsal capsule. It provides pain relief through ulnar osteotomy, incorporates interposition for separation, and restores DRUJ stability via a tendon graft.

However, this technique requires a learning curve in arthroscopic surgery and involves high costs due to the fixation and interposition materials. Additionally, a limitation of this study is the small sample size and short follow-up duration.

CONCLUSIONS

The glider arthroscopic interposition technique offers an alternative to current joint salvage procedures. It is minimally invasive, preserves soft tissue structures, is reproducible, relieves DRUJ pain, and provides additional joint stability, resulting in acceptable mobility and good functional outcomes. An added advantage is its ability to avoid the proximal radioulnar impingement often seen with other salvage techniques.

Conflict of interest: The authors declare no conflicts of interest.

REFERENCES

1. Green DP Wolfe SW. *Green's operative hand surgery*, 5th ed. New York: Elsevier Inc.; 2013.
2. Spies CK, Langer MF, Unglaub F, Mühlendorfer-Fodor M, Müller LP. Carpus and distal radioulnar joint, clinical and radiological examination. *Unfallchirurg* 2016;119(8):673-89. <https://doi.org/10.1007/s00113-016-0206-0>
3. Isaacs JE, Chhabra A. *Arthritis & arthroplasty: The hand, wrist and elbow*. Philadelphia, PA: Elsevier; 2011.
4. Chung KC. *Hand and upper extremity reconstruction*. Philadelphia, PA: Elsevier Health Sciences; 2010.
5. Luchetti R, Khanchandani P, Da Rin F, Borelli PP, Mathoulin C, Atzei A. Arthroscopically assisted Sauve-Kapandji procedure: An advanced technique for distal radioulnar joint arthritis. *Tech Hand Upper Extrem Surg* 2008;12(4):216-20. <https://doi.org/10.1097/BTH.0b013e31818ee28a>
6. Gupta RK, Soni A, Masih GD. "Quadrangular-construct" modification of Sauve-Kapandji procedure. *Indian J Orthop* 2017;51(1):99-102. <https://doi.org/10.4103/0019-5413.197556>
7. Guo Z, Wang Y, Zhang Y. Modified Sauve-Kapandji procedure for patients with old fractures of the distal radius. *Open Med (Wars)* 2017;12:417-23. <https://doi.org/10.1515/med-2017-0060>
8. Tomori Y, Sawaizumi T, Nanno M, Taka S. Functional outcomes after the Sauvé-Kapandji procedure for distal radio-ulnar post-traumatic instability: a case-control comparison of three different operative methods of stabilization of the ulnar stump. *Int Orthop* 2028;42:2173-9. <https://doi.org/10.1007/s00264-018-4042-4>
9. Tolat AR, Stanley JK, Trail IA. A cadaveric study of the anatomy and stability radioulnar joint in the coronal and transverse planes. *J Hand Surg Br* 1996;21(5):587-94. [https://doi.org/10.1016/s0266-7681\(96\)80136-7](https://doi.org/10.1016/s0266-7681(96)80136-7)
10. Schmidbauer S, Ladurner R, Hallfeldt KK, Mussack. Heavy weight versus low weight polypropylene meshes for open sublay mesh repair of incisional hernia. *Eur J Med Res* 2005;10(6):247-53. PMID: 16033714
11. Atzei A, Luchetti R. Foveal TFCC tear classification and treatment. *Hand Clin* 2011;27(3):263-72. <https://doi.org/10.1016/j.hcl.2011.05.014>
12. Kermarrec G, Cohen G, Upex P, Fontes D. Arthroscopic foveal reattachment of the triangular fibrocartilaginous complex. *J Wrist Surg* 2020;9(3):256-62. <https://doi.org/10.1055/s-0040-1702929>
13. Bade H, Koebke J, Schloter M. Morphology of the articular surfaces of the distal radio-ulnar joint. *Anat Rec* 1996;246(3):410-4. [https://doi.org/10.1002/\(SICI\)1097-0185\(199611\)246:3<410::AID-AR12>3.0.CO;2-R](https://doi.org/10.1002/(SICI)1097-0185(199611)246:3<410::AID-AR12>3.0.CO;2-R)
14. Hollevoet N, Verdonk R, Van Maele G. The influence of articular morphology on non-traumatic degenerative changes of the distal radioulnar joint. A radiographic study. *J Hand Surg Br* 2006;31(2):221-5. <https://doi.org/10.1016/j.jhsb.2005.10.012>
15. Kaempf R, Aita M, Delgado PJ. *Cirurgia minimamente invasiva. Artroscopia do Punho*; Rio de Janeiro: Di Livros Editora Limitada; 2022: cap. 17.
16. Sala JM, Ambrosi AD, Ledesma AD. Resultados del tratamiento de la artrosis radiocubital distal mediante técnica de Sauvé-Kapandji artroscópica. *Artroscopia*. 2021;28(4). Available at: <https://www.revistaartroscopia.com.ar/index.php/revista/article/view/159>
17. Yayac M, Padua FG, Banner L, Seigerman DA, Beredjiklian PK, Aita DJ, et al. Treatment outcomes in patients undergoing surgical treatment for arthritis of the distal radioulnar joint. *J Wrist Surg* 2020;9(3):230-4. <https://doi.org/10.1055/s-0040-1702200>
18. Nawijn F, Verhiel SHWL, Jupiter JB, Chen NC. Hemiresection interposition arthroplasty of the distal radioulnar joint: A long-term outcome study. *Hand (NY)* 2009;16(5):484-97. <https://doi.org/10.1007/s00064-009-1913-2>
19. Schober F, Van Schoonhoven J, Prommersberger KJ, Lanz U. Die Hemiresektions-Interpositionsarthroplastik nach Bowers zur Behandlung der posttraumatischen Arthrose des distalen Radioulnargelenks nach distalen Radiusfrakturen. [Bowers hemi-resection-interposition arthroplasty for treatment of post-traumatic arthrosis of the distal radio-ulnar joint after distal radius fractures]. *Handchir Mikrochir Plast Chir* 1999;31(6):378-82. <https://doi.org/10.1055/s-1999-13557>