

Case Presentation

Juan Manuel Romero Ante,^{*} Carlos A. Polo Marulanda,^{**} Cristian Valderrama,[#] Cynthia Delgado Soto^{##}

^{*}Orthopedics and Traumatology Service, Hospital Alma Máter, Medellín, Colombia

^{**}Foot and Ankle Department, Orthopedics and Traumatology Service, Neuromédica, Medellín, Colombia

[#]Universidad de Antioquia, Medellín, Colombia

^{##}Laboratorio de Patología y Citología (LAPACI), Clínica Medellín de Occidente, Medellín, Colombia

Case Resolution on page 286.

Tumor of the Hallux

ABSTRACT

A 34-year-old man presented with a progressively enlarging mass in the right hallux, with a 2-year history. The lesion was painful due to mechanical compression against the adjacent toes, particularly when wearing shoes with a narrow toe box. There were no signs of local infection, nocturnal pain, or associated weight loss. Radiographs showed a lesion in the proximal metaphyseal-diaphyseal region of the distal phalanx. Magnetic resonance imaging demonstrated an eccentrically located lesion with low signal intensity on T1-weighted sequences and high signal intensity on T2-weighted sequences.

Keywords: Neoplasm; eccentric location; atypical; intramedullary; hallux.

Level of Evidence: IV

Tumoración en el hallux

RESUMEN

Un hombre de 34 años consulta por una masa en el hallux derecho, de crecimiento progresivo y 2 años de evolución, dolorosa por la compresión mecánica con los dedos adyacentes, en especial, con el uso de calzado estrecho en su cámara anterior, sin signos de infección local, ni dolor nocturno o pérdida de peso asociada. La radiografía muestra una lesión en la falange distal metafiso-diafisaria proximal. La resonancia magnética permite visualizar una lesión de baja intensidad en secuencia T1 y de alta intensidad en secuencia T2, de localización excéntrica.

Palabras clave: Neoplasia; localización excéntrica; atípica; endomedular; hallux.

Nivel de Evidencia: IV

INTRODUCTION

A 34-year-old man employed at a plastics manufacturing plant, with a medical history significant only for dysautonomia, presented with a 2-year history of a progressively enlarging mass on the lateral aspect of the right hallux. The lesion was initially painless but had become symptomatic over the previous weeks, causing mechanical discomfort due to rubbing against the second toe when wearing shoes. The patient denied any ulceration or sinus tract formation, lesions involving the lesser toes, or ipsilateral inguinal lesions. He also denied weight loss, nocturnal pain, and pain at rest.

Physical examination revealed a firm, immobile nodular lesion on the lateral aspect of the distal phalanx of the hallux. The lesion was nonulcerated and showed no evidence of increased vascularity. Nail dystrophy secondary to previous onychocryptosis was noted, without signs of active infection. No clinical extension of the lesion into the interphalangeal joint was evident, and joint motion was preserved.

Received on August 22nd, 2025. Accepted after evaluation on December 16th, 2025 • Dr. JUAN MANUEL ROMERO ANTE • juanmaro04041977@gmail.com  <https://orcid.org/0000-0002-9390-9496>

How to cite this article: Romero Ante JM, Polo Marulanda CA, Valderrama C, Delgado Soto C. Postgraduate Orthopedic Instruction – Imaging. Case Presentation. *Rev Asoc Argent Ortop Traumatol* 2026;91(3):189-191. <https://doi.org/10.15417/issn.1852-7434.2026.91.3.2218>

FINDINGS AND INTERPRETATION OF IMAGING STUDIES

Anteroposterior and oblique radiographs of the foot demonstrated an abnormality involving the distal phalanx of the hallux (Figure 1).

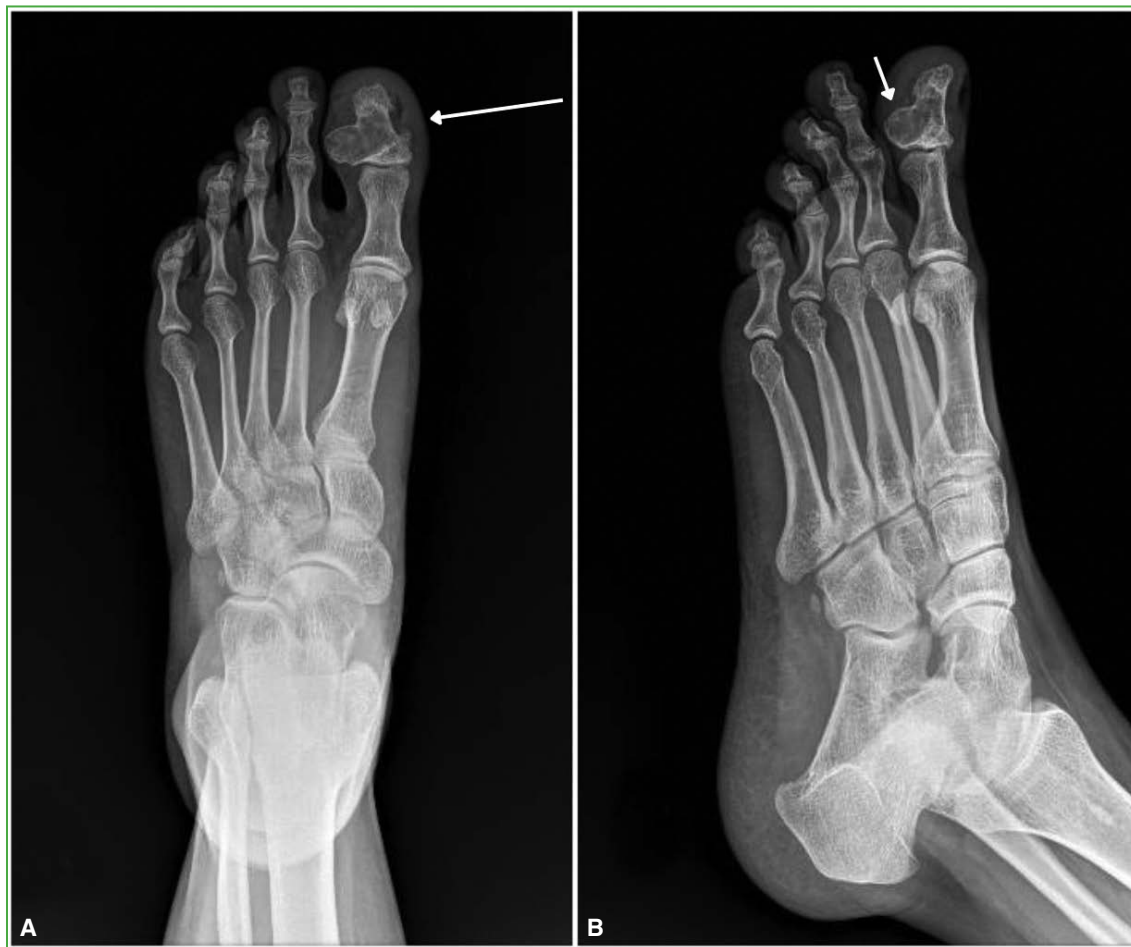

Figure 1. Radiographs of the right foot. **A.** Anteroposterior view. Eccentric lesion involving the proximal metaphyseal-diaphyseal region of the distal phalanx of the hallux (long arrow). **B.** Oblique view. Thinning of the dorsolateral cortex (short arrow).

Further imaging evaluation included contrast-enhanced magnetic resonance imaging (MRI) (Figure 2).

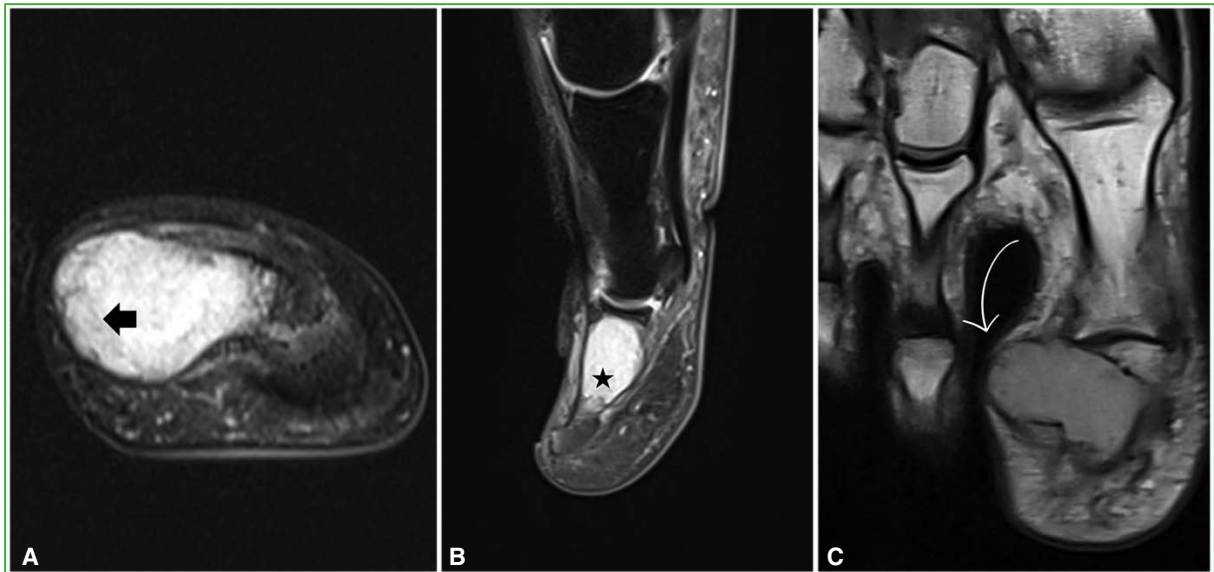


Figure 2. Contrast-enhanced magnetic resonance imaging of the right foot. **A.** Axial T2-weighted image showing a hyperintense lesion adjacent to the lateral cortex of the distal phalanx of the hallux (black arrowhead). **B.** Sagittal T2-weighted image demonstrating intramedullary extension within the distal phalanx of the hallux (black star). **C.** Coronal T1-weighted image showing lateral cortical destruction of the distal phalanx and a homogeneous, non-septated lesion (white curved arrow).

Based on the clinical presentation, physical examination findings, and imaging studies, surgical treatment was planned, consisting of complete tumor excision with tissue sampling for histopathological examination, placement of bone graft within the residual defect, and possible internal fixation if required.

Conflicts of interest: The authors declare no conflicts of interest.

C. A. Polo Marulanda ORCID ID: <https://orcid.org/0000-0002-4736-8393>

C. Valderrama ORCID ID: <https://orcid.org/0009-0002-3614-6952>

C. Delgado Soto ORCID ID: <https://orcid.org/0000-0001-5461-8955>

REFERENCES

1. Käfer W, Kinzl L, Sarkar MR. Epiphysenfraktur der proximalen Tibia. *Unfallchirurg* 2008;111(9):740-5. <https://doi.org/10.1007/s00113-007-1390-8>
2. Israni P, Panat M. Proximal tibial epiphysis injury (flexion type, Salter-Harris type 1). *J Orthop Case Rep* 2016;6(4):62-5. <https://doi.org/10.13107/jocr.2250-0685.572>
3. Ryu RK, Debenham JO. An unusual avulsion fracture of the proximal tibial epiphysis. Case report and proposed addition to the Watson-Jones classification. *Clin Orthop* 1985;194:181-4. PMID: 3978913