

Post-traumatic lumbosacral unilateral facet dislocation

MANUEL GONZÁLEZ MURILLO,* LORENZO ZUÑIGA GÓMEZ,** PATRICIA ÁLVAREZ GONZÁLEZ,**
FELISA SÁNCHEZ-MARISCAL,** JAVIER PIZONES ARCE,** ENRIQUE IZQUIERDO NÚÑEZ**

*Hospital Universitario Torrejón,**Hospital Universitario Getafe
Madrid, España

Received on January 25th, 2015; accepted after evaluation on February 17th, 2015 • MANUEL GONZÁLEZ MURILLO, MD • mgonzalezmurillo@hotmail.es

Introduction

Literature reports about fifty cases of lumbosacral dislocations; most of them are bilateral facet dislocations.¹

Unilateral lumbosacral dislocations result from high energy mechanisms of injury that involve hyper-flexion, rotation and compression. In most cases, they are associated with other injuries such as transverse processes fractures.

The first cases that were published supported orthopedic treatment with immobilization.²⁻⁵ However, recent publications back surgical setting and stabilization by orthopedic hardware as standard treatment.^{1,6,7}

We report the diagnosis and surgical treatment of this rare traumatic condition.

Case

A forty-two year-old female intensivist doctor that had suffered a car crash a month before. In the beginning she was diagnosed an L5 transverse process fracture and given conservative treatment. Ever since, she has complained of severe lumbosacral pain with lumbosacral sensation of crepitation that increases by slight rotation; she also shows lumbosacral blockage at spine flexion-extension with neither lower limbs irradiation nor distal neurological involvement.

She is taken anterior-posterior and lateral X-rays of the lumbar spine that show L5 transverse process fracture and slight L5-S1 spondylolisthesis (Figure 1A). Given these findings, she is taken a 3D CT scan that shows unilateral dislocation of the right articular process at L5-S1 level,

with some fragmentation of the right lower articular process in its posterior-medial aspect and grade I L5-S1 anterior spondylolisthesis. MRI shows disc rupture with right central-lateral disc protrusion (Figures 1B and C).

Due to the patient's symptoms and because of these findings, she was treated with circumferential arthrodesis at L5-S1 level by interbody cages and pedicle screws through a sole posterior approach (Figure 2). Among the intra-operative findings, it is worth mentioning the right facet overlap between L5 and S1, the rupture of the posterior ligamentous complex and the rupture of the disc ring.

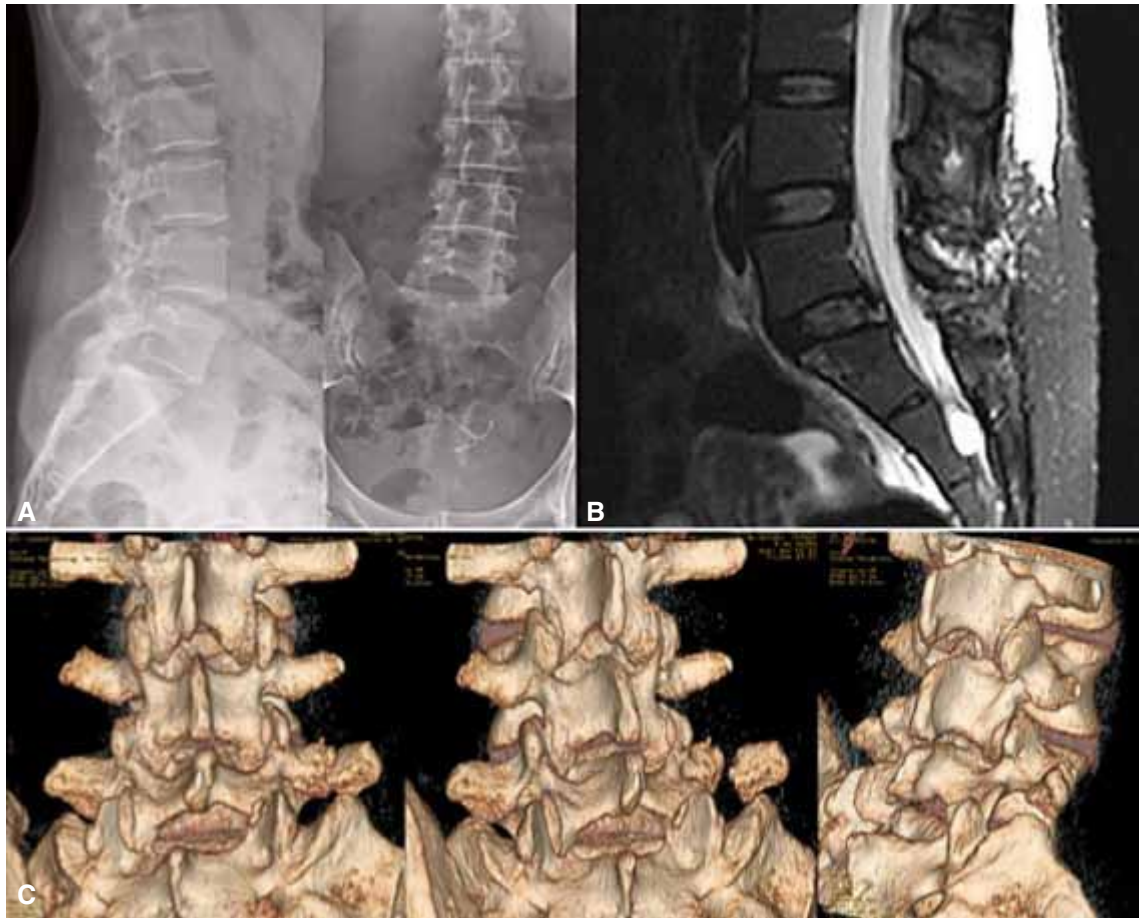
Six months after the surgery, the patient shows no symptoms and complete mobility, and she has retaken her daily activities with no restrictions whatsoever.

Discussion

In 1940, Watson-Jones was the first one to describe the lumbosacral dislocation resulting from a hyper-extension mechanism. Roaf, however, in the 1960s states that the mechanism of injury most frequently seen in lumbosacral dislocation with no fracture is hyper-flexion with rotation.⁸ Nevertheless, the majority of authors believe that this injury results from a mixed mechanism of hyper-flexion and compression. We have to tell it apart from traumatic spondylolisthesis, in which the relationship between facets remains.⁶

The lumbosacral dislocation is an infrequent injury that results from the combination of a high energy mechanism of injury with predisposing anatomic factors, such as

Conflict of interests: The authors have reported none.



▲ **Figure 1.** A. Anterior-posterior and lateral X-rays. Right L5 transverse process fracture with mild anterior spondylolisthesis. B. Lumbosacral MRI, sagittal section. Rupture of the posterior ligamentous complex and disc extrusion with injury of the posterior ligamentous complex. C. 3D CT scan: lumbosacral unilateral fracture-dislocation.

the frontal orientation of the facets, the intrinsic stability of the lumbosacral area and the powerful iliolumbar ligaments.^{2,5} Most of the patients show associated injuries, such as sacral promontory fractures and fractures of the lumbar transverse processes. Moreover, they might show perineal injuries.

The diagnosis of this injury is based on an initial X-ray analysis of good quality that shows the abnormal relationship between the lumbosacral facets. However, more often than not the X-rays taken at the ER are not good, and the injury can be underestimated. In the case that we present, we can see L5-S1 anterior spondylolisthesis and right L5 transverse process fracture. This led us to ask for other imaging studies (Figure 1A).

In the 3D CT scan we can see that the right L5 articular facet is overlapping the S1 facet on the front, and also the right L5 transverse process fracture (Figure 1C). Similarly, the MRI shows rupture of the posterior ligamentous complex and rupture of the intervertebral disc with disc extrusion (Figure 1B).

According to Aihara, lumbosacral fracture-dislocations can be classified into five types:⁹ type 1, lumbosacral facet unilateral dislocation with or without facet fracture; type 2, lumbosacral facet bilateral dislocation with or without facet fracture; type 3 lumbosacral unilateral dislocation and contralateral fracture of the lumbosacral facet; type 4, L5 vertebral body dislocation with bilateral fracture of the interarticular portion; and type 5, L5 vertebral body dislocation with fracture of the vertebral body or the pedicle, with or without lamina and facet injury. The case that we present here can be considered a type 1 lesion.

Facet unilateral dislocations are injuries mostly seen in the mobile cervical spine.⁷ This way, it is thought that it is hardly possible in the lumbosacral spine due to the orientation of the articular facets and the stronger anatomic structures that give more intrinsic stability. The neurologic injury is hardly likely as compared to bilateral facet dislocations.⁷

The therapeutic management of lumbosacral dislocations has varied throughout history. Newell³ and Zoltan⁵

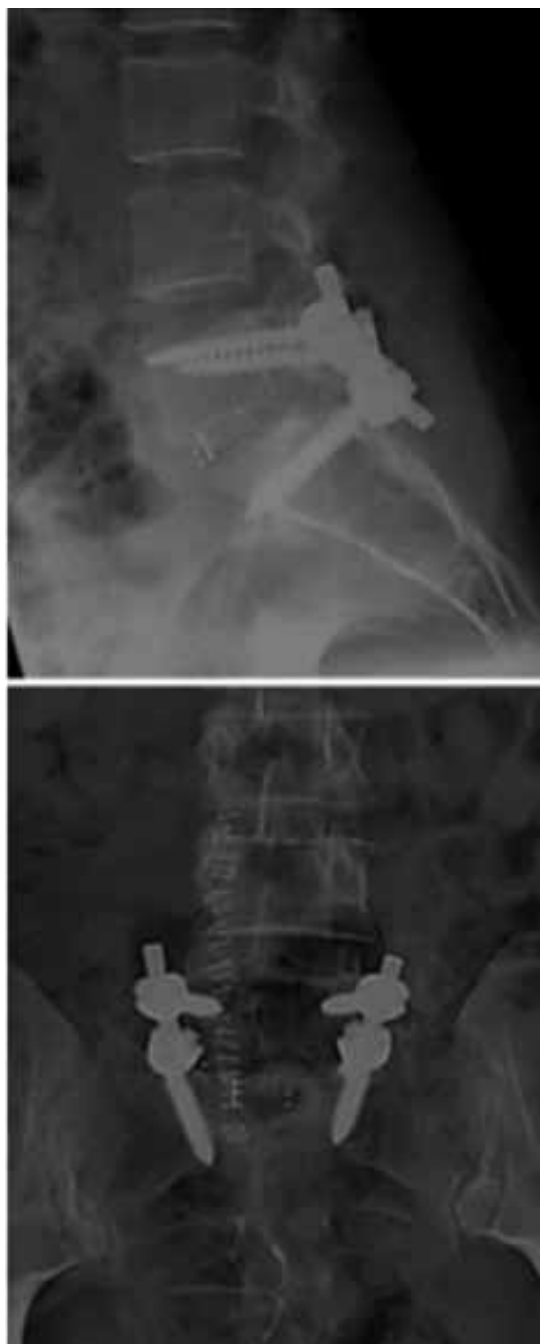report good results giving conservative treatment to dislocations without setting. Beguiristain¹⁰ reports successful results at eight-year follow-up using traction and a lumbar cast in a five year-old child with pure traumatic anterior lumbosacral dislocation, even though the dislocation has just been partially set. In the case of sub-acute or inveterate dislocations, some authors suggest conservative treatment given the complexity of the surgical treatment.⁴

Independently of the classification, this injury affects the three columns damaging the posterior ligamentous complex with capsular rupture, with disc rupture in this case, and also with rotation; therefore, it causes instability. Acute dislocations can be set by distraction with transpedicle screws. On some occasions, however, partial facetectomies are really helpful to facilitate dislocation setting. It is worth mentioning that neurological monitoring is most useful during these maneuvers to avoid iatrogenic injuries of the nervous elements.^{1,7}

Circumferential fixation with pedicle screws and interbody cages is the treatment of choice and, nowadays, the sole posterior approach is recommended to avoid complications such as the retrograde ejaculation associated with the anterior approach.^{1,7} In our patient, the circumferential arthrodesis was performed using an interbody cage with local autologous bone, rods, and L5-S1 pedicle screws (Figure 2).

Conclusion

Lumbosacral unilateral dislocations are infrequent injuries that result from high energy mechanisms. Diagnosis is based on proper physical examination and imaging (X-rays, CT scan and MRI). Nowadays, the treatment of choice consists of open setting, facetectomies, decompression and circumferential fixation with interbody cages and pedicle screws, so as to keep stability with restoration of alignment and decompression of neurologic elements.



▲ Figure 2. Post-operative X-ray check.

Bibliografía

1. Xu R, Solakoglu C, Kretzer RM, McGirt MJ, Witham TF, Bydon A. Bilateral traumatic dislocation without fracture of the lumbosacral junction. *Spine* 2011;36:E662-8.
2. Boyd MC, Yu WY. Closed reduction of lumbosacral fracture dislocations. *Surg Neurol* 1985;23:295-8.
3. Newell RLM. Lumbosacral fracture dislocation: A case managed conservatively, with return to heavy work. *Injury* 1977;9:131-4.
4. Veras del Monte LM, Bago J. Traumatic lumbosacral dislocation. *Spine* 2000;25:756-9.
5. Zoltan JD, Gilula LA, Murphy WA. Unilateral facet dislocation between the fifth lumbar and first sacral vertebrae: Case report. *J Bone Joint Surg Am* 1979;61:767-9.

6. Cruz-Conde R, Rayo A, Rodriguez de Oya R, Berjano P, Gárate E. Acute traumatic lumbosacral dislocation treated by open reduction internal fixation and fusion. *Spine* 2003;28:E51-3.
7. Tsirikos AI, Saifuddin A, Noordeen MH, Tucker SK. Traumatic lumbosacral dislocation: report of two cases. *Spine* 2004; 29(8):E164-8.
8. Roaf R. A study of mechanics of spinal injuries. *J Bone Joint Surg Br* 1960;42:810-23.
9. Aihara T, Takahashi K, Yamagata M, Moriya H. Fracture-dislocation of the fifth lumbar vertebra: A new classification. *J Bone Joint Surg Br* 1998;80:840-5.
10. Beguiristain J, Schweitzer D, Mora G, Pombo V. Traumatic lumbo-sacral dislocation in a 5-year-old boy with eight years follow-up. *Spine* 1995;20:362-6.