

# Early experience in a High Complexity Hospital with the vascularized fibular graft in segmental bone defects of the upper limb

MARTÍN M. ESTEFAN, FERNANDO DIAZ DILERNIA, GERARDO L. GALLUCCI,  
PABLO DE CARLI, JORGE G. BORETTO

*Hand and Upper Limb Surgery Section, Orthopedics Department "Dr. Prof. Carlos E. Ottolenghi",  
Hospital Italiano of Buenos Aires, Ciudad Autónoma de Buenos Aires*

Received on February 24th, 2016; accepted after evaluation on May 16th, 2017 • JORGE G. BORETTO, MD • jorge.boretto@hospitalitaliano.org.ar

**Introduction:** Long bones' >6 cm bone defects represent a problem difficult to solve in upper limb reconstruction. The vascularized fibula has become the main reconstruction method due to its biological advantages. The aim of this study was to assess bone consolidation rates and spans, as well as the associated complications in a continuous series of patients.

**Materials and Methods:** We carried out a 5-year review. We included the patients that were treated for >6 cm defects in their upper limbs. We analyzed pre-operative, intra-operative and immediately post-operative, and remote post-operative variables.

**Results:** Throughout the assessment period, 6 patients (4 males/2 females) met the inclusion criteria. Average age was 47 years old. The time passed between the initial traumatism and reconstructive surgery varied between 2 and 21 years. The average bone defect was 10 cm. Average follow-up was 17 months. We got bone consolidation in all cases in 16 weeks, on average. Two patients suffered post-operative complications. Patient suffered neither complications nor functional sequela in the donor zone.

**Conclusions:** The vascularized fibular graft is a valid option for the reconstructive surgical treatment of >6cm segmental bone defects in the upper limb, with high bone consolidation rates, even in the cases with multiple previous surgeries and in long-term lesions. Technical details avoid complications in the donor zone.

**Key words:** Vascularized fibula; bone defect; reconstructive surgery.

**Level of evidence:** IV

## EXPERIENCIA INICIAL EN UN CENTRO DE ALTA COMPLEJIDAD CON EL INJERTO VASCULARIZADO DE PERONÉ EN DEFECTOS ÓSEOS SEGMENTARIOS DEL MIEMBRO SUPERIOR

**Introducción:** Los defectos óseos >6 cm en los huesos largos plantean un problema difícil de solucionar en la reconstrucción del miembro superior. El peroné vascularizado se ha convertido en el principal método de reconstrucción por sus ventajas biológicas. El objetivo de este estudio fue evaluar la tasa y el tiempo de consolidación ósea, y las complicaciones asociadas en una serie continua de pacientes.

**Materiales y Métodos:** Se realizó una revisión durante un período de 5 años. Se incluyeron los pacientes que fueron tratados por defectos >6 cm en el miembro superior. Se analizaron variables preoperatorias, intraoperatorias y posoperatorias inmediatas y alejadas.

Conflict of interests: The authors have reported none.

**Resultados:** Durante el período de evaluación, 6 pacientes (4 hombres/2 mujeres) cumplían con los criterios de inclusión. La edad promedio fue de 47 años. El tiempo transcurrido entre el trauma inicial y la cirugía reconstructiva varió de 2 a 21 años. El defecto óseo promedio fue de 10 cm. El tiempo de seguimiento promedio fue de 17 meses. Se logró la consolidación ósea en todos los casos, como promedio, en 16 semanas. Dos pacientes sufrieron complicaciones posoperatorias. Ninguno presentó complicaciones o secuelas funcionales en la zona dadora.

**Conclusiones:** El injerto óseo vascularizado de peroné es una opción válida para el tratamiento quirúrgico reconstructivo de defectos óseos segmentarios >6 cm en el miembro superior, con una tasa alta de consolidación, aun en casos con múltiples cirugías previas o con una lesión de larga evolución. Los detalles técnicos previenen las complicaciones en la zona dadora.

**Palabras clave:** Peroné vascularizado; defecto óseo; cirugía reconstructiva.

**Nivel de Evidencia:** IV

## Introduction

Long bones' >6 cm bone defects, secondary to trauma, infections or tumor resection represent a problem difficult to solve in upper limb reconstruction, especially when they are associated with the loss of soft tissues coverage. The therapeutic alternatives for reconstruction of such defects are limited—among the options we can mention allogeneic bone graft,<sup>1</sup> vascularized fibular graft<sup>2-5</sup> and the induced membrane technique.<sup>6</sup>

The vascularized fibular graft has become the main therapeutic method due to its biologic advantages, among which there is consistent anatomy and vascularization, what allows surgeons a reproducible technique.<sup>3</sup>

Originally developed as bone graft by Taylor et al.<sup>2</sup> in 1975, it was later modified with the addition of a fasciocutaneous flap in 1983 by Chen et Yan.<sup>7</sup> Beppu et al.<sup>8</sup> reported that the most consistent cutaneous blood vessels are in the distal two thirds of the leg; therefore, this zone is the one preferred to design the fasciocutaneous flap. The inclusion of the fasciocutaneous flap brings about technical advantages.<sup>9,10</sup> First of all, it gives cutaneous coverage in the case of deficit and, secondly, it plays the role of cutaneous monitor, giving continuous and immediate information about the flap and the bone graft blood supply.<sup>11</sup>

The aim of this study was to assess the consolidation rates and spans, along with the associated complications in a continuous series of patients with >6 cm bone defects in their upper limbs.

## Materials and methods

We carried out an electronic revision of medical histories to identify all the patients that were subject to reconstruction with vascularized fibular graft between 2011 and 2016.

We included all the patients that were treated due to >6 cm bone defects in the upper limb and excluded those with lower limb reconstruction, the cases of co-adjuvant therapy (radiotherapy) for the treatment of oncologic disease, and the patients we used this technique in as an

associated procedure to increase stability in shoulder arthrodesis.

The variables we analyzed are the following:

*Pre-operative variables:* Cause of bone defect, co-morbidities and the number of previous surgeries.

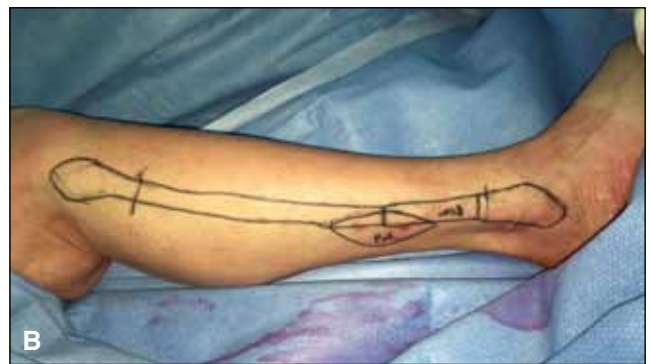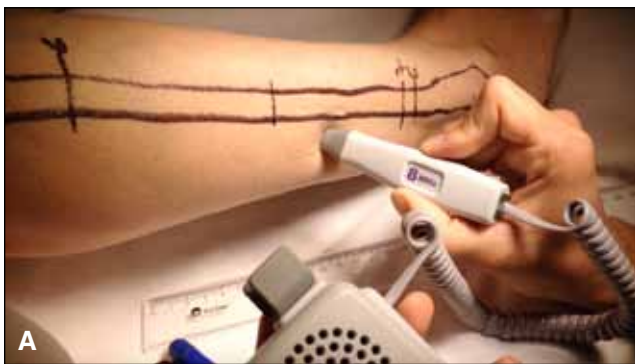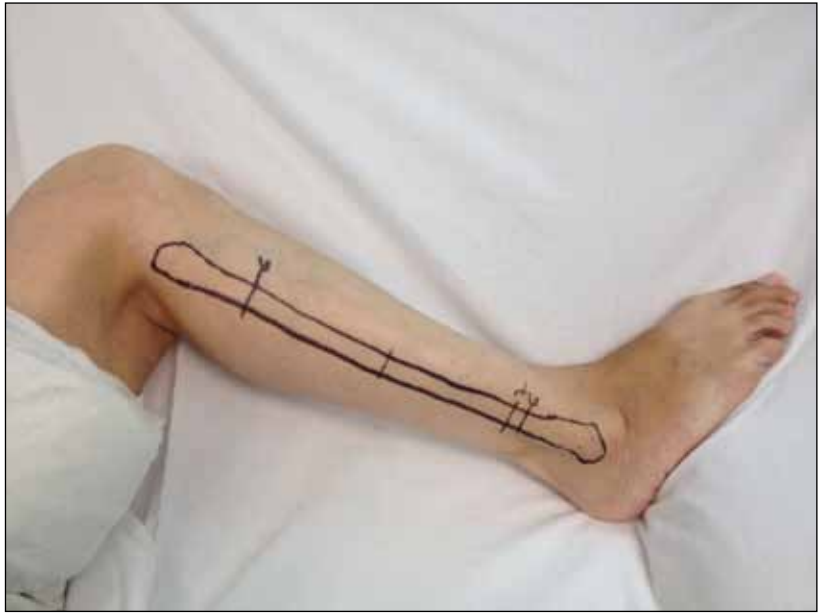
*Intra-operative and immediately post-operative variables:* Surgery duration, surgical teams, suture type, suture thread used, receptor blood vessels, blood transfusion and admission amount of time.

*Remote post-operative variables:* Time passed since surgery until bone consolidation, complications associated with the procedure and the donator area. We assessed post-operative mobility with a goniometer. In the patients with humeral reconstruction, we assessed shoulder and elbow mobility. In those we reconstructed the forearm in we assessed elbow, forearm and wrist mobility.

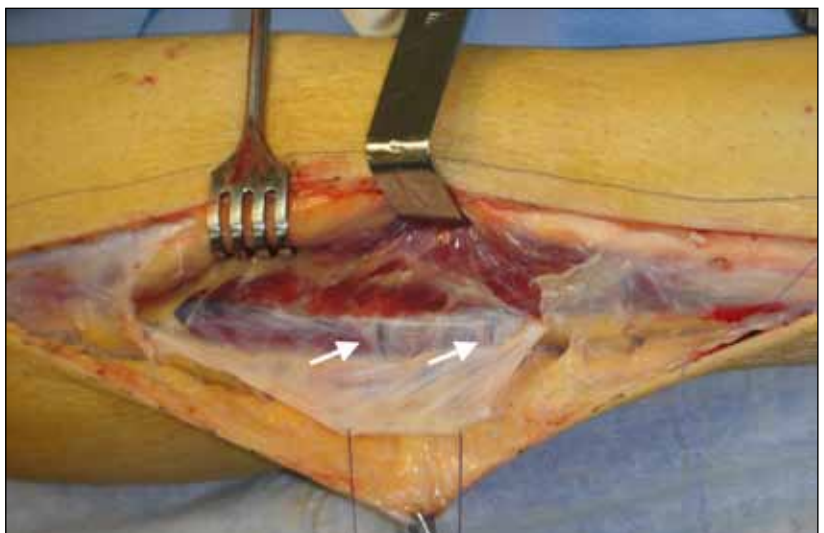
## Surgical technique

In the first surgical time we prepare the receptor bed for the vascularized bone graft and identify and spare the receptor blood vessels. Then, we go on to the surgical time in the lower limb. On the lateral aspect of the leg we delineate the subcutaneous fibular relief including both the lateral distal malleolus and the proximal fibular head. From the distal end of the lateral malleolus we establish 6 cm proximally as the lower limit for bone graft taking and, from the proximal end of the fibular head, we determine 6 cm distally as the proximal end (Figure 1). These hallmarks avoid instability of both ankle and knee joints, and they have to be carefully monitored to avoid complications at the donor zone level. On the dorsal edge of the fibula we identify the cutaneous arteries by Doppler-US and design a fasciocutaneous flap as needed (Figure 2). We carry out a lateral approach in the leg following the Gilbert's technique.<sup>12</sup> We identify the fibular muscle and the cutaneous arteries for the fasciocutaneous flap in the fascial septum between the fibular muscles and the soleus muscle (Figure 3). We carry out dissection and detachment of the fibular muscles in the anterior direction. We sever the anterior-medial fascial septum to get to the anterior-medial compartment, where we identify and spare the pedicle of the anterior tibial neurovascular bundle to avoid

**Figure 1.** Fibular design with proximal and distal safety limits. ▶



▲ **Figure 2.** A. Mapping of cutaneous arteries by 8 mHz Doppler-US. B. Pre-operative planning with the design of the associated fasciocutaneous flap.

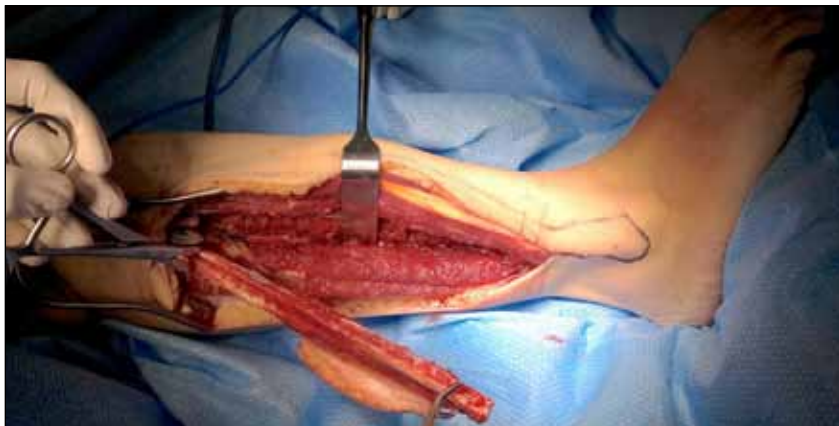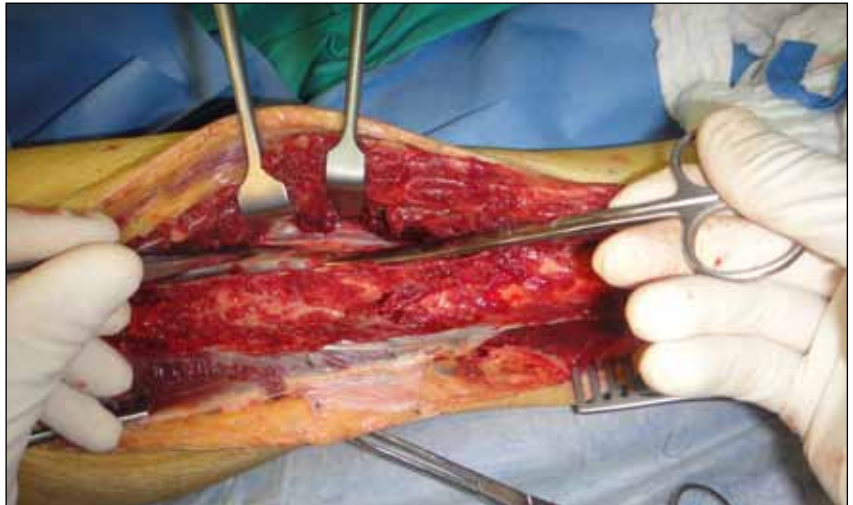


**Figure 3.** Identification of two cutaneous arteries (white arrows) in the inter-muscular septum. ▶

injury (Figure 4). We identify the interosseous membrane and sever it. We dissect the flexor hallucis muscle and identify the fibular artery and vein under magnifying devices. We carry out proximal and distal fibular osteotomies with oscillating saw and take the bone graft depending on the defect to reconstruct (Figure 5). We carry out dissection of the fibular artery in the proximal direction as much as the required length of the pedicle in the receptor area takes. Finally we sever the fibular artery and satellite

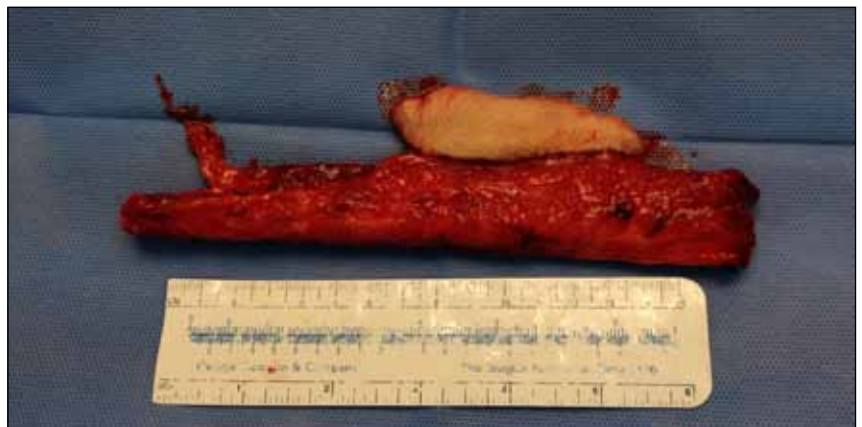veins, and take the osteocutaneous graft away from the leg (Figure 6). Back to the upper limb, we position the fibula and carry out osteosynthesis preferably with locking plate as bridge plate. Then we go under microscope on to termino-terminal or termino-lateral (depending on the case) arteriorrhaphy and venorrhaphy between the fibular bundle and the receptor vessels. Before releasing the haemostatic cuff and after blood vessels suture we administer the patient i.v. 70 UI/kg heparin.

**Figure 4.** Identification of the pedicle of the anterior tibial neurovascular bundle in the anterior-medial compartment of the leg. ▶



◀ **Figure 5.** Proximal and distal osteotomies in the fibula before severing the vascular pedicle from the bone graft.

**Figure 6.** Fibular bone graft with fasciutaneous flap. ▶





### Post-operative management

Patients are allocated to a common room, preferably and individual one for temperature management. The graft blood supply is controlled by Doppler-US in the cutaneous plate or, in cases of just bone grafting, we carry out a three-phase-scintigraphy within the first five post-operative days.

Since the first post-operative day, we prescribe anti-thrombotic prophylaxis with low molecular weight heparin (subcutaneous enoxaparin) in prophylactic doses together with 100 mg/ day acetylsalicylic acid. Heparin is kept for three weeks, and acetylsalicylic acid, for six weeks.

We carry out daily lab controls so as to keep RBC re-count above 30%. If this figures fall below this parameter, we prescribe transfusion.

### Results

Throughout the assessment period, 17 patients were subject to reconstructive surgery with fibular bone graft. Among them we included six patients (4 males and 2 females) who met the inclusion criteria (Figure 7).

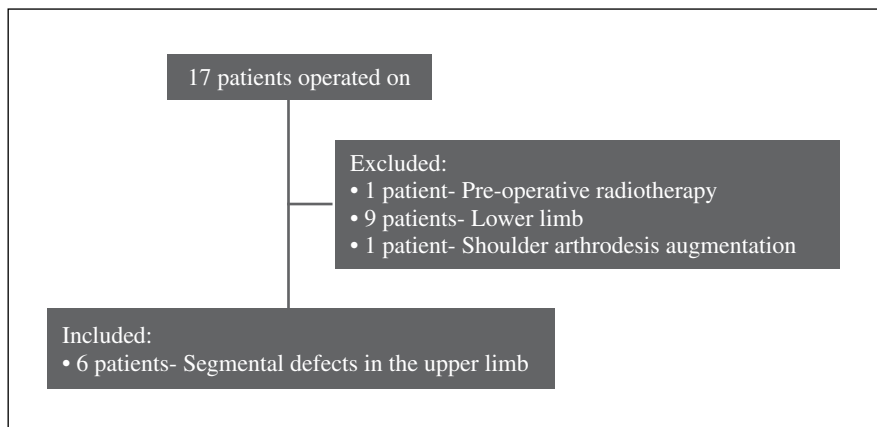
The average patients' age was 47 years old (ranging from 16 to 66). On average, patients had three previous surgeries (ranging from 1 to 4), either for initial traumatism stabilization, for the treatment of an associated infection or for the oncologic resection of the involved segment. The average time that passed between the initial traumatism and the reconstructive surgery was seven years (ranging from 1 to 21). The causes of bone defect were: post-traumatic sequel (non-union) (5 patients) and oncologic disease in one patient with diagnosis of giant

**Table 1.** Demographic data

Case	Sex	Age (years)	Dominant side	Injured side	Smoking	History	Bone	Co-morbidities and associated injuries	Bone defect (cm)	Number of previous surgeries	Span since traumatism/ first surgery to reconstruction (years)	Previous infection
1	M	50	Right	Left	No	Multiple trauma. Humeral fracture	Humerus	Homolateral Monteggia fracture. Depression	15	3	2	Yes
2	F	63	Right	Right	No	Multiple trauma. Ulnar non-union	Ulna	Contra-lateral C5-T1 palsy Chronic dislocation of homlateral radial head	13.5	3	21	Yes
3	M	16	Right	Right	No	Forearm fracture. Right radial non-union	Radius	-	6	1	4	No
4	M	51	Right	Left	Yes	Multiple trauma. Left humeral non-union	Humerus	Contra-lateral olecranon fracture. Cranioencephalic trauma	11	2	11	Yes
5	M	37	Right	Right	No	Ulnar GCT	Radius and ulna	-	9	4	3	No
6	F	66	Right	Left	No	Closed humeral fracture	Humerus	Parkinson's Disease	6	4	1	Yes

M = male, F = female, GCT = Giant cells tumor.

**Figure 7.** Flaw diagram of the patients operated on between 2011 and 2016 with vascularized fibular bone graft.



cells tumor. The bone segments involved were the humerus (3 cases), the radius (1 case), the ulna (1 case) and the radius plus the ulna (1 case). The average bone defect was 10 cm (ranging from 6 to 15) (Table 1) In Table 2 we describe the type of suture we used, the stitches given and the receptor blood vessels. In five cases we carried out a fasciocutaneous flap and, in one case, we did not. Patients remained admitted nine days, on average (ranging from 4 to 17). Five of them received transfusion. On average, we administered 14 transfusions (ranging from 1 to 5)—eight were intra-operative and the rest of them were given immediately after the surgery (Table 3).

In all cases we used locking plates as the fixation method for the graft (5 bridge plate cases) (Table 3). The average follow-up was 17 months (ranging from 5 to 40). We got bone consolidation in all the patients, confirmed by X-ray. The average time since the surgery until bone consolidation was 16.8 weeks (ranging from 8 to 22). Post-operative mobility is shown in Table 4 (Figures 8-12).

Two patients had post-operative complications. One suffered exposure of the osteosynthesis material in the elbow; therefore, the patient required a brachioradialis muscle flap. Another one showed loosening of the osteo-

**Table 2.** Receptor blood vessels and microsurgery suture

Case	Bone	Suture	Suture type	Receptor artery	Arterial anastomoses	Receptor vein	Venous anastomoses
1	Humerus	10-0 Nylon	Separate stitches	Deep brachial artery	Término-terminal	Humeral vein	Término-lateral
2	Ulna	9-0 Nylon	Continuous stitches	Ulnar artery	Término-lateral	Forearm superficial vein Ulnar artery satellite vein	Término-terminal
3	Radius	9-0 Nylon	Separate stitches	Radial artery	Término-lateral	Forearm superficial vein	Término-terminal
4	Humerus	9-0 Nylon	Separate stitches	Humeral artery	Término-lateral	Humeral vein	Término-lateral
5	Ulna	10-0 Nylon	Continuous stitches	Ulnar artery	Término-lateral	Ulnar artery satellite vein	Término-terminal
6	Humerus	9-0 Nylon	Separate stitches	Brachial artery	Término-lateral	Brachial artery satellite vein	Término-terminal

**Table 3. Results**

Patient	Surgery duration (min)	Surgical teams	Trans-fusions	Admission amount of time (days)	Bone consolidation	Time until bone consolidation (weeks)	Osteosynthesis	Cutaneous flap	Seguimiento (meses)	Complicaciones
1	435	2	2 RBC Units 2 PU	9	Yes	16	Locking bridge plate (4.5 mm LCP)	Yes	5	No
2	420	1	3 RBC Units	17	Yes	18	Locking bridge plate (3.5 mm LCP)	Yes	14	Osteosynthesis exposure at proximal level. It required brachioradialis muscle flap
3	450	2	1 RBC Unit	7	Yes	8	Locking bridge plate (3.5 mm LCP)	No	18	No
4	414	2	-	4	Yes	17	Locking bridge plate (4.5 mm LCP) proximally modeled as screw-plate	Yes	40	No
5	375	1	1 RBC Unit	5	Yes	20	3.5 mm proximal locking plate and two distal 2.4mm plates	Yes	16.4	Loosening of proximal osteosynthesis. Osteosynthesis revision surgery
6	390	2	5 RBC Units	13	Yes	22	Double distal humerus anatomic plate with parallel configuration	Yes	8	No

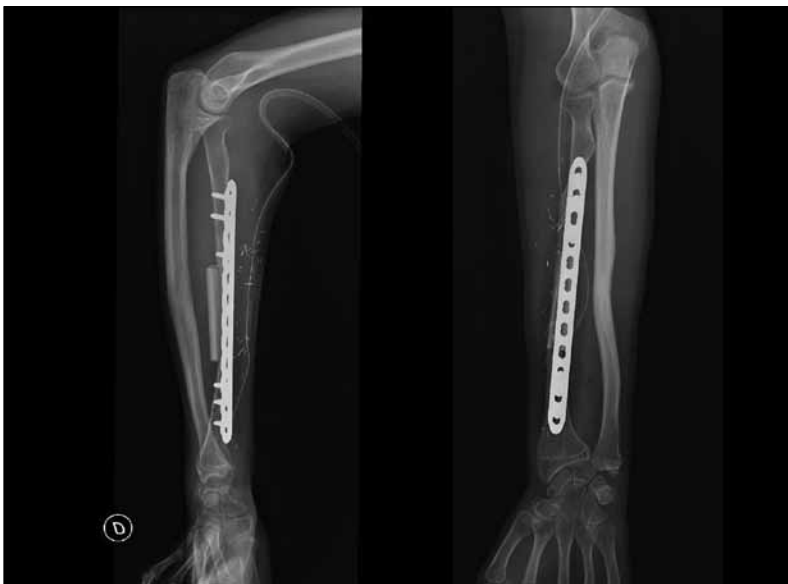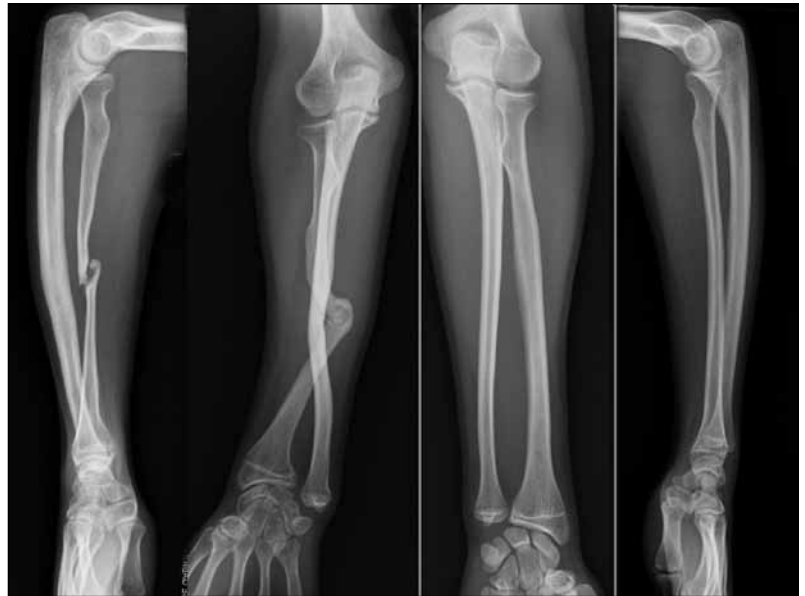RBC = Red blood cells, PU = Plasma units, LCP = locking compression plate.

**Table 4. Post-operative mobility**

Patient	Shoulder		Elbow		Forearm		Wrist	
	Flexion	Abduction	Flexion	Extension	Pronation	Supination	Flexion	Extension
1	170	120	120	40	-	-	-	-
2	-	-	146	16	20	60	60	70
3	-	-	150	0	50	76	70	70
4	60	68	120	8	-	-	-	-
5	-	-	145	0	0	0	0	0
6	130	90	125	45	-	-	-	-

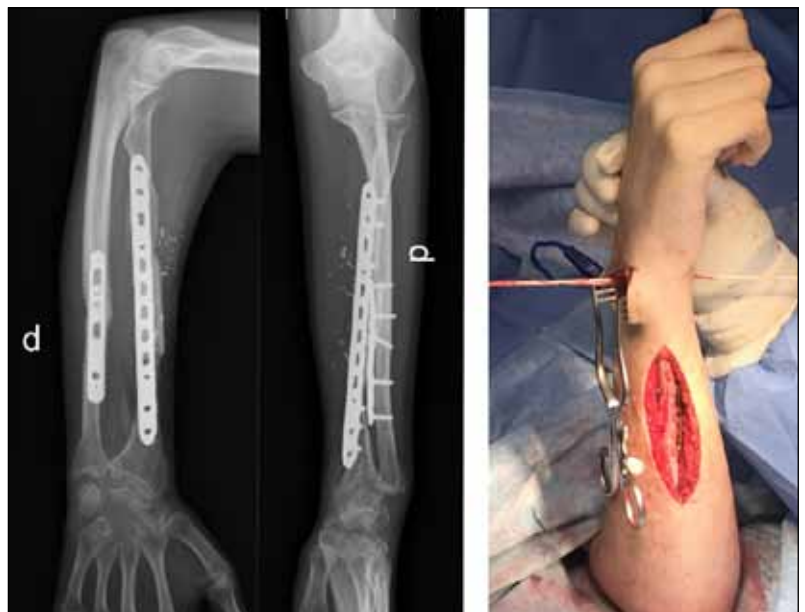
All figures are expressed in degrees.

**Figure 8.** X-rays comparing the affected with the healthy side in a patient with radial diaphysis non-union. There is radial shortening with lower radio-ulnar incongruence.



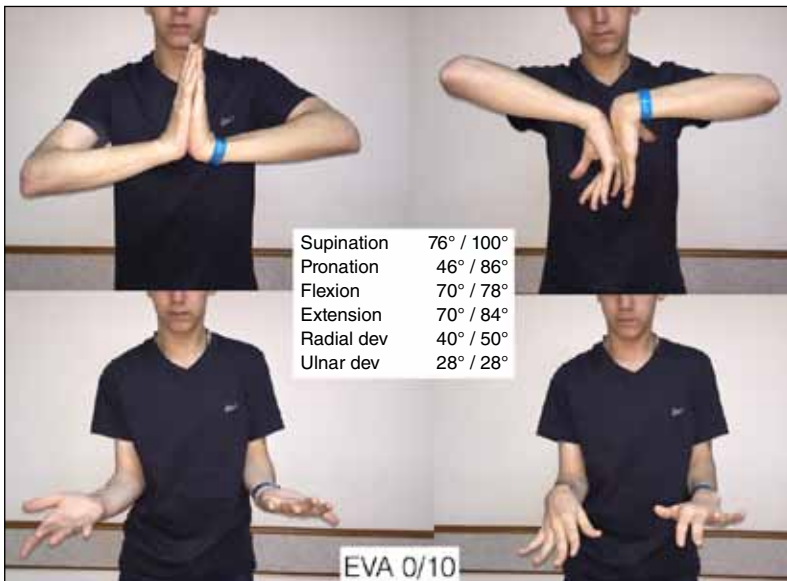
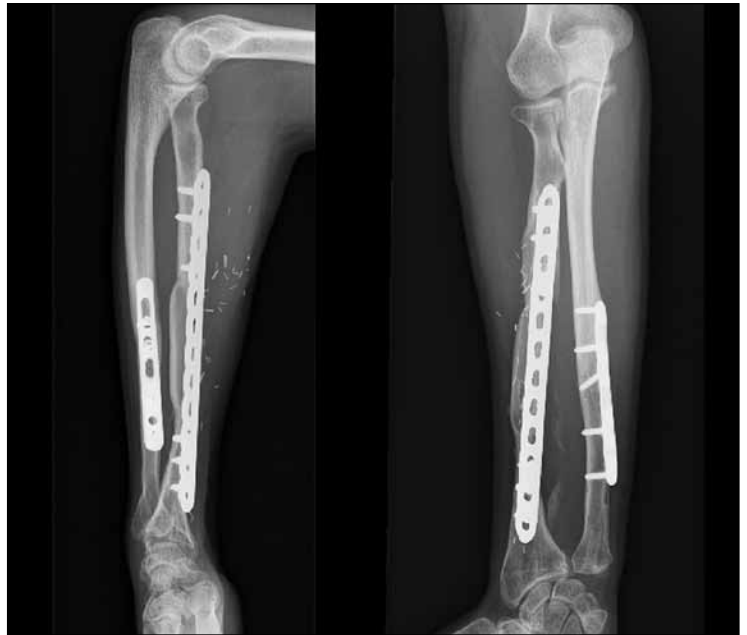
**Figure 9.** Post-operative X-ray showing the reconstruction of a radial segmental defect with vascularized fibular graft. Restitution of radius length was incomplete.

**Figure 10.** Three months after the surgery we carried out surgery for distal radio-ulnar stabilization by shortening the ulna and reconstructing the radio-ulnar ligaments using the Adams' technique. (Adams BD, Berger RA. *J Hand Surg Am* 2002;27:243-251).





**Figure 11.** X-rays showing bone consolidation and forearm alignment. ▶



◀ **Figure 12.** Final result 18 months after the surgery.

**Figure 13.** X-rays showing results in a patient with giant cells tumor in distal radius. ▶

**A.** Second recurrence of the giant cells tumor that involves the transplant of not only the radius but also the ulna.

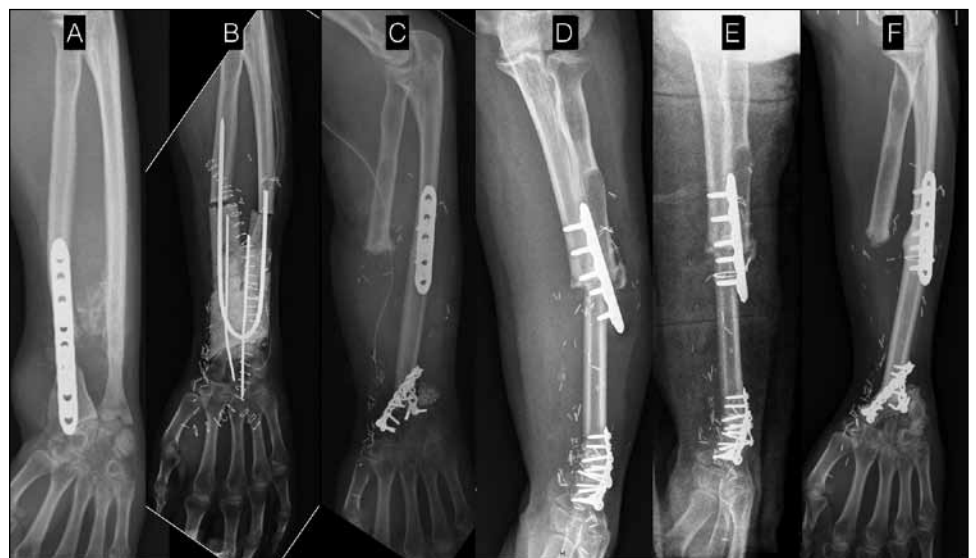
**B.** Wide oncologic resection and insertion of cement spacer.

**C.** Reconstruction with vascularized fibula 17 months after wide resection.

**D.** Osteosynthesis failure two months after the surgery.

**E.** Osteosynthesis revision.

**F.** Final consolidation 16 months after the surgery.



synthesis material two months after the surgery, which required revision (Figure 13). Patients suffered neither complications nor functional sequel in the donor zone (Table 3).

## Discussion

In the limbs, extensive bone defects have been and still are a challenge for surgeons. Vascularized bone grafts have been used as the treatment for reconstruction of defects secondary to traumatism, tumor removal, congenital non-union, osteomyelitis, and bone necrosis.

The fibula is one of the options mostly used for reconstruction in the upper limb, and success stems from this bone characteristics such as vascularization and triangular shape, which resist angular and rotational stress, as well as its resemblance in size to the radius and the ulna, whereas, in the humerus, it fits into the intramedullary canal in the humerus proximal and distal thirds. With respect to the donor zone, there are reports on low complications rates.<sup>9,13</sup> One of the main complications in the donor zone is ankle pain and instability in adults patients; moreover, children run the risk of undergoing ankle valgus deformity.<sup>14,15</sup> Most authors agree on leaving 4 cm of distal fibula; however, we opted for 6 cm above the joint as the graft lower limit to reduce the risk of complications at the ankle joint level.

The reconstruction of bone defects with non-vascularized graft implies migration of cells from a zone with good blood supply in the receptor zone to a bone graft which has almost no cells in its matrix. This is associated with the fact that the osteoblasts are not able to survive in a biological environment with low oxygen tension.<sup>16-18</sup> Enneking et al.<sup>4</sup> report poor results at the time of using non-vascularized bone grafts in large defects (>7cm). Therefore, the use of non-vascularized grafts not only requires time but it is also associated with a high risk of complications, such as bone atrophy, transplant fracture, and consolidation delay.<sup>16,17</sup> Moreover, they are contra-indicated when there is evidence of recurrent infection.<sup>13,19</sup>

The technique of the induced membrane (Masquelet technique)<sup>6</sup> is a reconstruction method for bone defects that requires two surgical times—the first one consists of radical debridement and the insertion of a polymethylmethacrylate cement spacer which creates a membrane around it, that after six or eight weeks is taken off to fill the cavity with autogenous morcellized bone graft from iliac bone or long bones (femur) intramedullary bone. However, this technique requires at least two surgical times and consolidation can take up to a year.<sup>20</sup>

The external fixator with the Ilizarov technique and osteogenic traction with bone transfer is pretty much used in lower limbs, and it has been used in upper limbs for

congenital deformities and special post-traumatic cases of loss of radius and ulna bone stock. For this therapeutic approach the defect cannot go beyond average 3 cm; moreover, the external fixator should be used approximately 4 months to get 4-cm enlargement. The radius and the ulnar bones have low potential of callotaxis and, after immobilization for such a long time, pronation-supination is limited.<sup>5,21</sup>

Since Taylor et al.<sup>2</sup> reported the use of the vascularized fibular graft, this has been the main option for the reconstruction of >6 cm bone defects, and the description of the fasciocutaneous flap widened the application of vascularized fibular graft when the bone defect is associated with coverage defect. The addition of the fasciocutaneous flap allows the surgeon to monitor the bone graft vitality continuously and immediately; therefore, it makes it possible to detect complications at vascular level early.<sup>11</sup>

The vascularized bone graft keeps its bio-structural characteristics, what implies the possibility to strengthen resistance through hypertrophy and early remodeling.<sup>22</sup> The vascularized fibular bone graft has been associated with good results when it comes to forearm reconstruction. It is worth highlighting, however, that contrarily to the arm, where there is only one bone, forearm reconstruction takes not only reconstruction of the length and alignment of the affected bone, but also restitution of congruency and stability to the proximal and distal radio-ulnar joints.

Although the one-bone rescue technique for the forearm allows the surgeon to treat bone defects, it is not free from frequent complications and poor functional results.<sup>23</sup> The main author and surgeon in this series (JGB) indicates the one-bone forearm reconstruction technique in case of impossibility to reconstruct the pronation-supination mechanism or in selected cases, such as that of the patient with the forearm tumor in our series, where the bone defect affects the two forearm bones.

However, humeral defects have been associated with higher complication rates with the use of fibular bone graft.<sup>9,24</sup> In their series of humerus reconstruction, Holtenbeck et al.<sup>3</sup> reported graft fracture rates higher than 20% within the first post-operative year, in relationship with normal physiological stress. De Boer et al.<sup>22</sup> reported post-operative fracture rates of 33% (14 out of 42), whereas Gebert et al. reported 24% of graft fracture (4 humerus and 1 radius).<sup>25</sup> In our series, there were no post-operative secondary fractures. We believe that the absence of this complication was due to the type of osteosynthesis we used. The use of plate and screws gives rigid fixation to the graft, but it can hamper hypertrophy; therefore, we prefer fixation with bridge plate, which in spite of providing the graft with more elastic fixation, contributes to the remodeling and, consequently, it avoids stress fractures.<sup>26</sup>

## Conclusions

Vascularized fibular bone graft is a valid option for the reconstructive surgical treatment of >6cm segmental bone defects in the upper limb. It is associated with high bone consolidation rates, even in the cases with multiple

previous surgeries or in long-term lesions since the initial injury. It is necessary to carry out a meticulous pre-operative planning, especially when an associated fasciocutaneous flap is required. By watching technical details it is possible to avoid complications, especially in the donor zone.

## Bibliography

1. Scaglietti O, Stringa G, Mizzau M. Bone grafting in nonunion of the forearm. *Clin Orthop Relat Res* 1965;43:65-76.
2. Taylor GI, Miller GD, Ham FJ. The free vascularized bone graft. A clinical extension of microvascular techniques. *Plast Reconstr Surg* 1975;55(5):533-544.
3. Hollenbeck ST, Komatsu I, Woo S, Schoeman M, Yang J, Erdmann D, et al. The current role of the vascularized-fibular osteocutaneous graft in the treatment of segmental defects of the upper extremity. *Microsurgery* 2011;31(3):183-189.
4. Enneking WF, Eady JL, Burchardt H. Autogenous cortical bone grafts in the reconstruction of segmental skeletal defects. *J Bone Joint Surg Am* 1980;62(7):1039-1058.
5. Villa A, Paley D, Catagni MA, Bell D, Cattaneo R. Lengthening of the forearm by the Ilizarov technique. *Clin Orthop Relat Res* 1990;(250):125-137.
6. Masquelet AC, Begue T. The concept of induced membrane for reconstruction of long bone defects. *Orthop Clin North Am* 2010;41(1):27-37.
7. Chen ZW, Yan W. The study and clinical application of the osteocutaneous flap of fibula. *Microsurgery* 1983;4(1):11-16.
8. Beppu M, Hanel DP, Johnston GH, Carmo JM, Tsai TM. The osteocutaneous fibula flap: an anatomic study. *J Reconstr Microsurg* 1992;8(3):215-223.
9. Heitmann C, Erdmann D, Levin LS. Treatment of segmental defects of the humerus with an osteoseptocutaneous fibular transplant. *J Bone Joint Surg Am* 2002;84(12):2216-2223.
10. Wood MB. Upper extremity reconstruction by vascularized bone transfers: results and complications. *J Hand Surg Am* 1987;12(3):422-427.
11. Guo QF, Xu ZH, Wen SF, Liu QH, Liu SH, Wang JW, et al. Value of a skin island flap as a postoperative predictor of vascularized fibula graft viability in extensive diaphyseal bone defect reconstruction. *Orthop Traumatol Surg Res* 2012;98(5):576-582.
12. Gilbert A. Free vascularized bone grafts. *Int Surg* 1981;66(1):27-31.
13. Jupiter JB, Gerhard HJ, Guerrero J, Nunley JA, Levin LS. Treatment of segmental defects of the radius with use of the vascularized osteoseptocutaneous fibular autogenous graft. *J Bone Joint Surg Am* 1997;79(4):542-550.
14. Vail TP, Urbaniak JR. Donor-site morbidity with use of vascularized autogenous fibular grafts. *J Bone Joint Surg Am* 1996;78(2):204-211.
15. Gaskill TR, Urbaniak JR, Aldridge JM, 3rd. Free vascularized fibular transfer for femoral head osteonecrosis: donor and graft site morbidity. *J Bone Joint Surg Am* 2009;91(8):1861-1867.
16. Soucacos PN, Dailiana Z, Beris AE, Johnson EO. Vascularised bone grafts for the management of non-union. *Injury* 2006;37 (Suppl 1):S41-S50.
17. Soucacos PN, Johnson EO, Babis G. An update on recent advances in bone regeneration. *Injury* 2008;39(Suppl 2):S1-S4.
18. Soucacos PN, Korompilias AV, Vekris MD, Zoubos A, Beris AE. The free vascularized fibular graft for bridging large skeletal defects of the upper extremity. *Microsurgery* 2011;31(3):190-197.
19. Mattar Junior J, Azze RJ, Ferreira MC, Starck R, Canedo AC. Vascularized fibular graft for management of severe osteomyelitis of the upper extremity. *Microsurgery* 1994;15(1):22-27.
20. Micev AJ, Kalainov DM, Soneru AP. Masquelet technique for treatment of segmental bone loss in the upper extremity. *J Hand Surg Am* 2015;40(3):593-598.
21. Emara KM. Ilizarov technique in management of nonunited fracture of both bones of the forearm. *J Orthop Traumatol* 2002;3(3):177-180.
22. de Boer HH, Wood MB. Bone changes in the vascularised fibular graft. *J Bone Joint Surg Br* 1989;71(3):374-378.
23. Jacoby SM, Bachoura A, Diprinzio EV, Culp RW, Osterman AL. Complications following one-bone forearm surgery for posttraumatic forearm and distal radioulnar joint instability. *J Hand Surg Am* 2013;38(5):976-982 e1.

24. del Pinal F, Innocenti M. Evolving concepts in the management of the bone gap in the upper limb. Long and small defects. *J Plast Reconstr Aesthet Surg* 2007;60(7):776-792.
25. Gebert C, Hillmann A, Schwappach A, Hoffmann C, Harges J, Kleinheinz J, et al. Free vascularized fibular grafting for reconstruction after tumor resection in the upper extremity. *J Surg Oncol* 2006;94(2):114-127.
26. Noaman H. Management of upper limb bone defects using free vascularized osteoseptocutaneous fibular bone graft. *Ann Plast Surg* 2013;71(5):503-509.