

# Dorsal wrist ganglion: Arthroscopic resection with “dry” technique Minimum follow-up of two years

AGUSTIN G. DONNDORFF, GERARDO L. GALLUCCI, PABLO DE CARLI

*Orthopedics Department. Hospital Italiano of Buenos Aires,  
Ciudad Autónoma de Buenos Aires*

Received on March 15th, 2016; accepted after evaluation on May 15th, 2017 • AGUSTÍN G. DONNDORFF, MD • agustin.donndorff@hospitalitaliano.org.ar

## ABSTRACT

**Introduction:** The aim of this study was to report mid-term results in the arthroscopic resection of dorsal ganglia in the wrist using the “dry” technique.

**Materials and Methods:** We evaluated retrospectively 22 patients (22 wrists) with minimal follow-up of 2 years. Eleven females and 11 males who averaged 29 years old (ranging from 18 to 57). We made pre-operative medical evaluations, and also one month after the surgery and at final consultation. We assessed comparative mobility and grip strength, pain and function by the visual analogue scale, QuickDASH and Wrightington’s scores, re-taking of working activities and intra-operative plus post-operative complications. Average follow-up: 42 months (ranging from 24 to 60). We carried out t-test statistical analysis.

**Results:** There were 2 ganglia recurrence. We did not find any other complication. Comparative mobility and grip strength improved significantly—99 and 100%, respectively. Pain and function also improved significantly, as the QuickDASH did. According to the Wrightington’s scale, 18 cases were excellent; 3, good; and one result was bad. Twenty-one out of the 22 patients re-took working activities with no limitations, whereas 20 reported satisfaction with the procedure.

**Conclusion:** Arthroscopic resection using the “dry” technique represents a safe and effective technique for the treatment of dorsal wrist ganglia; it brings about pain relief and both functional and esthetic improvement in most patients by early rehabilitation, with low recurrence incidence.

**Key words:** Arthroscopy; wrist; dorsal ganglion; ganglion resection.

**Level of evidence:** IV

**GANGLIÓN DORSAL DE MUÑECA: RESECCIÓN ARTROSCÓPICA CON TÉCNICA “EN SECO”.  
SEGUIMIENTO MÍNIMO DE DOS AÑOS**

## RESUMEN

**Introducción:** El objetivo de este estudio fue comunicar los resultados a mediano plazo de la resección artroscópica de gangliones dorsales de muñeca utilizando la técnica “en seco”.

**Materiales y Métodos:** Se evaluó retrospectivamente a 22 pacientes (22 muñecas) con un seguimiento mínimo de 2 años. Once mujeres y 11 hombres con una edad promedio de 29 años (rango 18-57). Se realizaron evaluaciones clínicas preoperatoria, al mes de la cirugía y en el último control. Se evaluaron la movilidad y la fuerza de puño comparativas, el dolor

Conflict of interests: The authors have reported none.

y la función según la escala analógica visual, los puntajes funcionales QuickDASH y de Wrightington, el retorno laboral y las complicaciones intraquirúrgicas y posquirúrgicas. Seguimiento promedio: 42 meses (rango 24-60). Se realizó un análisis estadístico mediante la prueba t.

**Resultados:** Hubo 2 recidivas del ganglión. No se registraron otras complicaciones. La movilidad y la fuerza de puño comparativas mejoraron significativamente, 99% y 100%, respectivamente. El dolor y la función también mejoraron significativamente, al igual que el puntaje QuickDASH. Según la escala de Wrightington, 18 casos resultaron excelentes; 3, buenos, y uno fue malo. Veintiuno de los 22 pacientes retornaron a sus tareas laborales sin limitaciones, 20 refirieron estar satisfechos con el resultado.

**Conclusión:** La resección artroscópica utilizando la técnica “en seco” representa una alternativa segura y eficaz para el tratamiento de los gangliones dorsales de muñeca, logra aliviar el dolor, y una mejoría funcional y estética en la mayoría de los pacientes mediante una rehabilitación temprana, con una baja incidencia de recidiva.

**Palabras clave:** Artroscopia; muñeca; ganglión dorsal; resección ganglionar.

**Nivel de Evidencia:** IV

## Introduction

Wrist ganglia represent the most frequent benign tumors in the hand (60-70%).<sup>1</sup> Sixty percent of them are located on the back of wrist,<sup>2</sup> and they are more frequently seen in young women, between 20 and 50 years old.<sup>3</sup> However, although they are common conditions in the day-to-day medical praxis, their pathophysiology and treatment are still controversial.

Conservative therapeutic alternatives include from mere observation to suction puncture with or without infiltration with different chemical agents, all of them associated with high recurrence rates that get up to 78%.<sup>4-8</sup> Up till today, surgical resection represents the safest way to avoid recurrence—however, the incidence of wrist ganglia recurrence can oscillate between 1 and 40% anyway.<sup>8-10</sup>

Although open resection is still the traditional surgical method, over the latest years it has been suggested that arthroscopic resection may represent a potentially more favorable alternative, avoiding some complications associated with the open technique, such as joint rigidity or unsightly scars, with less post-operative pain and faster recovery, and similar or even lower recurrence risks.<sup>11-17</sup> On the other hand, by allowing the surgeon visual direct assessment of the whole joint, the arthroscopic technique could make a more controlled ganglion resection possible, thus avoiding the risk of iatrogenic carpal instability due to the injury of the scapho-lunate ligament,<sup>8-19</sup> and detecting plus treating associated injuries.<sup>12-14</sup>

The aim of this study is to describe mid-term results in the arthroscopic resection of dorsal wrist ganglia using the “dry” technique, originally described in our country by Dr. Carlos Zaidenberg and later popularized by Francisco del Pinal.<sup>20,21</sup>

## Materials and Methods

We conducted an observational, descriptive, retrospective case series study. Between 2009 and 2014 we operated on 42 dorsal wrist ganglia by arthroscopic surgery. In

all cases the diagnosis had been confirmed by micro-coil based MRI, detecting the joint origin of the ganglion in the scapho-lunate gap, compulsory requirement for the indication of arthroscopic resection. According to Wong et al., routine X-ray evaluation may not be justified;<sup>22</sup> therefore, we did not take pre-operative X-rays except in one patient suspected of associated triquetrum-hamate instability. We included all the cases with minimal follow-up of two years. Out of the 24 patients that met the inclusion criteria, two were lost to follow-up; therefore, 22 cases (22 wrists in 22 patients) were included for retrospective evaluation.

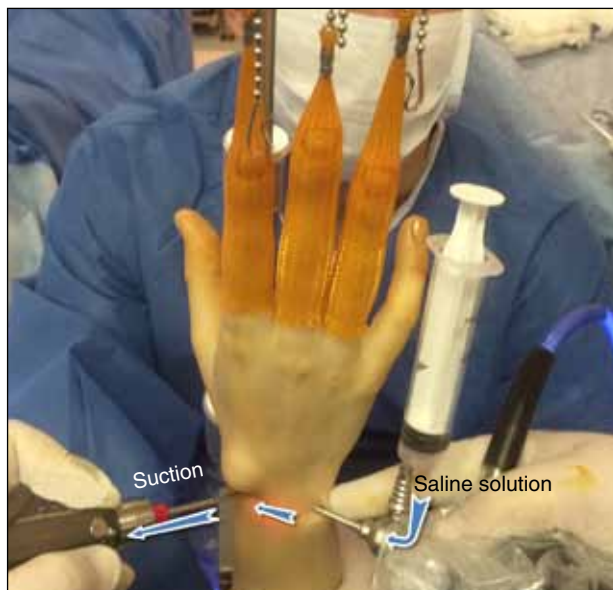
The group was made up of 11 females and 11 males who averaged 29 years old (ranging from 18 to 57). The affected side was the dominant one in 10 cases. Indications for the ganglion surgical resection were as follows: 1) pain (15 cases), 2) esthetic trouble (5 cases), 3) pain and esthetics (2 cases). Only one patient with joint hyperlaxity had also symptomatic triquetrum-hamate instability. Two patients showed ganglion recurrence—they had been operated on at another center by conventional open techniques.

### *Surgical technique*

All the patients were operated on by the same surgeon on outpatient premises using upper limb regional anesthesia and haemostatic cuff. The patient is in supine position with his or her arm on the surgical table and their 90°-flexed elbow hanging on a 3-5 kg-traction tower. For ganglion resection we used a 2.7 mm 30°-angled arthroscope and a 2.5 mm shaver to carry out the “dry” technique. Dry arthroscopy is similar to the traditional “wet” arthroscopic technique; however, there is no need of using fluids so as to visualize the surgical field, what we can do basically by traction. Saline solution is used just sporadically to wash the joint when it is difficult to see due to tissues, blood or the mucinous fluid that the ganglion contains. Using a closed system, the saline solution we inject with a syringe in the arthroscope valve is immediately sucked in the other arthroscopic portal by the shaver, all along washing the joint (Figure 1).

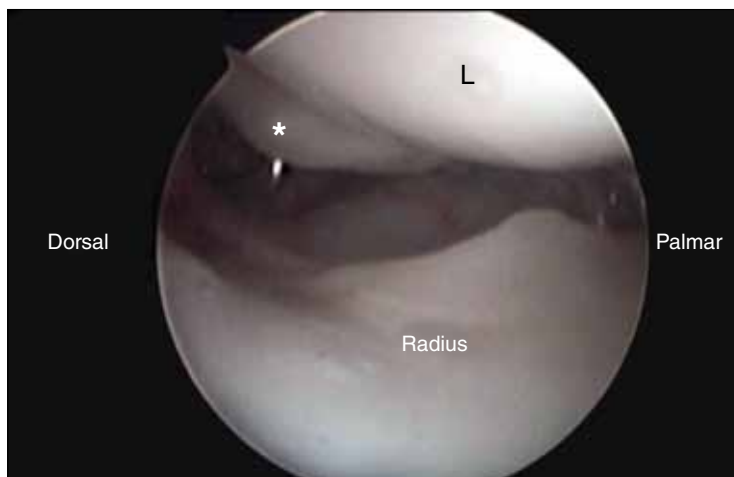
In all cases, we used the radio-carpal portals 6R for visualization and 3-4 for ganglion resection; in most of them we started at the ulnar portal level so as to determine more safely what is the best place to carry out the radial portal by direct visualization without injuring the ganglion, which is located in this area, what will facilitate further identification of the ganglion pedicle. The incisions are transverse, because they are more esthetic.

First it is necessary to check systematically the whole joint so as to identify any associated injury (Figure 2). Up to here in most cases it is not possible to identify the ganglion pedicle because this is covered to a lesser or greater extent by redundant synovial tissues or synovitis (Figure 3). Therefore, the first step is all about conducting dorsal synovectomy with the shaver, being careful not to cause early damage to neither the ganglion nor the dorsal radio-triquetral ligament (Figure 4).

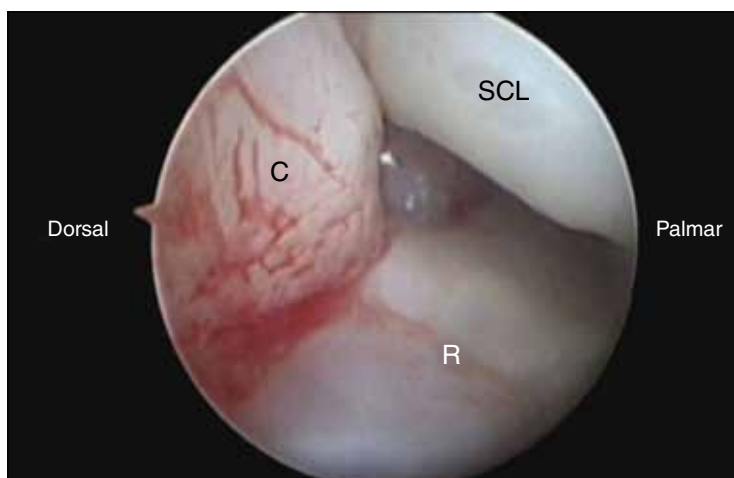


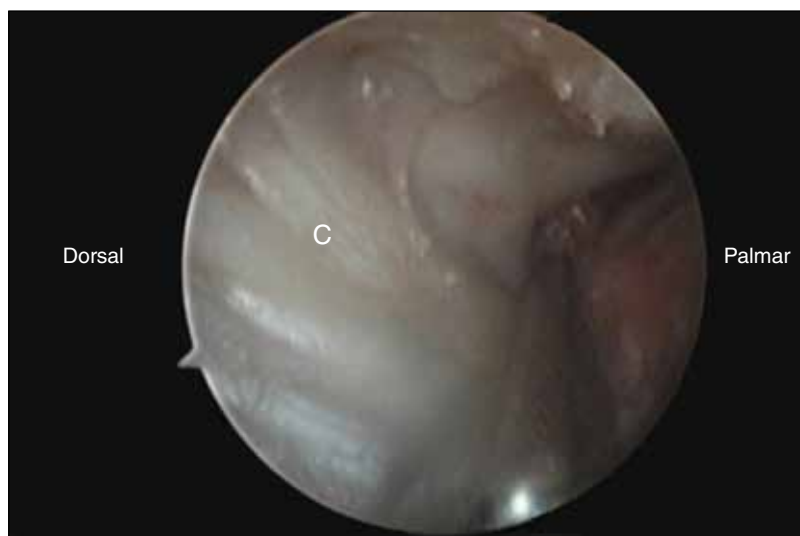▲ **Figure 1.** Using a closed system, the saline solution is injected with a syringe in the arthroscope valve and immediately sucked in the other portal by the shaver, all along washing the joint every time it is required.

► **Figure 2.** Radio-carpal joint seen since the ulnar side with the arthroscope in the 6R arthroscopic portal. We appreciate with the palpator a lax scapho-lunate ligament type I in the Geissler's classification (\*). L= Lunate bone.



► **Figure 3.** With the arthroscope in the 6R portal, we verify the presence of congestive synovial tissue (synovitis) covering the dorsal capsule and hampering the visualization of the ganglion pedicle. SLL= Scapho-lunate ligament, C= Dorsal capsule, R= Radius.





▲ **Figure 4.** Resection of the dorsal synovial tissue with the shaver from the 3-4 arthroscopic portal C= Dorsal capsule.

Once we have carried out synovitis resection, only then, we go on to identify the ganglion pedicle (Figures 5 and 6). Always visualizing the surgical field from the ulnar side, we start pedicle resection, whose origin is in the dorsal part of the scapho-lunate ligament, taking care of preserving it so as not to generate intra-carpal instability. Generally speaking, if the ganglion is considerably large, it is possible to see its viscose contents leaking towards the joint (Figure 7). On the contrary, if it is very small, it will be absorbed by the cannula before detecting it. As most authors affirm, so as to avoid possible recurrences,<sup>12-17,23</sup> it is essential to supplement the pedicle resection with that of an approximately 1cm<sup>2</sup> area from the surrounding dorsal capsule and its connections with the scapho-lunate ligament, especially if it has not been possible to identify the pedicle (Figure 8). In four cases in which there was too distal a ganglion it was necessary to supplement the radio-carpal portals with mid-carpal portals to assure total ganglion resection. Once we have carried out ganglion resection, we palpate the back of the wrist to make sure that the contents have been totally evacuated. With the dry technique this is easier because we avoid the saline solution leaking that characterizes the conventional technique (Figure 9).

Finally we close the arthroscopic portals with one 5/0 nylon simple stitch in each and apply a palmar-forearm bandage, which we take off 2-7 days after the surgery to initiate a rehab program (Figure 10). All the patients started occupational therapy before the 10<sup>th</sup> post-operative day.

The average follow-up was 42 months (ranging from 24 to 60). The pre-operative data were taken from the medical history, and physical examination was conduct-

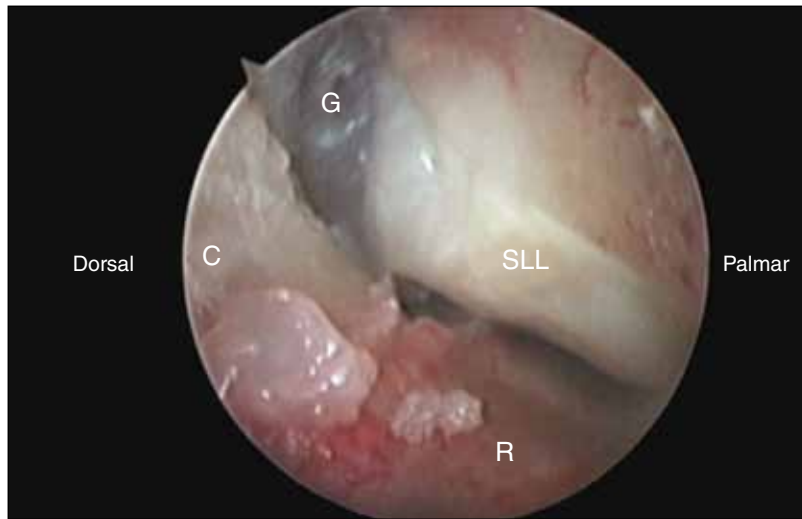
ed at each patient's first assessment consultation. Medical evaluation was made one month after the surgery and at last consultation. It was systematically carried out by the same surgeon and included objective parameters: comparative wrist mobility and grip strength; and subjective parameters: pain and function by the visual analogue scale, QuickDASH and Wrightington's functional scores, the possibility of coming back to working activities and the patient's degree of satisfaction. Moreover, we evaluated intra-operative and post-operative complications, and also ganglion recurrence by physical examination.

### **Statistics Analysis**

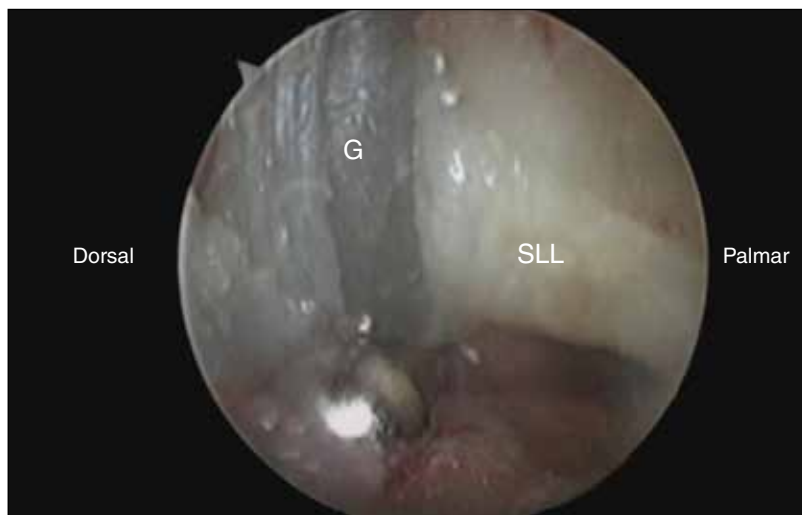For the statistics analysis of the results we used the Student's t test so as to determine whether or not there were significant statistical differences in the diverse variables that were studied at the three times of evaluation. We considered  $p \leq 0.05$  as a significant value.

### **Results**

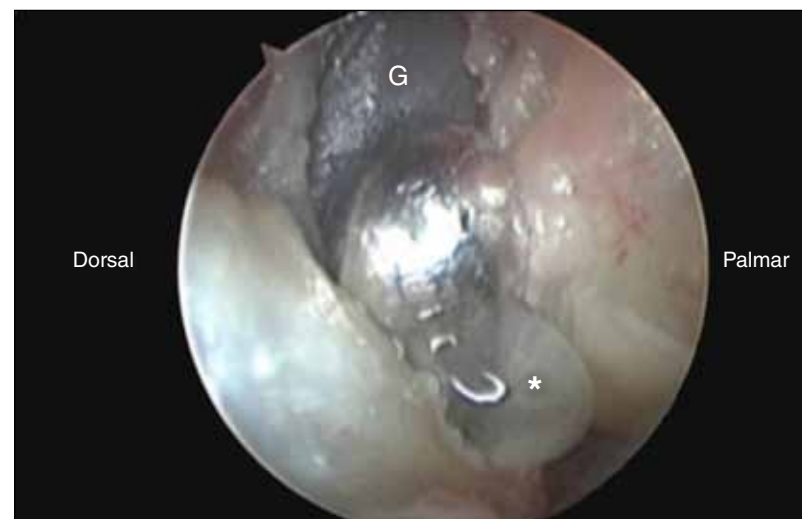There were two cases of ganglion recurrence; one was in a 22-year old female with a very large ganglion in her non-dominant wrist, whose consultation reason was intense pain and who did with bad functional results; up to the time of conducting this study, she did not agree to a new surgery. The other case, a 21 year-old male with a hidden ganglion in his dominant wrist who had consulted for pain, in spite of good functional results reported working limitations. He underwent arthroscopic surgery with good final results.



▲ **Figure 5.** Once dorsal synovectomy is carried out, what comes is the identification of the ganglion pedicle (G) in its origin, in the scapho-lunate ligament (SLL). C= Dorsal capsule. R= Radius.

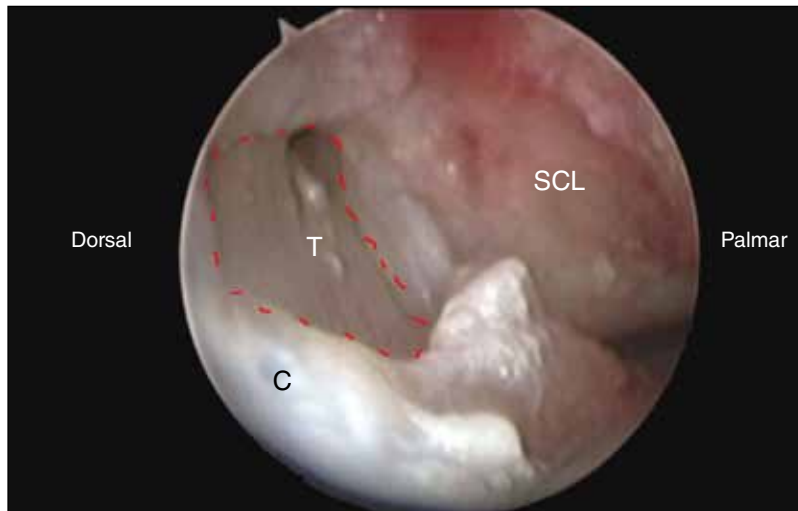


▲ **Figure 6.** Focused visualization of the ganglion pedicle (G). SLL= Scapho-lunate ligament.

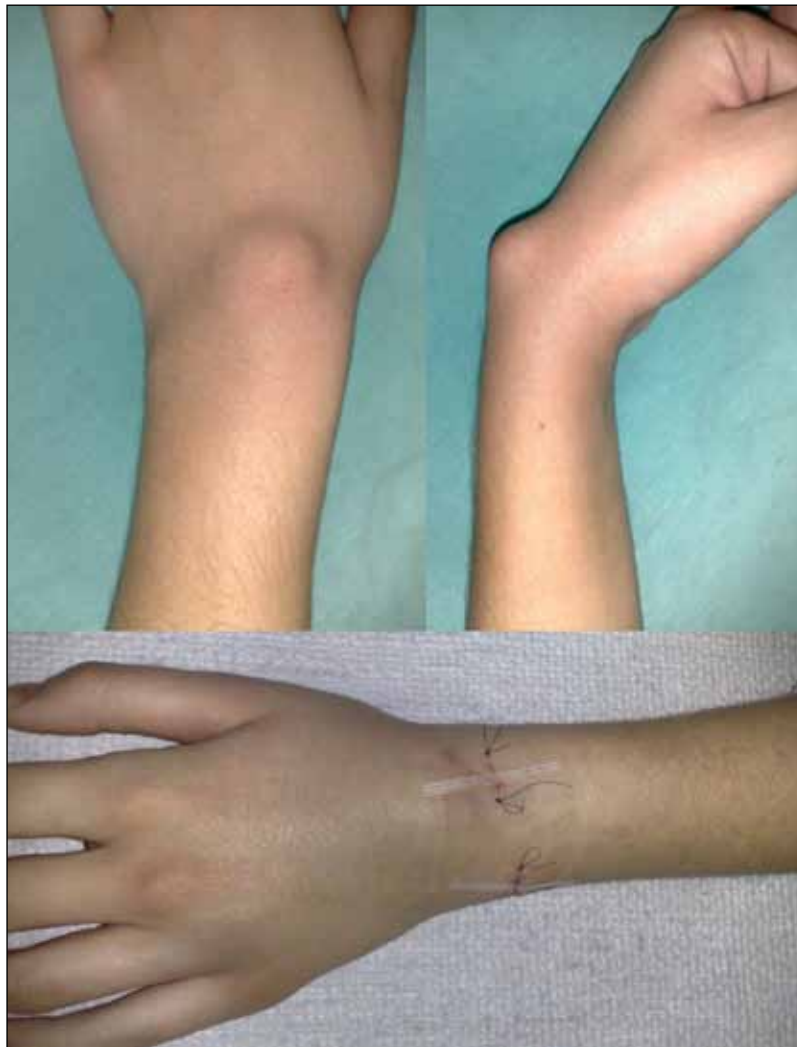

▲ **Figure 7.** Ganglion leaking during the pedicle resection (\*). G= Ganglion.

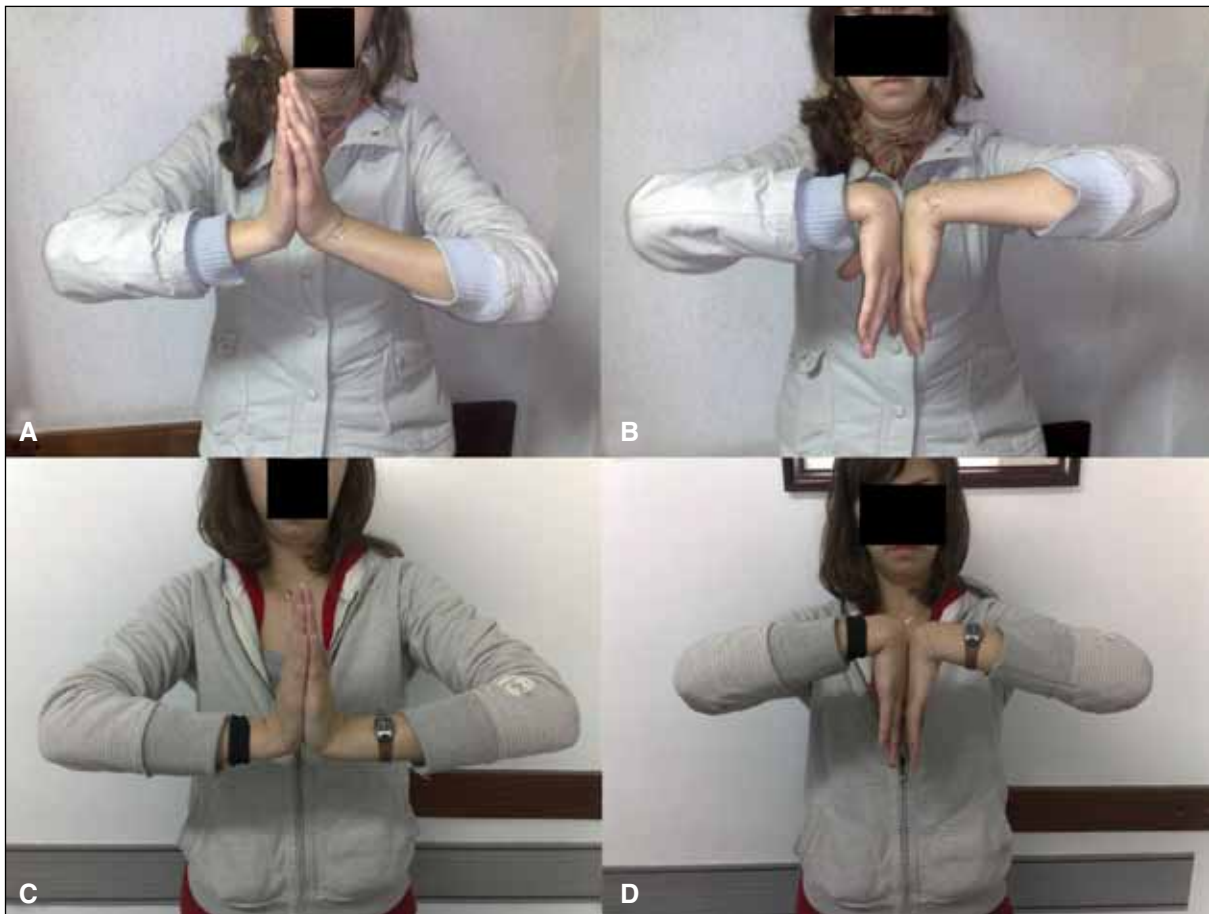



▲ **Figure 8.** Dorsal capsulectomy in an approximately 1cm<sup>2</sup> area (dotted line) right up to the extensor tendons (T), being careful not to injure the dorsal part of the scapho-lunate ligament.



▲ **Figure 9.** Pre- and immediately post-operative images in a 27 year-old female with a dorsal ganglion in her left (non-dominant) wrist. You should note the absence of post-operative edema due to fluids leaking by using the “dry” technique.



▲ **Figure 10.** Post-operative wrist mobility in the same patient in Figure 9. **A and B.** Three days after the surgery she starts mobilization exercises. You should note the presence of the wound stitches (enlarged image). **C and D.** One month after the surgery.

Tables 1 and 2 show the general results verified at the time of medical evaluation.

The average final comparative flexion and extension wrist mobility was 99%. The average final grip strength was 100%. Flexion decreased non-significantly one month after the surgery; at the time of the final evaluation, it has been significantly restored with respect to its pre-operative status. Similarly, wrist extension and grip strength remained with no significant differences one month after the surgery, with significant improvement at the time of the final evaluation. One month after the surgery, one patient showed total improvement of mobility and strength (greater values than those verified pre-operatively and similar values to the ones in the contralateral wrist), 10 cases showed partial improvement (greater values than the ones seen pre-operatively, but lower than those in the contralateral, healthy wrist) and 11 cases showed deterioration (lower than pre-operatively). At final evaluation, 18 patients recovered total mobility and 21, complete strength; all re-took working activities, but for one of patient with ganglion recurrence.

According to the visual analogue scale, average pain and function improved significantly one month after the

surgery, with even more significant improvement at final evaluation. Analyzing these results individually, 18 patients reported pain relief one month after the surgery, and the 22 cases, at final evaluation. With respect to function, 12 cases reported functional improvement one month after the surgery, and the 22 patients reported better function at final evaluation.

The QuickDASH functional score had a tendency to improve one month after the surgery with no statistic differences, but it showed significant improvement at final evaluation. According to the Wrightington's specific wrist functional scale, one month after the surgery 11 cases had excellent results; seven, good results; three, regular results; and one patient had bad results, whereas at final evaluation 18 cases were excellent; three, good; and one case showed bad results.

One month after the surgery, 11 patients were able to re-take working activities with no problem whatsoever; eight, with limitations; and three patients were not able to re-take working activities at all. At final evaluation, all but one patient were able to re-take every working activity with no limitations. Eventually, 20 out of the 22 patients reported satisfaction with final results.

**Table 1.** Medical results: Objective parameters

	Pre-operative	P <sup>1</sup>	Post-operative one month after the surgery	P <sup>2</sup>	Final post-operative	P <sup>3</sup>	Contralateral, healthy wrist	P <sup>4</sup>	%
Flexion	78° (50-94)	0.06	71° (40-100)	<0.001	85° (65-100)	0.002	86° (80-100)	0.2	99
Extension	74° (42-90)	0.2	78° (56-95)	<0.001	84° (70-95)	<0.001	85° (70-95)	0.053	99
Grip strength	27 kg (10-52)	0.9	27 kg (12-48)	<0.001	34 kg (13-53)	<0.001	34 kg (18-46)	0.5	100

P<sup>1</sup> = Differences between the pre- and post-operative results one month after the surgery

P<sup>2</sup> = Differences between the post-operative results one month after the surgery and at final evaluation

P<sup>3</sup> = Differences between the pre-operative and the final post-operative results

P<sup>4</sup> = Differences between final results and the contralateral, healthy wrist

**Table 2.** Medical results: Subjective parameters

	Pre-operative	P <sup>1</sup>	Post-operative one month after the surgery	P <sup>2</sup>	Final post-operative	P <sup>3</sup>
Pain* <sup>1</sup>	6 (1-10)	<0.001	3 (0-8)	0.002	1 (0-8)	<0.001
Function* <sup>2</sup>	6 (2-10)	0.03	7 (2-10)	<0.001	9 (5-10)	<0.001
QuickDASH* <sup>3</sup>	28 (1-84)	0.07	18 (0-77)	0.01	5 (0-58)	<0.001

P<sup>1</sup> = Differences between the pre- and post-operative results one month after the surgery

P<sup>2</sup> = Differences between the post-operative results one month after the surgery and at final evaluation

P<sup>3</sup> = Differences between the pre-operative and the final post-operative results

\*<sup>1</sup> = Results in the visual analogue scale: 0 = without pain, 10 = maximal pain.

\*<sup>2</sup> = Results in the visual analogue scale: 0 = total dysfunction, 10 = maximal function.

\*<sup>3</sup> = Score: 0 = maximal function, 100 = total dysfunction.

There were neither intra-operative nor post-operative complications, except for ganglia recurrence.

### ***Intra-operative findings***

We were able to identify the ganglion pedicle in 14 out of the 22 cases. With respect to the scapho-lunate ligament, in 12 cases we found a lax ligament (Geissler's instability grade 1), which was not treated. Another patient had a perforation in the proximal membranous part of the ligament, which was treated by arthroscopic debridement. The patient who also suffered an associated symptomatic triquetrum-hamate instability was treated in the same arthroscopic procedure by electro-thermic shortening of the palmar arcuate ligament.

In another case, we detected as a finding a chondral lesion on the dorsal surface of the distal radius lunate fossa. It could not be determined how this lesion contributed to the pre-operative severe pain the patient experienced, and it was treated by multiple bone perforations carried out by the same arthroscopic approach, and a metaphyseal bone blockage performed by an accessory dorsal mini-approach.

## **Discussion**

Wrist ganglia represent one of the most problematic lesions in minor surgery in the upper limb, and even today there is controversy about their pathophysiology and treatment.

One of the main problems with the treatment is recurrence, independently of the therapeutic alternative that has been chosen. In this sense, up till now surgical resection has given more favorable results than conservative methods have. According to the diverse series of isolated cases that have been published, the incidence of recurrence after arthroscopic resection is 0-10%, 11-17% below that reported after traditional open surgery (8-40%).<sup>8-10%</sup> However, in a randomized prospective study (level of evidence I), Kang et al. did not find significant differences between both techniques at weeks 4-8 (arthroscopic technique: 2%; open technique: 0%) and after more than one-year follow-up (arthroscopic technique: 11%; open technique: 9%), what suggests that the recurrence risk should not represent a determinant factor at the time of choosing one technique or the other one.<sup>16</sup>



According to our bibliographic revision, there were no series reporting long-term results in patients treated with arthroscopic methods. Only two studies report mid-term results with a minimal two-year follow-up. The Mayo Clinic group, with an average follow-up of 48 months (ranging from 28 to 97),<sup>14</sup> and Gallego and Mathoulin,<sup>24</sup> with an average follow-up of 42 months (ranging from 24 to 74) report good results, with an incidence of recurrence of 9 and 12%, respectively. In a smaller series, but with a very similar mid-term follow-up and contrarily to them, using a dry technique our incidence of recurrence was 9%. Coinciding with other authors, we believe that there are two key aspects to avoid recurrence: 1) to remove the ganglion pedicle in its origin over the scapho-lunate ligament together with a large—approximately 1cm x 1cm—part of the dorsal capsule<sup>12-17,23</sup> and 2) not to hesitate about using the mid-carpal portals when the ganglion pedicle is too distal to allow the surgeon complete ganglion resection from the radio-carpal joint.<sup>12,14,17,24,25</sup>

We found no direct relationship between the possibility to visualize the ganglion pedicle with arthroscopy and the risk of recurrence. In the specialized bibliography, the importance of identifying the pedicle is controversial. Some authors back its importance to avoid recurrence.<sup>16,26,27</sup> On the contrary, in their original report, Osterman and Raphael identify it only in two thirds of the cases, with excellent results and no recurrence, independently of this finding.<sup>12</sup> Other authors report an even lower incidence of pedicle identification, between 9 and 30%, but also with good results and a similar recurrence risk.<sup>13,14,18,25</sup>

The mechanism underlying the onset of symptoms in dorsal ganglia has not been clarified. In our series, pain was the main reason for the indication of surgical resection—17 out the 22 cases suffered pain. All of them, including the patients who suffered recurrence, reported improvement in pain and function at final evaluation. This impact highly favorable on pain in our series is very similar to that seen in other published series. As diverse authors state, at the time of assessing these cases with arthroscopy, the majority shows some degree of radio-carpal dorsal synovitis.<sup>14,15,24,25</sup> The resection of this abnormal synovial tissue is necessary not just for good visualization of the ganglion pedicle. As described by Shi et al., we believe that this synovitis represents, at least in part, the reason for pain in these patients; therefore, synovectomy represents an important stage in the arthroscopic procedure to get significant pain relief.<sup>15</sup>

Taking into account that some of our patients were worried about esthetics, in these cases, the aspects associated with the post-operative scar do not represent a minor issue. In our series, all patients showed total satisfaction with esthetic results. On the other hand, as most of these patients do not show symptoms or have just mild symptoms, it is particularly important to avoid any kind of post-operative limitation in function. In our series, all patients kept mobility and strength similar to those seen pre-operatively

and in the contralateral, healthy wrist, with no remaining pain and normal function at final evaluation.

Although the first authors recommended wrist post-operative immobilization during 1-3 weeks, nowadays, the trend is early mobilization to avoid joint rigidity, especially flexion rigidity. As described by Rizzo et al., in spite of a large dorsal capsulectomy, excessive post-operative immobilization may not be necessary.<sup>14</sup> None of our patients received immobilization, all of them started with the rehab program before the 10<sup>th</sup> post-operative day. As positive data, one month after the surgery, most patients reported pain relief and improvement in function, and re-taking of working activities. However, the fact that only four of the 22 cases showed improvement in wrist mobility or strength throughout this time somehow suggests the importance of explaining clearly to the patients that, even when this is a minimally invasive procedure with high probabilities to recover total mobility and strength, this will require rehabilitation for several weeks.

So far, there is no consensus over the need for mid-carpal portals. Most authors agree on dorsal ganglia originating in the scapho-lunate gap at radio-carpal level. However, sometimes this area is communicated with the mid-carpal space and it is difficult to get this gap from the radio-carpal joint. Kang et al. associate the high recurrence rates seen in their series with the fact that they use the supplementary mid-carpal access in no case.<sup>16</sup> Therefore, diverse authors recommend using the mid-carpal portals routinely.<sup>12,15,24,25,28</sup> In our experience, it was possible to get the dorsal scapho-lunate gap from the radio-carpal joint in all cases after wide synovectomy. Only in four cases with too distal a ganglion did we have to supplement our approach with the mid-carpal portals to assure complete resection of the ganglion pedicle. This way, coinciding with other authors, we believe that the mid-carpal access only would be necessary when there is doubt about the complete resection of the ganglion pedicle or the surgeon suspects that there are associated lesions, especially severe scapho-lunate instability.<sup>13,14,17,29-31</sup>

One of the advantages of the arthroscopic resection is the possibility to explore the joint and thus detect associated lesions. Diverse authors describe an incidence of associated lesions between 11 and 75%, with rupture of the scapho-lunate ligament, the triangular fibrocartilage complex and the luno-triquetral ligament, or chondromalacia in the articular aspects of the radius, the ulna and the triquetrum-hamate joint.<sup>12,15,25,26,32-34</sup> In our series, during the surgery we detected two associated injuries in two out of the 22 cases, which were not seen in the pre-operative medical-radiographic evaluation: a perforation in the scapho-lunate ligament treated with debridement, and chondromalacia in the distal radius lunate fossa treated with multiple bone perforations. Both patients had satisfactory outcomes. A third patient showed, apart from the painful ganglion, symptomatic triquetrum-hamate instability at the time of the pre-operative evaluation; there-

fore, both conditions were treated with arthroscopy. These cases show the importance of arthroscopy to detect and treat associated lesions simultaneously when the surgeon suspects possible implications in the patient's symptoms, i.e. when he or she shows symptoms associated with them. On the contrary, the importance of treating these findings without clear symptomatic correlation is controversial. Osterman<sup>12</sup> and Shi<sup>15</sup> describe that 50 and 38% of their patients, respectively, had some joint condition, and that 98% of them showed good results in spite of not having been treated for them.

Some studies describe the risk of lesions in the scapho-lunate ligament during the open resection of the ganglion, what can cause instability.<sup>19</sup> In this sense, the arthroscopic technique seems to be safer—it allows the surgeon a controlled resection under direct visualization of the joint. However, it is worth mentioning that diverse authors suggest that the ganglion itself is the consequence of previous scapho-lunate instability, based on their finding of high incidence of associated scapho-lunate ligament lesions in some series. In our series, only one patient had a perforation in the dorsal part of the scapho-lunate ligament, but a stable instability and, in 12 cases, the ligament was lax (Geissler's grade 1). It is still being discussed whether or not this is abnormal and the relevance of treating it. Although it makes sense to set out that ligament laxity or instability can contribute to the ganglion formation, nowadays their importance is unclear, since the true incidence of such laxity in the general population is uncertain. Needless to say, in case of detecting serious instability beyond Geissler's grade 1 we believe that ganglia resection should be supplemented with some other procedure, either arthroscopic or open, to treat it.

Last but not least, in all the cases we used "dry" arthroscopic techniques. Unlike what happens in other joints, in the wrist, saline solution irrigation is not absolutely necessary to swell the space, what can mainly be managed by traction. As Pinal states, working with "dry" arthroscopy offers us some advantages such as allowing us to visualize in a more real way the anatomic structures and avoid drawbacks related to saline solution infiltration in the tissues; moreover, the patient can start post-operative rehabilitation immediately.<sup>20,22</sup>

It goes without saying that this study shows all the limitations that characterize retrospective works. Although the series is relatively small, we believe that to have included only the cases with a greater than two-year follow-up allowed us to evaluate mid- and long-term results, especially their main complication—ganglia recurrence. Only two patients were lost to follow-up (8%); therefore, the study comes as a representative sample of our experience. Although the evaluator was the surgeon himself, what somehow can influence objectivity, the fact that the same surgeon has operated on and evaluated all the patients represents, in turn, this study's strength avoiding other bias factors.

## Conclusions

According to our results, we consider that the arthroscopic resection using the "dry" technique represents a safe and effective alternative for the treatment of dorsal wrist ganglia; it brings about pain relief and both functional and esthetical improvement in most patients by early rehabilitation with low incidence of complications and recurrence.

## Bibliography

1. Bain JJ, Munt J, Turner PC. New advances in wrist arthroscopy. *Arthroscopy* 2008;24(3):355-367.
2. McEvedy BV. The simple ganglion: a review of modes of treatment and an explanation of the frequent failures of surgery. *Lancet* 1954;266(6803):135-136.
3. Angelides AC, Wallace PF. The dorsal ganglion of the wrist: its pathogenesis, gross and microscopic anatomy, and surgical treatment. *J Hand Surg Am* 1976;1(3):228-235.
4. Richman JA, Gelberman RH, Engber WD, Salamon PB, Bean DJ. Ganglions of the wrist and digits: results of treatment by aspiration and cyst wall puncture. *J Hand Surg Am* 1987;12:1041-1043.
5. Stephen AB, Lyons AR, Davis TR. A prospective study of two conservative treatments for ganglia of the wrist. *J Hand Surg Br* 1999;24:104-105.
6. Zubowics VN, Ishii CH. Management of ganglion cysts of the hand by simple aspiration. *J Hand Surg Am* 1987;12:618-620.
7. Varley GW, Needoff M, Davis TR, Clay NR. Conservative management of wrist ganglia. Aspiration versus steroid infiltration. *J Hand Surg Br* 1997;22:636-637.
8. Clay NR, Clement DA. The treatment of dorsal wrist ganglia by radical excision. *J Hand Surg Br* 1988;13:187-191.
9. Dias JJ, Dhukaram V, Kumar P. The natural history of untreated dorsal wrist ganglia and patient reported outcome 6 years after intervention. *J Hand Surg Br* 2007;32:502-508.
10. Faithfull DK, Seeto BG. The simple wrist ganglion—more than a minor surgical procedure? *J Hand Surg Am* 2000;5:138-143.

11. Bienz T, Raphael JS. Arthroscopic resection of the dorsal ganglia of the wrist. *Hand Clin* 1999;15:429-434.
12. Osterman AL, Raphael J. Arthroscopic resection of dorsal ganglión of the wrist. *Hand Clin* 1995;11:7-12.
13. Luchetti R, Badia A, Alfarano M, Orbay J, Indriago I, Mustapha B. Arthroscopic resection of dorsal wrist ganglia and treatment of recurrences. *J Hand Surg Br* 2000;25:38-40.
14. Rizzo M, Berger RA, Steinmann SP, Bishop AT. Arthroscopic resection in the management of dorsal wrist ganglions: results with a minimum 2-years follow-up period. *J Hand Surg Am* 2004;29:59-62.
15. Shih JT, Hung ST, Lee HM, Tan CM. Dorsal ganglion of the wrist: results of treatment by arthroscopic resection. *Hand Surg* 2002;7:1-5.
16. Kang L, Akelman E, Weiss APC. Arthroscopic versus open dorsal ganglión excision: a prospective, randomized comparison of rates of recurrence and of residual pain. *J Hand Surg Am* 2008;33:471-475.
17. Aslani H, Najafi A, Zaaferani Z. Prospective outcomes of arthroscopic treatment of dorsal wrist ganglia. *Orhopedics* 2012;35:e365-e370.
18. Duncan KH, Lewis RC. Scapholunate instability following ganglión cyst excision. *Clin Orthop* 1988;228:250-253.
19. Crawford GP, Taleisnik J. Rotary subluxation of the scaphoid after excision of dorsal carpal ganglion and wrist manipulation—a case report. *J Hand Surg Br* 1983;8:921-925.
20. Del Piñal F. Dry arthroscopy and its applications. *Hand Clin* 2011;27:335-345.
21. Del Piñal F, García-Bernal FJ, Pisani D. Dry arthroscopy of the wrist: surgical technique. *J Hand Surg Am* 2007;32:119-123.
22. Wong AS, Jebson PJJ, Murray PM, Trigg SD. The use of routine wrist radiography is not useful in the evaluation of patients with a ganglion cyst of the wrist. *Hand* 2007;2:117-119.
23. Clembosky G, Perrotto C. Resección artroscópica de gangliones dorsales-Técnica quirúrgica. *Arthroscopia* 2009;16(3):212-216.
24. Gallego S, Mathoulin C. Arthroscopic resection of dorsal wrist ganglia: 114 cases with a minimum follow-up of 2 years. *Arthroscopy* 2010;26:1675-1682.
25. Edward SG, Johansen JA. Prospective outcomes and associations of wrist ganglion cysts resected arthroscopically. *J Hand Surg Am* 2009;34:395-400.
26. Ho PC, Griffiths J, Lo WN, Yen CH, Hung LK. Current treatment of ganglion at the wrist. *Hand Surg* 2001;6:49-58.
27. Yao J, Trindade MCD. Color-aided visualization of dorsal wrist ganglion stalks aids in complete arthroscopic excision. *Arthroscopy* 2011;27:425-429.
28. Chassat R, Nourissat G, Chaumeil G, Dumontier C. Arthroscopic treatment of dorsal ganglion cyst at the wrist. About 54 cases. *Chir Main* 2006;25:146-151.
29. Bishop AT, Rizzo M, Berger RA, Steinmann SP. In reply. *J Hand Surg Am* 2004;29:958-959.
30. Slater RR. Arthroscopic ganglionectomy? *J Hand Surg Am* 2004;29:958-959.
31. Chen ACY, Lee WC, Hsu KY, Chan YS, Yuan LJ, Chang CH. Arthroscopic ganglionectomy through an intrafocal cystic portal for wrist ganglia. *Arthroscopy* 2010;26:617-622.
32. Povlsen B, Peckett WR. Arthroscopic findings, in patients with painfull wrist ganglions. *Scand J Plast Reconstr Surg Hand Surg* 2001;35:323-328.
33. Mathoulin C, Hoyos A, Pelaez J. Arthroscopic resection of wrist ganglions. *Hand Surg* 2004;9:159-164.
34. Langner I, Krueger PC, Merk HR, Ekkernkamp A, Zach A. Ganglions of the wrist and associated triangular fibrocartilage lesions: a prospective study in arthroscopically treated patients. *J Hand Surg Am* 2012;37:1561-1567.