

Femoral revision surgery with conical stem of distal fixation

LEANDRO A. SALCEDO ZUNINO, JAVIER NÚÑEZ, MARTÍN M. MANGUPLI,
IGNACIO PIOLI, JOSÉ GÓMEZ, BARTOLOMÉ L. ALLENDE

*Joint Reconstruction Department, Allende Institute of Limb
Reconstructive Surgery, Cordoba*

Received on July 2nd, 2016; accepted after evaluation on October 7th, 2016 • LEANDRO A. SALCEDO ZUNINO, MD • lsalcedozunino@gmail.com

Abstract

Introduction: Proximal bone loss in the revision surgery of the femoral stem is the main challenge surgeons are faced with while carrying out arthroplasty revision. The aim is to get components' stable fixation as well as restoration of the joint kinematics.

Materials and Methods: We evaluated 37 patients (39 femoral revisions), between 2010 and 2014, who received distal fixation non-cemented conical stems (28 modular ones and 11 non-modular ones). Average age was 63.5 years old. We included 18 (48.64%) females and 19 (51.35%) males. We operated on 14 (35.89%) cases of aseptic loosening, 14 (35.89%) infections, 7 (17.94%) peri-prosthetic fractures, 3 (7.69%) stem fractures and one (2.56%) instability. Average follow-up was 42 months (24-74 range).

Results: The average Harris score improved from 37 (10-77 range) before the surgery to 81 (33-96 range) at last follow-up. Four patients (10.2%) showed dislocation, one (2.5%) had deep infection; another one (2.5%), intra-operative fracture; in three (7.6%) patients, there was subsidence and it was necessary to revise 2 (5.1%) femoral implants.

Conclusions: Conical stems have showed satisfactory results in 2 to 6-year follow-up, under diverse circumstances of femoral revision. The procedure takes a simple and reproducible technique, with medical improvement widely published.

Key words: Hip revision; distal fixation stem; femoral revision.

Level of evidence: IV

REVISIÓN FEMORAL CON TALLO CÓNICO DE FIJACIÓN DISTAL

Resumen

Introducción: La pérdida de hueso proximal en la cirugía de revisión del vástago femoral es el principal desafío que enfrenta el cirujano al efectuar una revisión. El objetivo es obtener una fijación estable de los componentes, así como la restauración de la cinemática de la articulación.

Materiales y Métodos: Evaluamos a 37 pacientes (39 revisiones femorales), entre 2010 y 2014, a quienes se les colocaron tallos cónicos no cementados de fijación distal (28 modulares y 11 no modulares). La edad promedio fue 63.5 años. Se incluyó a 18 (48,64%) mujeres y 19 (51,35%) hombres. Se intervinieron 14 (35,89%) casos de aflojamiento aséptico, 14 (35,89%) infecciones, 7 (17,94%) fracturas periprotésicas, 3 (7,69%) fracturas de vástago y una (2,56%) por inestabilidad. El seguimiento medio fue de 42 meses (rango 24-74).

Conflict of interests: The authors have reported none.

Resultados: El puntaje medio de Harris mejoró de 37 (rango 10-77) antes de la operación a 81 (rango 33-96) en el último seguimiento. Cuatro pacientes (10,2%) presentaron luxación, uno (2,5%) tuvo una infección profunda; otro (2,5%), una fractura intraoperatoria; en tres (7,6%) pacientes, se produjo un hundimiento y fue necesario revisar 2 (5,1%) implantes femorales.

Conclusiones: Con el vástago cónico se han logrado resultados satisfactorios en 2-6 años de seguimiento, en varias condiciones de revisión femoral. Requiere de una técnica simple y reproducible, con una mejoría clínica ampliamente publicada.

Palabras clave: Revisión de cadera; tallo de fijación distal; revisión femoral.

Nivel de Evidencia: IV

Introduction

Total hip arthroplasty (THA) has come as a breakthrough for patients with terminal hip osteoarthritis. Indications and the absolute number of primary THAs increase on a yearly basis and so does the number of patients that require revision surgery due to THA failure. The main challenge that the surgeon gets faced with while carrying out arthroplasty revision is to get stable fixation of the components, as well as kinematics restoration of the joint, considering deformity and, above all, the bone stock deficit in this kind of patients.

Bone loss secondary to osteolysis, infection, fracture, or to the need for sacrificing bone tissue during the removal of the previous components has been managed by means of different kinds of techniques and implants.¹⁻⁸ Impaction of bone graft by long cemented stems, mega-prosthesis and proximal femur alloprosthesis are options, although they are technically demanding and are associated with high complication rates; therefore, they are spared for femur bone deficit where distal fixation is not possible.

When it is possible to get diaphyseal fixation, non-cemented revision stems represent a good choice;⁷⁻⁹ they can be cylindrical, conical, monoblock or modular implants, or grooved stems designs.¹⁰⁻¹³ More than 90% of femoral revisions can be dealt with using these kinds of implants (fluted or porous-coated stems). These long non-cemented stems are designed to overlap proximal bone deficit, with minimal distal fixation of 4-7 cm to provide the system with stability. Moreover, there are reports on low failure rates, longer duration (5 to 10 years) and good functional results.¹⁻⁶

Conical stems are designed following the Wagner's stem principles, with conical geometry for distal axial stability and three-point fixation, and longitudinal fluting for rotation stability.¹³⁻¹⁵ Modular designs offer the potential advantages of fitting in and restoring limbs length, offset, version, and proximal bone stocking.¹⁶⁻¹⁸

Objectives

The aim of this study is to report our experience in hip arthroplasty revision with distal fixation conical stem and a minimal follow-up of two years, and to assess the duration of the implants and the Harris hip score, as well as the complications and re-surgeries associated with the use of these stems in complex femoral revisions.

Materials and Methods

Thirty-seven patients were subject to revision surgery (39 femoral revisions) between 2010 and 2014. We used modular (28 cases) and non-modular (11 cases) distal fixation non-cemented conical stems. All the patients had a minimal follow-up of two years, with average follow-up of 42 months (ranging from 24 to 74).

At the time of the surgery patients averaged 63.5 years old (ranging from 30 to 81, standard deviation= 13.3). We included 18 (48.64%) females and 19 (51.35%) males. In 14 revisions (35.89%) the indication was aseptic loosening, and in 14 (35.89%) it was infection (two-staged revision); revisions were performed after peri-prosthetic fracture in seven cases (17.94%), stem fracture in three cases (7.69%) and instability in one case (2.56%). As regards pre-operative X-ray assessment, two patients (5.1%) had a type II Paprosky defect; 15 (38.4%), a type IIIA; 11 (28.2%), a type IIIB; and four (10.2%), a type IV. Among those cases operated on because of peri-prosthetic fracture, four patients (10.2%) were Vancouver B2 and three (7.6%), Vancouver B3. We carried out an arthroplasty first revision in 23 hips (58.97%), a second revision in 14 (35.89%), and a third one in two (5.12%) (Table 1). We used the modular stems ZMR® (Zimmer®), Prevision® (Aesculap®), MPTM (Link®) and Arcos® (Biomet), and the non-modular stems VEGA® (Baumer). We determined the pre-operative and post-operative average Harris score.

Table 1. Baseline demographic and medical data about the patients' cohort

| | |
|---|-------------|
| AVERAGE AGE | |
| Average | 63.5 ± 13.3 |
| Females | 18 (48.64%) |
| Males | 19 (51.35%) |
| INDICATION FOR REVISION | |
| Aseptic loosening | 14 (35.89%) |
| Infection | 14 (35.89%) |
| Peri-prosthetic fracture | 7 (17.94%) |
| Stem fracture | 3 (7.69%) |
| Instability | 1 (2.56%) |
| PREVIOUS THA REVISIONS | |
| First revision | 23 (58.97%) |
| Second revision | 14 (35.89%) |
| Third revision | 2 (5.12%) |
| FEMORAL BONE DEFICIT (PAPROSKY) | |
| Type I | 0 (0%) |
| Type II | 2 (5.1%) |
| Type IIIA | 15 (38.4%) |
| Type IIIB | 11 (28.2%) |
| Type IV | 4 (10.2%) |
| PERI-PROSTHETIC FRACTURE (VANCOUVER) | |
| A | 0 (0%) |
| B1 | 0 (0%) |
| B2 | 4 (10.2%) |
| B3 | 3 (7.6%) |
| C | 0 (0%) |

Surgical approach included extended throcanteric osteotomy in 20 (51.28%) cases. The femoral component removed was a cemented stem in 20 (51.28%) cases, a non-cemented stem in five (12.82%) cases and a cemented spacer with antibiotic in 14 (35.89%) cases. The acetabular cup was revised in 24 (61.53%) of the cases.

Pre-operative planning included the X-ray assessment of the previous implant and that of the femoral bone deficit, which was classified as stated by Della Valle and Paprosky.¹⁹ We always carried out pre-operative planning using the implant template, so as to make sure that distal fixation was adequate; we required minimally 5-cm diaphyseal distal fixation. When such fixation was not possible, we decided to use another surgical technique.^{7,8} All the patients were operated on in lateral position with posterior-lateral surgical approach.

For fixed cemented and non-cemented stems, we usually perform extended throcanteric osteotomy for better visualization and easier implant removal. Osteotomy is extended up to plug level or the distal end of the stem. If this procedure hampers minimal diaphyseal distal fixation of 5 cm, osteotomy should be shorter, prioritizing remaining fixation. We added at least one prophylactic wire loop distal to the osteotomy. We started with progressive rigid conic reamers until we reached fixed and stable resistance at pre-established depth. In the case of modular implants,

after inserting the definite femoral stem and reaching fixation, we used proximal reamers for the implant body, inserting it at proper version and depth as outlined by the stability verified with sample implants.

Immediately after surgery, patients were routinely allowed weight bearing as tolerated with the aid of a walker. The patient who had undergone an intra-operative peri-prosthetic fracture was made to limit weight bearing partially during six weeks until X-ray bone healing. All the patients received antibiotic prophylaxis pre-operatively and immediately after the surgery, and antithrombotic therapy for 30 days.

Post-operative follow-up was at weeks 3, 6 and 12, at month 6 and one year after the surgery; later on, patients were seen once a year. Medical examination included pre-operative and last follow-up Harris hip score. X-ray checkup (anterior-posterior bi-lateral hip X-ray; anterior-posterior and lateral femoral X-ray) was performed before the surgery, immediately afterwards, at week 6, at month 6 and one year after the surgery. The immediately post-operative X-ray series was taken as reference. When early subsidence of the femoral component was inferred, serial X-rays were taken six weeks apart until verifying stem stabilization or deciding to revise the stem instead. Subsidence was determined evaluating the distance between a landmark on the stem and a landmark on the femur. Differences of 5 mm or greater between them verified in the immediately post-operative X-ray and comparatively at last follow-up were considered as stem subsidence.²⁰

For statistical analysis we used the Stata/ MP 14 program (StataCorp, 2015, Stata Statistical Software; Release 14; StataCorp LP, College Station, TX, USA). We used $p < 0.05$ to establish statistical significance.

Results

Average follow-up was 42 months (standard error= 7.12); 25% of the patients were subject to follow-up up to five years after the surgery or more (Table 2). The average Harris score improved from 37 (ranging from 10 to 77) before the surgery to 81 (ranging from 33 to 96) at last follow-up. Before the surgery, 75% of the population showed values <55 and only 5%, >70. After the surgery, this score shows different behavior, with distribution displaced significantly ($p < 0.05$) towards greater figures; this way, the range between these scores (before and after the surgery) was, on average, 44.23 (standard error= 3.36). Table 2 shows that, as from percentile 10, the Harris score following the surgery is already higher than 70 marks (in other words: 90% of the patients showed scores >70). As regards subsidence, the summarized statistical data show homogeneous distribution around approximately 3 mm, because only 5% of the patients studied showed figures greater than 13 mm.

Table 2. Summarized figures of the study and patients' main characteristics

| Variables | Average | SE | P ₁₀ | P ₂₅ | P ₇₅ | P ₉₅ |
|-----------------------------|---------|------|-----------------|-----------------|-----------------|-----------------|
| Follow-up (month) | 42 | 2.82 | 24 | 27 | 59 | 75 |
| Previous Harris score | 37.1 | 3.23 | 16 | 19 | 55 | 70 |
| Post-operative Harris score | 81.26 | 1.97 | 71 | 75 | 89 | 95 |
| Difference between scores | 44.23 | 3.36 | 16 | 24 | 61 | 73 |
| Subsidence (mm) | 2.88 | 0.72 | 0 | 0,3 | 3 | 13 |

P₁₀, P₂₅, P₇₅ y P₉₅ represent, respectively, the 10, 25, 75 and 95 percentile sample figures. SE= standard error.

In our series, the complications rate associated with the use of this kind of implants was 25.3%. Three patients (7.6%) had subsidence >12 mm. Average subsidence for this series was 4.04 mm (ranging from 0 to 17). Two patients, with subsidence = 12 and 13 mm (showing symptoms), were subject to X-ray checkups until verifying stabilization and bone ingrowth, throughout the first year following the surgery. Only one case with subsidence = 17 mm required stem revision for this reason.

Four patients (10.2%) suffered dislocation events. One case received closed setting with no recurrence, but the other three cases required the acetabular component revision with constrained insert (one case) and replacement of the femoral head for a longer one (one case), with no recurrence of the episode either.

One patient (2.5%) received treatment for deep infection. Due to failure in surgical toilet, it was necessary to remove the implants. Other patient (2.5%) suffered a non-displaced and incomplete intra-operative fracture, distal to the stem, which healed with no incidents in X-ray checkups. There were no cases of femoral false passages. With respect to the stems that required revision (5.1%), one patient suffered slow subsidence that reached 17 mm and stem loosening, apart from pain and an increase in the difference between limbs. In this case, the stem was replaced by a longer one that was cemented with impaction bone grafting technique. Another patient suffered deep infection and it was necessary to remove the femoral stem. Implant duration of the femoral revision for any reason by the Kaplan-Meier's analysis was 92.3% (Figure 1). In our series, surgical revision rates for any reason were 12.82%. Implant duration was analyzed considering complications such as dislocation and subsidence > 12 mm. As regards the latter, prosthesis duration showed association with neither patients' sex (p= 0.931) nor patients' age (p=0.361). Moreover, the risk of subsidence >12 mm was not associated with the pre-operative Harris score (p=0.186), although there was a mild indirect range tendency (p=0.094) between the pre-operative and the post-operative Harris score, what suggests that, the greater the range, the lower the probability of showing subsidence

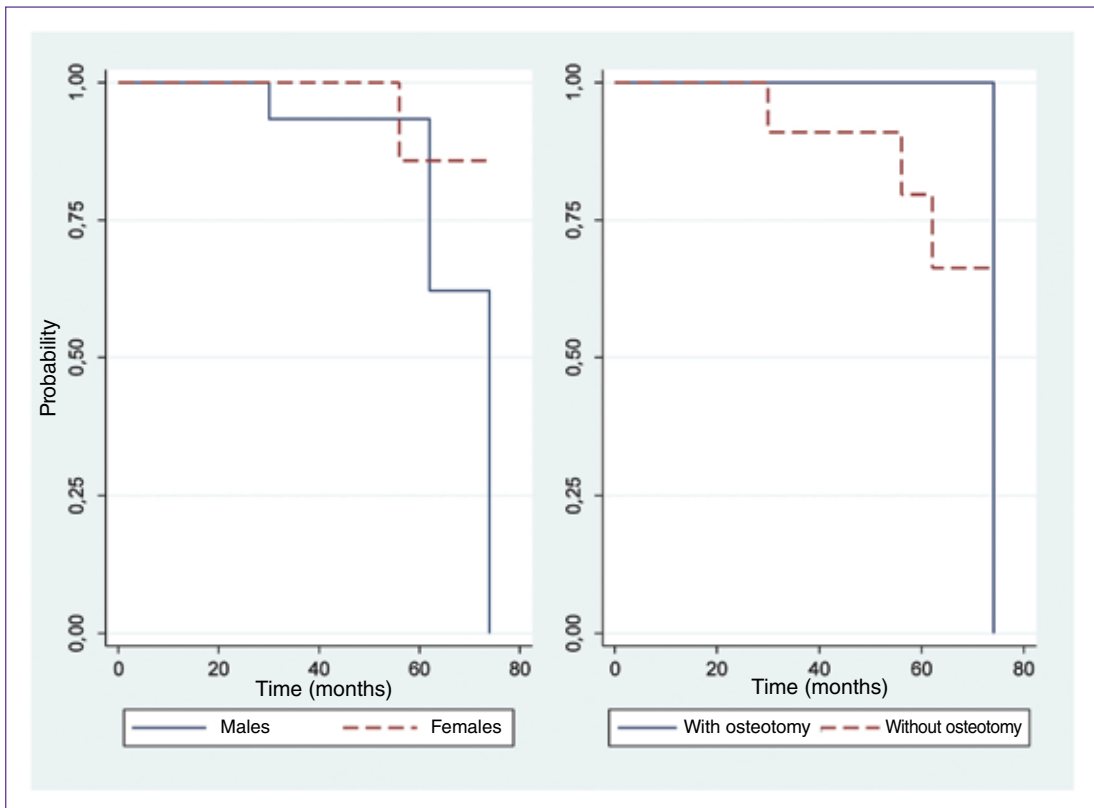
figures <12 mm. Implant duration, analyzed by dislocation standards, followed a similar pattern, i.e. it was associated neither with patients' sex (p=0.414, nor with the pre-operative Harris score (p=0.310), nor with pre-operative and post-operative range differences (p=0.186). Probabilities of implant duration following dislocation showed no association with osteotomy (p=0.316). Figures 1 and 2 show homogeneous behavior in (dislocation) duration curves in the study population with respect to some traits asked for. Finally, the correlation between pre-operative (and post-operative) Harris score and the patients' age was not significant (p=0.919).

Discussion

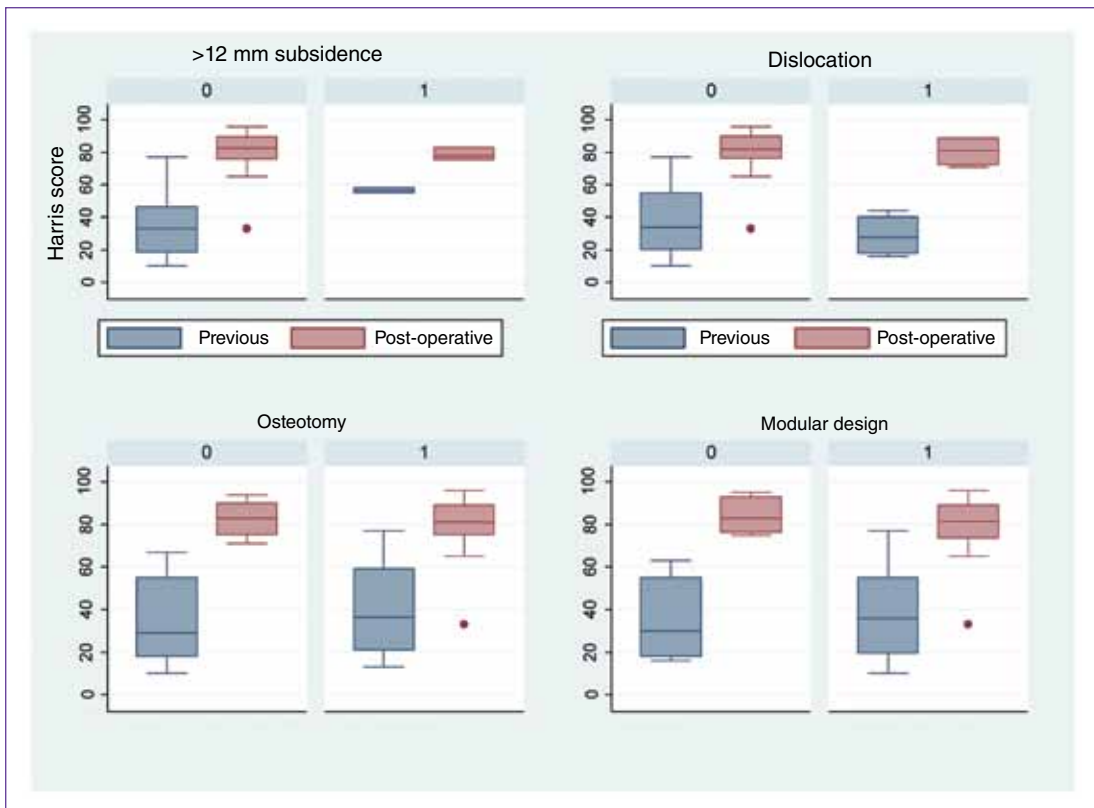
This study reports a current experience in hip revision with distal fixation conical stems and follow-ups between two and six years. It shows high duration of the implants considering functional traits, complications and re-surgeries.

The main challenge the surgeon gets faced with in revision is to get stable fixation in both components. When the proximal femur is significantly distorted by fracture, bone stock deficit or lack of bone tissue following THA, it is necessary to get prosthetic stabilization distal to the area of the weakened bone so as to succeed in revision.¹⁻⁶

There are reports on results with cemented femoral components in failed THA revisions with failures rates = 17%-60% at 2 to 8-year follow-up.²¹⁻²³ Therefore, revision with non-cemented stems has become a better option (Table 3). The main consideration at the time of choosing a conical stem is to make sure that the great limb forces are reliably transmitted. There is a vast contact area between the reamed femoral surface and the conical stem.¹ Due to the stem geometry, which implies greater proximal diameter, the load bearing area by length unit of the proximal femur contact area is greater than the distal one.²⁴ This is why conical stems guarantee high axial stability and the femoral canal can be quite precisely prepared using conic reamers and implementing techniques easily reproducible.



▲ **Figure 1.** Implant duration curves by dislocation standards, by age and osteotomy



▲ **Figure 2.** Box plots for previous (blue) and post-operative (pink) Harris score, by subsidence scale (<12 is used as reference), dislocation, osteotomy, and modular design of the prosthesis (non-modular used as control).

In terms of medical results, this piece of research did not find significant differences as compared to short- and mid-term results already reported (Table 3). Jibodh et al.²⁵ evaluated 54 femoral revisions with modular conical stems at five-year follow-up, with final average Harris score of 81, with no peri-prosthetic infections and five dislocation events. Kang et al.¹³ evaluated 39 revisions with 2 to 5-year follow-up and improvement in Harris score from 47 to 72—similar to our study.

It has been proved that modular stems are more precise at the time of restoring limbs length,²⁶ but proximal modular designs have not reduced dislocation rates as compared to cylindrical or monoblock conical stems. Modular conical stems show dislocation rates between 3% and 19%.^{27,28} In spite of using modular design in all cases, the Revision Total Hip Arthroplasty Study Group²⁹ reported instability rates of 6%, similar to those seen in both cylindrical and conical monoblock implants.^{1, 30} This study shows that patients subject to multiple surgeries, with likely deficit of the abductor system, run a high risk of dislocation, even when hip biomechanics is restored. In this high risk group there are options such as big femoral heads or constrained implants. In this study, 10% of the patients suffered dislocation, which is consistent with what we describe.

Out of the total number of revisions assessed in this study, 36% of the results were good due to deep infection. Although medical history of deep infection can affect negatively the prosthesis duration,^{31,32} in this study group failure rates due to infection proved low. Lakstein et al.¹² evaluated 84 femoral revisions with 2-year follow-up; deep infection rates were 2.4% with satisfactory solution at last follow-up. This study detected only one case (2.5%) of peri-prosthetic infection.

Meek et al. found fracture rates of 18% (including femoral perforation and diaphyseal fracture during stem insertion) in a recent evaluation of 211 consecutive THA revisions carried out with distal fixation stems.³³ Other authors have similar or even higher rates of intra-operative fracture, like 15% with porous-coated implants in revision of hip arthroplasty.^{34,35} Among our patients, there was only one case of intra-operative fracture (during the insertion of the stem).

Subsidence in distal fixation stems is a highly acknowledged complication. With non-modular Wagner-type conical stems, there are reports on >5 mm subsidence in 48%-54% of the patients, with stabilization in high percentages after 3-13 months.^{14,36} Kang et al. reported >5 mm subsidence in more than 15% of their cases;¹³ in Lackstein et al.'s series, only 3% of the subsidence cases was progressive and associated with symptoms, and required revision surgery.³⁷ In diverse studies, subsidence was related to a smaller prosthesis, osteoporosis, insufficient metaphyseal support and extended femoral osteotomy. As in these studies, most of the subsidence cases in our series (7.6%) showed no symptoms and got stabilized within the first year. Only one patient required revision. Our results together with the ones already published^{3,13} suggest that an inadequate selection of the stem diameter and a smaller prosthesis can often cause progressive subsidence.

This study has two limitations that are worth mentioning: patients were not selected randomly, and there is no control group that can be used as reference. This, along with the need of longer follow-up so as to evaluate long-term complications (which are likely in this type of surgeries), could result in vagueness in our inferences and reliability in the evaluation of the implant duration in case of complications or relevant events.

Table 3. Results of published series about non-cemented femoral revision

| Study | Year | Stem type | Number of revisions | Follow-up (years) | Implant duration | Functional score |
|------------------------------------|------|--|---------------------|-------------------|-------------------------|----------------------------|
| Bohm and Bischel ¹ | 2004 | Non-modular conical stem | 129 | 8.1 (5.1-14.1) | 95,20% | Merle d'Aubigné 7,7 → 14,4 |
| Kang et al. ¹³ | 2008 | Modular conical stem | 39 | (2-5) | | Harris 47 → 72 |
| Krishnamurthy et al. ³⁰ | 2007 | Non-modular porous-coated cylindrical stem | 297 | 8.3 (5-13) | 2,4% mechanical failure | Merle d'Aubigné 4,8 → 10,2 |
| Lakstein et al. ³⁷ | 2010 | Modular porous-coated cylindrical stem | 72 | 7 (5-10) | 93,10% | Harris 39 → 72 |
| Amanatullah et al. ²⁸ | 2015 | Modular conical stem | 92 | 6.4 (2-12) | 97% | Harris 38 → 69 |
| Our series | 2016 | Non-modular and modular conical stem | 39 | 3.4 (2-6.16) | 92,30% | Harris 37 → 81 |

Conclusions

Conical femoral stems come as solutions for diverse femoral problems such as aseptic loosening, infection, peri-prosthetic fracture and instability. They require a technique simple and reproducible, with medical improvement widely published. It is necessary to have at

least 5-cm support at distal diaphyseal level. When such support does not seem likely due to distal bone deficit or, exceptionally, when the femoral canal's diameter is greater than the largest conical implant's, alternative therapeutic approaches seem to be necessary, such as impaction of bone graft, alloprosthesis or proximal femur replacement, which is not free from further complications.

Bibliography

1. Bohm P, Bischel O. The use of tapered stems for femoral revision surgery. *Clin Orthop Relat Res* 2004;420:148-159.
2. Engh CA Jr, Hopper RH Jr, Engh CA Sr. Distal ingrowth components. *Clin Orthop Relat Res* 2004;420:135-141.
3. Sculco P K, Abdel MP, Hanssen AD, Lewallen DG. The management of bone loss in revision total knee arthroplasty. *Bone Joint J Br* 2016;981 Suppl A):120-124.
4. McAuley JP, Engh CA Jr. Femoral fixation in the face of considerable bone loss: cylindrical and extensively coated femoral components. *Clin Orthop Relat Res* 2004;429:215-221.
5. Sporer SM, Paprosky WG. Revision total hip arthroplasty: the limits of fully coated stems. *Clin Orthop Relat Res* 2003;417: 203-209.
6. Sporer SM, Paprosky WG. Femoral fixation in the face of considerable bone loss: the use of modular stems. *Clin Orthop Relat Res* 2004;429:227-231.
7. Ling RS, Timperley AJ, Linder L. Histology of cancellus impaction grafting in the femur. *J Bone Joint Surg Br* 1993;75:14-21.
8. Lopreite F, Garabano G, Mana Pastroian D, Dal Lago J, Del Sel H. Utilización de tallos femorales largos cementados asociados a injerto óseo molido e impactado en revisiones de cadera. *Rev Asoc Argent Ortop Traumatol* 2012;77:104-111.
9. Dalury DF, Gonzales RA, Adams MJ. Minimum 5-year results in 96 consecutive hips treated with a tapered titanium stem system. *J Arthroplasty* 2010; 25: 104-7.
10. Leopold SS, Rosenberg AG. Current status of impaction allografting for revision of a femoral component. *Instr Course Lect* 2000;49:111-118.
11. Malkani AL, Settecerci JJ, Sim FH, Chao EY, Wallrichs SL. Long-term results of proximal femoral replacement for nonneoplastic disorders. *J Bone Joint Surg Br* 1995;77: 351-356.
12. Lakstein D, Kosashvili Y, Backstein D, Safir O, Lee P, Gross AE. Revision total hip arthroplasty with a modular tapered stem. *Hip Int* 2010;20(2):136-142.
13. Kang MN, Huddleston JI, Hwang K, Imrie S, Goodman SB. Early outcome of a modular femoral component in revision total hip arthroplasty. *J Arthroplasty* 2008;23:220-225.
14. Grünig R, Morscher E, Ochsner PE. Three-to 7-year results with the uncemented SL femoral revision prosthesis. *Arch Orthop Trauma Surg* 1997;116:187-197.
15. Weber M, Hempfing A, Orlor R, Ganz R. Femoral revision using the Wagner stem: results at 2-9 years. *Int Orthop* 2002; 26:36-39.
16. Cameron HU. Orthopaedic crossfire - Stem modularity is unnecessary in revision total hip arthroplasty: in opposition. *J Arthroplasty* 2003;18(Suppl 1):101-103.
17. Barrack RL. Orthopaedic crossfire - Stem modularity is unnecessary in revision total hip arthroplasty: in the affirmative. *J Arthroplasty* 2003;18(Suppl 1):98-100.
18. Wirtz DC, Heller KD, Holzwarth U, Siebert C, Pitto RP, Zeiler G, et al. A modular femoral implant for uncemented stem revision in THR. *Int Orthop* 2000;24:134-138.
19. Della Valle CJ, Paprosky WG. Classification and an algorithmic approach to the reconstruction of femoral deficiency in revision total hip arthroplasty. *J Bone Joint Surg Am* 2003;85:1-6.
20. Wagner H, Wagner M. Cone prosthesis for the hip joint. *Arch Orthop Trauma Surg* 2000;120:88-95.
21. Hungerford DS, Jones LC. The rationale of cementless revision of cemented arthroplasty failures. *Clin Orthop Relat Res* 1988; 235:12-24.
22. Moreland JR, Moreno MA. Cementless femoral revision arthroplasty of the hip: minimum 5 years follow-up. *Clin Orthop Relat Res* 2001;393:194-201.

23. Mulroy WF, Harris WH. Revision total hip arthroplasty with use of so-called second-generation cementing techniques for aseptic loosening of the femoral component: a fifteen-year average follow-up study. *J Bone Joint Surg Am* 1996;78:325-330.
24. Wagner H, Wagner M. Konische Schaftverankerung Zementfreier Hüftprothesen- Primärimplantation und Prothesenwechsel. En: Morscher EW (ed). *Endoprothetik*, Berlin: Springer-Verlag; 1995:278-288.
25. Jibodh S, Schwarzkopf R, Shawn A, Malchau H. Revision hip arthroplasty with a modular cementless stem: mid-term follow up. *J Arthroplasty* 2013;28(7):1167-1172.
26. Dou Y, Zhou Y, Tang Q, Yang D, Liu J. Leg-length discrepancy after revision hip arthroplasty: are modular stems superior? *J Arthroplasty* 2013;28(4):676-679.
27. Rodriguez JA, Deshmukh AJ, Robinson J, Cornell CN, Rasquinha VJ, Ranawat AS, Ranawat CS. Reproducible fixation with a tapered, fluted, modular, titanium stem in revision hip arthroplasty at 8-15 years follow-up. *J Arthroplasty* 2014;29(9 Suppl): 214-218.
28. Amanatullah DF, Howard JL, Siman H, Trousdale RT, Mabry TM, Berry DJ. Revision total hip arthroplasty in patients with extensive proximal femoral bone loss using a fluted tapered modular femoral component. *Bone Joint J* 2015;97(3):312-317.
29. Revision Total Hip Arthroplasty Study Group. A comparison of modular tapered versus modular cylindrical stems for complex femoral revisions. *J Arthroplasty* 2013;28(8 Suppl):71-73.
30. Krishnamurthy AB, MacDonald SJ, Paprosky WG. 5- to 13-year follow-up study on cementless femoral components in revision surgery. *J Arthroplasty* 1997;12(8):839-847.
31. Mitchell PA, Masri BA, Garbuz DS, Greidanus NV, Duncan CP. Cementless revision for infection following total hip arthroplasty. *Instr Course Lect* 2003;52:323-330.
32. Haddad FS, Muirhead-Allwood SK, Manktelow AR, Bacarase-Hamilton I. Two-stage uncemented revision hip arthroplasty for infection. *J Bone Joint Surg Br* 2000;82(5):689-694.
33. Meek RM, Garbuz DS, Masri BA, Greidanus NV, Duncan CP. Intraoperative fracture of the femur in revision total hip arthroplasty with a diaphyseal fitting stem. *J Bone Joint Surg Am* 2004;86(3):480-485.
34. Chappell JD, Lachiewicz PF. Fracture of the femur in revision hip arthroplasty with a fully porous-coated component. *J Arthroplasty* 2005;20(2):234-238.
35. Zalzal P, Gandhi R, Petruccioli D, Winemaker MJ, de Beer J. Fractures at the tip of long-stem prostheses used for revision hip arthroplasty. *J Arthroplasty* 2003;18(6):741-745.
36. Bohm P, Bischel O. Femoral revision with the Wagner SL revision stem: evaluation of one hundred and twenty-nine revisions followed for a mean of 4.8 years. *J Bone Joint Surg Am* 2001;83:1023-1031.
37. Lakstein D, Backstein D, Safir O, Kosashvili Y, Gross AE. Revision total hip arthroplasty with a porous coated modular stem: 5 to 10 years follow-up. *Clin Orthop Relat Res* 2010;468(5):1310-1315.