

# Anastomosis among iliac vessels and obturators in the retropubic region: study in cadavers

GILBERTO J. CAÇÃO PEREIRA, DAVID NICOLETTI GUMIEIRO, DANIEL INNOCENTI DINHANE, TRAJANO SARDENBERG, PAULO ROBERTO DE ALMEIDA SILVARES, MARCOS FERREIRA MINICUCCI, CARLOS R. PADOVANI

*Botucatu Medical School, Universidade Estadual Paulista, San Pablo, Brasil*

Received on June 9<sup>th</sup>, 2017; accepted after evaluation on March 22<sup>th</sup>, 2018 • GILBERTO J. CAÇÃO PEREIRA, MD • gpereira@fmb.unesp.br 

How to quote this article: Cação Pereira GJ, Nicoletti Gumieiro D, Innocenti Dinhane D, Sardenberg T, de Almeida Silvarés PR, Ferreira Minicucci M, Padovani CR. Anastomosis among iliac vessels and obturators in the retropubic region: study in cadavers. *Rev Assoc Argent Ortop Traumatol* 2018; 83(3): 205-209. doi: 10.15417/issn.1852-7434.2018.83.3.743

## ABSTRACT

**Introduction:** During the surgery of the retropubic region, section or rupture of anastomosis can cause severe bleeding that can go out of control. Our aim was to identify the presence—or absence of arterial or venous anastomosis between iliac and obturator vessels in the retropubic region.

**Materials and Methods:** Thirty cadavers (14 males/16 females; 60% white ones and 40% non-white). After dissection, we verified if there was anastomosis and assessed the distance between the anastomosis and the pubic symphysis.

**Results:** In 13.3% there was no anastomosis whereas in 86.6% there was some kind of anastomosis ( $p < 0.01$ ); venous anastomosis was the most frequent one ( $p < 0.05$ ). The average distance between the anastomosis and the pubic symphysis was 5.7 cm. While comparing sexes, anastomosis and side, 57% of males showed anastomosis at both sides, and 81% and 88% of females had anastomosis at the right and the left side, respectively ( $p < 0.05$ ). At the time of comparing the presence of anastomosis with the side, 70% was at the right side, whereas 73% was at the left side ( $p > 0.05$ ). Seventy-two percent of the white and 67% of the non-white had anastomosis ( $p > 0.05$ ).

**Conclusions:** Anastomosis is more frequently present than absent, and there are no significant differences between sides. On average the distance between the anastomosis and the pubic symphysis is 5.7 cm, and venous anastomosis is significantly more frequent. Anastomosis is significantly more frequent among females. There is no statistical difference in anastomosis between the white and the non-white.

**Key words:** Anastomosis; iliac vessels, obturator vessels; retropubic.

**Level of evidence:** IV

## ANASTOMOSIS ENTRE VASOS ILÍACOS Y OBTURADORES EN LA REGIÓN RETROPÚBICA: ESTUDIO EN CADÁVERES

### RESUMEN

**Introducción:** En las cirugías de la región retropúbica, la sección o ruptura de la anastomosis puede causar graves hemorragias de difícil control. Nuestro objetivo fue verificar la presencia o no de anastomosis arterial o venosa entre los vasos ilíacos y obturadores en la región retropúbica.

**Materiales y Métodos:** Treinta cadáveres (14 hombres/16 mujeres; 60% de raza blanca y 40%, no blanca). Después de la disección, se verificó si había anastomosis y su distancia de la sínfisis púbica.

Conflict of interests: The authors have reported none.

**Resultados:** El 13,3% no tenía comunicación y el 86,6% tenía algún tipo de anastomosis ( $p < 0,01$ ), la anastomosis venosa fue la más frecuente ( $p < 0,05$ ). La distancia promedio entre la anastomosis y la sínfisis púbica fue de 5,7 cm. Al comparar el sexo, la anastomosis y el lado, el 57% de los hombres presentaba anastomosis en ambos lados, y el 81% y 88% de las mujeres la tenían en el lado derecho e izquierdo, respectivamente ( $p < 0,05$ ). Cuando se comparó la presencia de anastomosis con el lado, el 70% estaba en el derecho y el 73%, en el izquierdo ( $p > 0,05$ ). El 72% de los blancos y el 67% de raza no blanca tenían anastomosis ( $p > 0,05$ ).

**Conclusiones:** La presencia de anastomosis es más frecuente que la ausencia y no existe diferencia significativa en cuanto al lado. Está localizada, en promedio, a 5,7 cm de la sínfisis púbica y la venosa es significativamente más frecuente. Es significativamente más frecuente en las mujeres. No hay diferencia estadística en cuanto a la presencia de anastomosis entre la raza blanca y no blanca.

**Palabras clave:** Anastomosis; vasos ilíacos, vasos obturadores; retropública.

**Nivel de Evidencia:** IV

## Introduction

Iliac and obturator vessels can cross the pelvic upper ramus in their respective pathways (external iliac vessels cross it above whereas obturator vessels cross it independently below). However, there is a population percentage that can show some anatomic variations such as venous or arterial anastomosis between such vessels in the retropubic region. Anastomoses between the iliac and the obturator arteries is called “corona mortis” due to the severe bleeding outcomes that its section or rupture can cause.<sup>1-3</sup> We should bear in mind the possibility of this anastomosis at the time of operating on the area, especially in the ilioinguinal approach and the modified Stoppa approach<sup>4,5</sup> used for the osteosynthesis of the fracture of the acetabulum anterior column, because the section or rupture of such anastomotic vessels can cause severe bleeding that can go out of control.

We carried out a study on cadavers with aim of analyzing the presence—or absence of retropubic anastomosis between iliac and obturator vessels.

## Materials and Methods

We dissected 30 fresh cadavers bilaterally (14 males and 16 females who were between 25 and 90) that we had taken consecutively from the cadaver verification section at our Department. Dissections were carried out by the same surgeon during a period of 3 months, in 2010. By bilateral ilioinguinal approach<sup>6</sup> we searched for the iliac vessels that cross the pubis and the obturator vessels that cross the retropubic region.

We looked for the presence—or absence of venous or arterial anastomoses between the iliac or epigastric and the obturator vessels. When there certainly was anastomosis, we assessed the distance (in cm) between this one and the pubic symphysis. We did not take  $< 1$  mm-diameter anastomoses into account.

The association between sex, race and (left or right) side, and the presence—or absence of anastomosis was assessed with the Goodman test<sup>7</sup> for contrasts between binomial proportions. Regarding the type of anastomosis, we used the chi-squared test for samples with equal distribution between the possibilities.<sup>8</sup>

## Results

Four cases (13.3%) did not show anastomosis (Figure 1) whereas 26 (86.6%) had some type of anastomosis (venous, arterial, arterial and venous) (Figure 2). In 17 of them, anastomoses were at both sides and, in nine (34.6%), only at one side. In 16 cases, anastomoses were between iliac and obturator vessels and, in 10, between the lower epigastric (artery or vein) and the obturator.

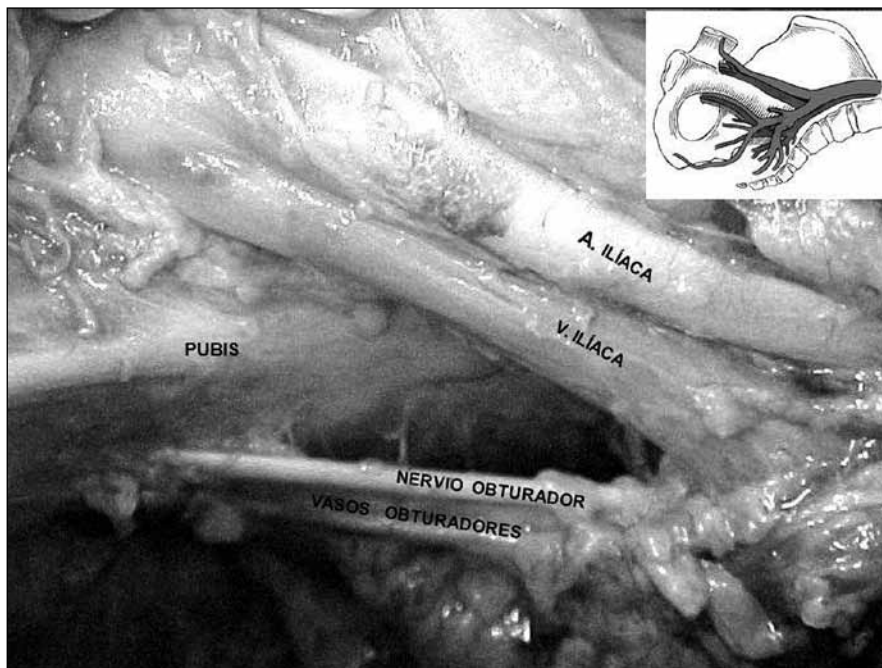
As regards the type of anastomosis between vessels, 54% were exclusively venous anastomoses; 12%, exclusively arterial anastomoses and 34%, arterial and venous anastomoses ( $p < 0.05$ ). The distance between the anastomosis and the pubic symphysis varied between 4.5 and 7.0 cm (average 5.7 cm). Fifty-seven percent of men had anastomoses at both sides, and 81% and 88% of women had anastomoses at the right and the left side, respectively ( $p < 0.05$ ). With respect to the association anastomosis-side, 70% (37% venous, 23% venous plus arterial, 10% arterial) were at the right side whereas 73% (40% venous, 26% venous plus arterial, 7% arterial), at the left side ( $p < 0.05$ ). We verified anastomosis in 72% of white patients and in 67% of non-white patients ( $p < 0.05$ ).

## Discussion

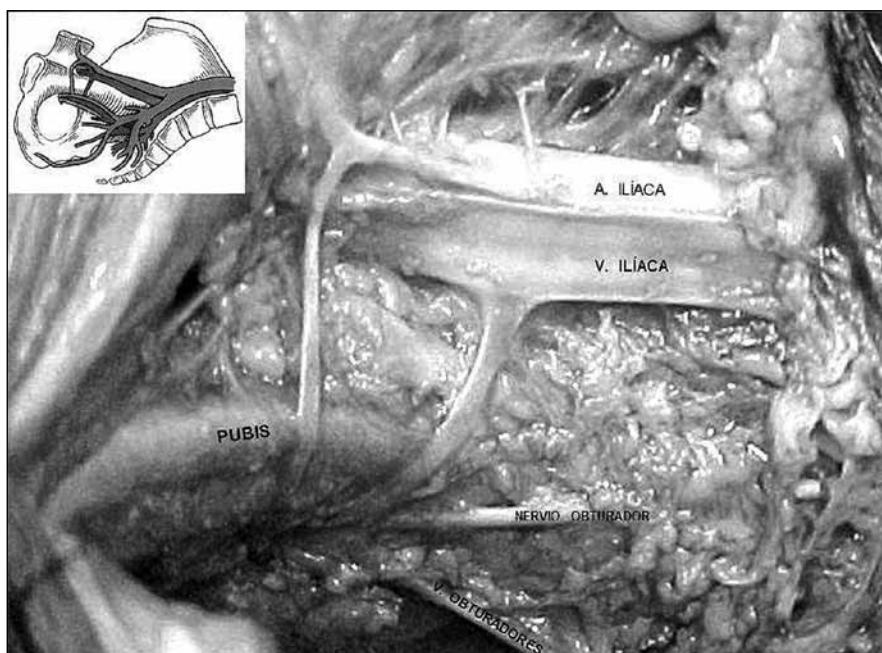
Some individuals can have anastomosis between iliac and obturator vessels in the retropubic region that can be of arterial or of venous profile, or of both.<sup>2</sup> Such arterial (“corona mortis”) or venous anastomosis is especially

significant in the ilioinguinal approach (treatment of acetabulum fracture) and with the use of the modified Stoppa approach,<sup>4,5</sup> because its section or rupture due to traction by the isolated ramus can cause great bleeding due to the difficulty to find the arterial segment that recoils

in the region of the obturator vessels. Therefore, surgical orthopedists and other specialists such as obstetricians, gynecologists and gastroenterologists (while repairing groin hernia) should take this probabilities into account.<sup>9</sup> If the anastomosis is carefully identified, it can be given



▲ **Figure 1.** Intrapelvic view in one case without anastomosis between iliac and obturator vessels. The drawing gives details about the schematic design of the intrapelvic region showing the absence of anastomosis.



▲ **Figure 2.** Intrapelvic view in one case with arterial and venous anastomosis between iliac and obturator vessels. The drawing gives details about the schematic design of the intrapelvic region showing the presence of anastomosis.

prophylactic ligature to avoid such devastating complication.<sup>1,2,10-12</sup>

In our study, in the analysis of a balanced sample between sexes, we found that anastomosis between such vessels is more frequently present than absent, considering small-diameter (>1mm) vessels as well. The vast majority (86%) of cases showed some type of anastomosis (venous, arterial, or venous and arterial anastomosis) at one of both sides, and even bilateral anastomosis was more frequent (65.4%) than unilateral anastomosis (34.6%). Tornetta et al.,<sup>2</sup> at the time of analyzing this type of anastomosis in 25 cadaver hemi-pelvis, found anastomosis in 84% of the sample—and they only worked with 2-mm diameter vessels or wider. Cole and Bolhofner,<sup>13</sup> in their study on the surgical treatment of acetabular fracture by intrapelvic approach, report that anastomosis between external iliac and obturator vessels was a common finding. In a cadaver study, Teague et al.<sup>10</sup> detected such anastomosis in 73% of their cases.

In our study, the most frequent anastomosis was the venous one (54%), followed by venous and arterial, and finally arterial anastomosis, with significant differences. For Tornetta et al.<sup>2</sup> the venous anastomosis was the most frequent one (70%), followed by arterial anastomosis (35%) and finally arterial and venous (20%). Teague et al.<sup>10</sup> report that venous anastomosis is the most frequent one. In a cadaveric study, Sarikcioglu et al.<sup>11</sup> reported that venous anastomosis was more frequent than arterial anastomosis. Barberoglu et al.,<sup>14</sup> in a study on seven cadavers and (subject to endoscopy) patients, report that, in spite of the emphasis on the retropubic anastomosis between the external iliac and the obturator arteries (“corona mortis”), venous anastomosis is much more frequent (96% of the sample). These authors highlight the importance of acknowledging such anatomic feature during laparoscopy and the surgical treatment of groin hernia. At the time of analyzing such report in female cadavers, Drewes et al.<sup>15</sup> detected it in 66.7% of their sample and venous anastomosis was the most frequent one. They state that acknowledging such anatomic variation is essential for surgery at such area. The authors remind the readership of the fact that anastomosis with obturator vessels can come from both iliac vessels and lower epigastric vessels.

In our study we also verified this anatomic feature (from the epigastric) in 38% of the cases with anastomosis. Likewise, Teague et al.<sup>10</sup> affirm that 50% of venous

anastomosis are originated in the epigastric and, in arterial anastomosis, rates were higher. Where anastomosis is located is an important detail to take into account at the time of carrying out a surgical approach in the area, because this will facilitate identification. In our study, the average distance between the anastomosis and the pubic symphysis was 5.7 cm. Karakut et al.<sup>16</sup> found a lower average distance (3.5 cm) and Berberoglu et al.<sup>14</sup> a 4 cm-average distance, but a number of authors report average distances similar to ours—Drewes et al.,<sup>15</sup> Rubel et al.<sup>17</sup> and Tornetta et al.<sup>2</sup> report average distances of 5.4 cm, 6.0 cm and 6.2 cm, respectively. With respect to the relationship between anastomoses and sex, anastomosis was more frequent in women (at both sides) and differences were significant. In an angiographic study on the “corona mortis”, Karakut et al.<sup>16</sup> did not find significant differences in the presence of anastomosis between both sexes. Requarth and Muller,<sup>18</sup> also in an angiographic study on the arterial anastomosis between the lower epigastric and the obturator, did not find significant differences between the female and the male sexes. They highlight that, while treating pelvic ring fractures, it is essential to bear in mind the possibility of this vascular alteration and the great bleeding it can cause if it gets injured.

Anastomosis was more frequent at the left than at the right side, but differences were non-significant. Requarth and Muller<sup>18</sup> also report left arterial anastomosis being more frequent than right arterial anastomosis, with no significant differences.

At the time of correlating race and the presence of anastomosis, we did not find significant differences between the white and the non-white ones. We did not find any article dealing with such parameter.

## Conclusions

Anastomosis between the iliac and the obturator vessels is more frequently present than absent, and the distance between anastomosis and the pubic symphysis is 5.7 cm on average (from 4.5 to 7 cm). There are no significant differences in anastomosis between the right and the left sides. Venous anastomosis is the more frequent, and anastomosis is more frequent among females, both with significant differences. There were no significant differences in anastomosis between the white and the non-white.

## Bibliography

1. Vialle LRG. Um estudo sobre a via de acesso ilioinguinal. *Rev Bras Ortop* 1973;8(1):63-72.
2. Tornetta P, Hochwald N, Levine R. Corona mortis, incidence and location. *Clin Orthop Relat Res* 1996;(329):97-101.
3. Henning P, Brenner B, Brunner K, Zimmermann H. Hemodynamic instability following an avulsion of the corona mortis artery secondary to benign pubic ramus fracture. *J Trauma* 2007;62(6):E14-7.
4. Sagi HC, Afsari A, Dziadosz D. The anterior intra-pelvic (modified Rives-Stoppa) approach for fixation of acetabular fractures. *J Orthop Trauma* 2010;24(5):263-9.
5. Archdeacon MT, Kazemi N, Guy P, Sagi HC. The modified Stoppa approach for acetabular fracture. *J Am Acad Orthop Surg* 2011;(19):170-5.
6. Kellam JP, Tile M. Surgical techniques. En: Tile M. *Fractures of the pelvis and acetabulum*, Baltimore: Williams & Wilkins; 1995:365.
7. Goodman LA. Simultaneous confidence intervals for contrasts among multinomial population. *Ann Math Stat* 1964;35(2): 716-25.
8. Zar JH. *Biostatistical analysis*, 4<sup>th</sup> ed. New Jersey: Prentice Hall; 2009:994.
9. Talalwah WA. A new concept and classification of corona mortis and its clinical significance. *Chin J Traumatol* 2016;(19):251-4.
10. Teague DC, Graney DO, Routt ML Jr. Retropubic vascular hazards of the ilioinguinal exposure: a cadaveric and clinical study. *J Orthop Trauma* 1996;10(3):156-9.
11. Sarikcioglu L, Sindel M, Akyildig F, Gur S. Anastomotic vessel in the retropubic region: corona mortis. *Folia Morphol (Warsz)* 2003;62(3):179-82.
12. Letournel E, Judet R. Surgical approaches to the acetabulum. En: Letournel E, Judet R. *Fractures of the acetabulum*, 2<sup>nd</sup> ed. Berlin: Springer-Verlag; 1993:379-81.
13. Cole J, Bolhofner B. Acetabular fracture fixation via a modified Stoppa limited intrapelvic approach. *Clin Orthop* 1994;305: 112-23.
14. Berberoglu M, Uz A, Ozmen MM, Bozkurt MC, Erkurun C, Taner S, et al. Corona mortis: an anatomic study in seven cadavers and endoscopic study in 28 patients. *Surg Endosc* 2001;15(1): 72-5.
15. Drewes PG, Marinis SL, Schaffer JL, Boreham MK, Corton MM. Vascular anatomy over superior pubic rami in female cadavers. *Am Obstet Gynecol* 2005;193(6):2165-8.
16. Karakut L, Karaca I, Yilmaz E, Burma O, Serin E. Corona mortis: incidence and location. *Arch Orthop Trauma Surg* 2002; 122(3):163-4.
17. Rubel IF, Seligson D, Mudd L, Willinghurst C. Endoscopy for anterior pelvis fixation. *J Orthop Trauma* 2002;16(7):507-14.
18. Requarth AJ, Muller RP. Aberrant obturator artery is a common arterial variant that may be a source of unidentified hemorrhagic in pelvic fracture patients. *J Trauma* 2011;70(2):366-72.