
IOP - Images

Case resolution

JUAN PABLO GHISI, MD
Argus Diagnóstico Médico
Chief of MRI Department, General Acute Care Hospital "Dr. Juan A. Fernández",
Ciudad Autónoma de Buenos Aires

ADRIANA PEMOFF, MD
Chief of the Upper Limb and Microsurgery Team
Chief of Orthopedics Department, General Acute Hospital "Dr. Juan A. Fernández",
Ciudad Autónoma de Buenos Aires

Presentation of the case on page 167.

Diagnosis

Os epilunatum.

Discussion

There are many skeletal variations in the body that include accessory bones, bi-partite bones and bone coalitions. Accessory bones, secondary centers of ossification and sesamoid bones make up the accessory bones in the body.

In the wrist, there are more than 20 accessory ossicles described (Figure 5). They can be on dorsal or palmar position, or inserted between carpal bones.

Most wrist accessory ossicles stem from un-fused secondary centers of ossification and, consequently, they can be considered as development anomalies.

The most frequently detected ossicles in the wrist are the lunula, the os styloideum, the os trapezium secundarium and the hamuli propium.

In general, they are asymptomatic incidental findings in imaging studies, and their importance stems from the fact that they should not be misinterpreted as fractures. Sometimes, however, these accessory bones and bone variants can be symptomatic, showing as fracture, degenerative changes, avascular necrosis or, occasionally, by partial disruption of their synchondrosis in response to chronic use, what results in altered movement, friction and the development of bone edema in the ossification. In this sense, the os styloideum and the lunula are the two ossicles more reported in the literature for their relevance or medical findings. Almost all the reports highlight the importance of MRI to evaluate an ossicle in symptomatic patients.

The os epilunatum is a rare accessory ossicle. There are scientific reports on their presence in corpses, but very few on their presentation in patients.

Descriptions define it as a cartilaginous nodule that shows at an early age and, in general, fuses with the distal corner of the lunate bone; sometimes, however, it remains separate and ossifies in that location. There are reports on its bi-laterality.

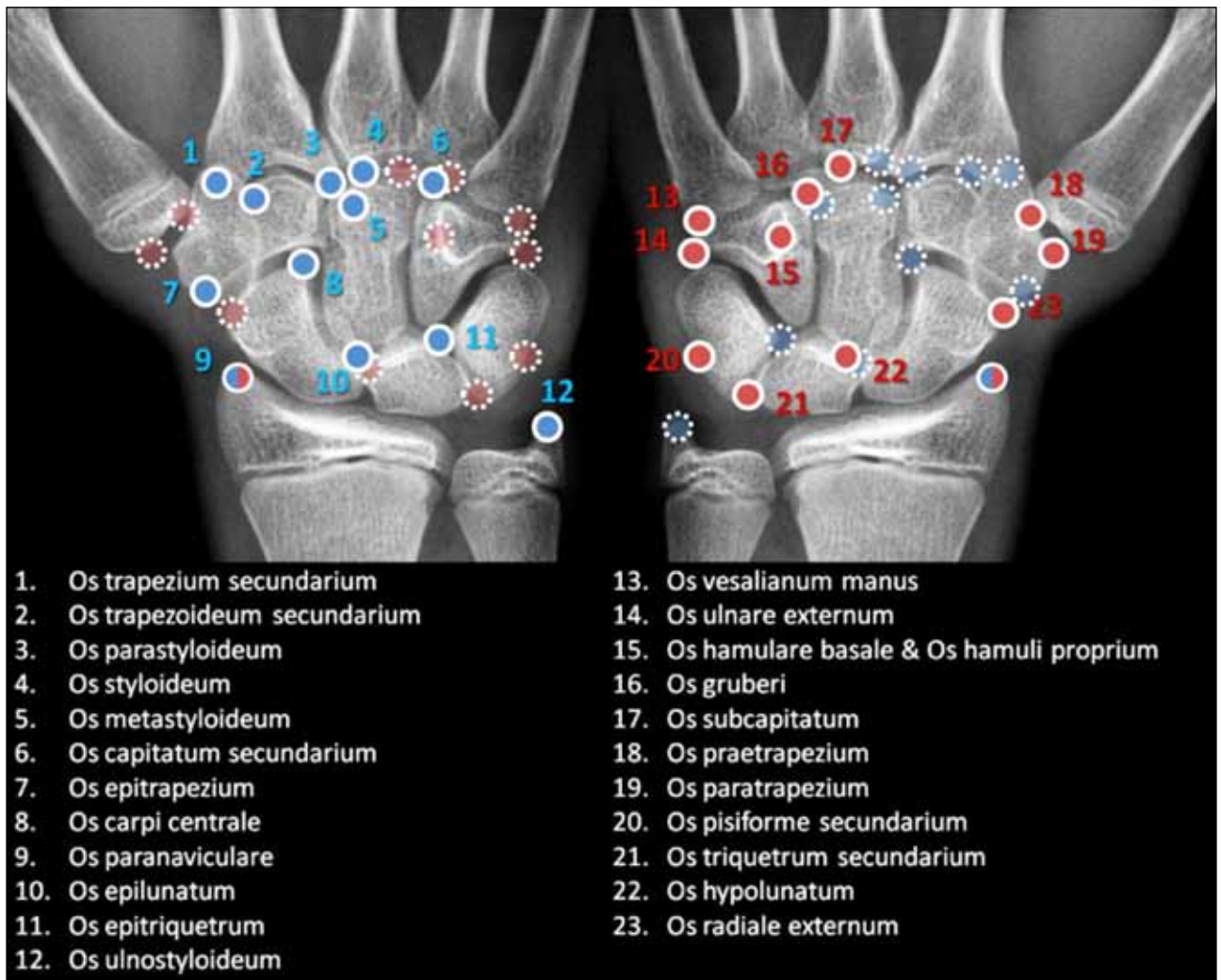
From the medical point of view, this accessory ossicle, as well as the other ones, can be traumatized and misinterpreted as fracture.

If it causes symptoms, the pain can be interpreted as a consequence of the partial tear of the scapho-lunate ligament, of synovitis, and of the inflammatory changes that surround the os epilunatum, mainly in the capsule and the fingers extensor tendons. However, the degenerative changes that come along can also cause pain.

Conclusions

Most accessory bones and skeletal variants in the body are usually asymptomatic incidental findings in imaging studies which should not be misinterpreted as fractures. However, they can also cause pain, especially in the wrist. In such cases, MRI is particularly useful to evaluate pain associated with the presence of ossicles, where the key finding is the bone marrow edema and the edema in the surrounding soft tissues.

The os epilunatum is an accessory ossicle in the body located on the back of the wrist, in the angle between the scaphoid, the lunate, and the capitate. The general incidence of ossicles in the wrist is low—is estimated to be around 1.6%. The presence of an os epilunatum is exceptional. The aim of this report is to highlight the fact that an accessory ossicle represents an important differential diagnosis in chronic wrist pain. According to different publications, sometimes the surgical resection of the accessory ossicle can relieve pain completely.



▲ **Figure 5.** Accessory ossicles in the wrist.