

Osteopetrosis: two case reports

Juan Carlos Caruso, Juan Martín Patiño

Hand Surgery Department, Hospital Militar Central "Cirujano Mayor Dr. Cosme Argerich" (Buenos Aires, Argentina)

ABSTRACT

Osteopetrosis, also known as Albers-Schönberg disease, is a disorder that is divided into four types and characterized by bone dysplasia and lack of bone resorption due to abnormal osteoclastic activity, resulting in the development of brittle and denser bone tissue that is prone to fractures that are difficult to treat surgically. On this paper, we discuss the cases of two patients with Osteopetrosis and humeral shaft fractures, both of whom received conservative management. The objectives of our paper are to discuss our experience in the management of these cases and to review the available literature. Conservative management provides the best outcome for humeral shaft fractures in patients with Osteopetrosis, given that bone quality in these patients excludes osteosynthesis. In addition, the use of implants may lead to complications such as infections, delayed fracture healing and pseudarthrosis, among others. Surgery should be reserved for certain patients, such as those with delayed fracture healing, pseudarthrosis, history of recurrent fractures, pre-existing fracture deformity, and those at risk of developing disabling deformities or that do not respond to conservative management.

Key words: Osteoclasts; humeral fracture; Osteopetrosis.

Level of Evidence: IV

Osteopetrosis. Presentación de dos casos

RESUMEN

Las osteopetrosis (enfermedad de Albers-Schönberg) comprende un síndrome con cuatro tipos clásicos e instituye una displasia ósea secundaria a la falta de resorción de hueso por anomalía de los osteoclastos, lo cual provoca un tejido óseo duro y quebradizo, propenso a fracturas difíciles de tratar quirúrgicamente. Se han publicado escasos artículos sobre el tema; por este motivo, decidimos presentar a dos pacientes con fracturas diafisarias de húmero con osteopetrosis, ambas tratadas en forma incruenta.

Los objetivos son comunicar nuestra experiencia y el método de tratamiento de dicha afección y realizar una revisión bibliográfica acerca del tema. Creemos que el tratamiento de elección para las fracturas diafisarias de húmero en pacientes con osteopetrosis es el incruento, ya que su tipo de tejido óseo dificulta la implementación de cualquier osteosíntesis. Además, la colocación de implantes puede provocar algunas complicaciones, como infecciones, retraso de la consolidación y pseudoartrosis. La cirugía se reserva para ciertos casos, como en pacientes con riesgo de desarrollar deformidades incapacitantes, aquellos que han sufrido fracturas repetidas, con retraso de la consolidación, pseudoartrosis, quienes no responden al tratamiento incruento o con una deformidad previa.

Palabras clave: Osteopetrosis; fractura de húmero; osteoclastos.

Nivel de Evidencia: IV

INTRODUCTION

Osteopetrosis, also known as Albers-Schönberg disease, is a syndrome with a wide range of variability and characterized by bone dysplasia caused by deficient resorption due to abnormal osteoclastic activity, resulting in the development of brittle and denser bone tissue, in short and broad bones, that is prone to fractures that are difficult to treat surgically.¹⁻⁴ There are four standard types of Osteopetrosis:

Received on June 24th, 2018. Accepted after evaluation on November 6th, 2018 • JUAN CARLOS CARUSO, MD • carusojc@hotmail.com 

How to cite this paper: Caruso JC, Patiño JM. Osteopetrosis: two case reports. *Rev Asoc Argent Ortop Traumatol* 2019;84(4):386-392. <http://dx.doi.org/10.15417/issn.1852-7434.2019.84.4.869>

1. Malignant, Infantile or Early Osteopetrosis (Osteopetrosis Congenita)
2. Benign Osteopetrosis (Osteopetrosis Tarda or Delayed Osteopetrosis)
3. Intermediate Osteopetrosis
4. Carbonic anhydrase deficiency (Osteopetrosis with renal tubule acidosis, cerebral calcification or Sly Disease).¹⁻⁴

In our literature research, we found few papers on Osteopetrosis; thus, we decided to report the cases of two patients with Osteopetrosis and humeral shaft fractures, both of whom received conservative management.

CLINICAL CASE 1

A 43-year-old female office worker who was polytraumatized in a high-energy motor vehicle accident: fracture of the middle third of the right humerus (Figure 1), femoral subtrochanteric fracture, right distal ulna and radius fracture, and multiple rib fractures. No nervous or vascular injury. No relevant family or personal history.

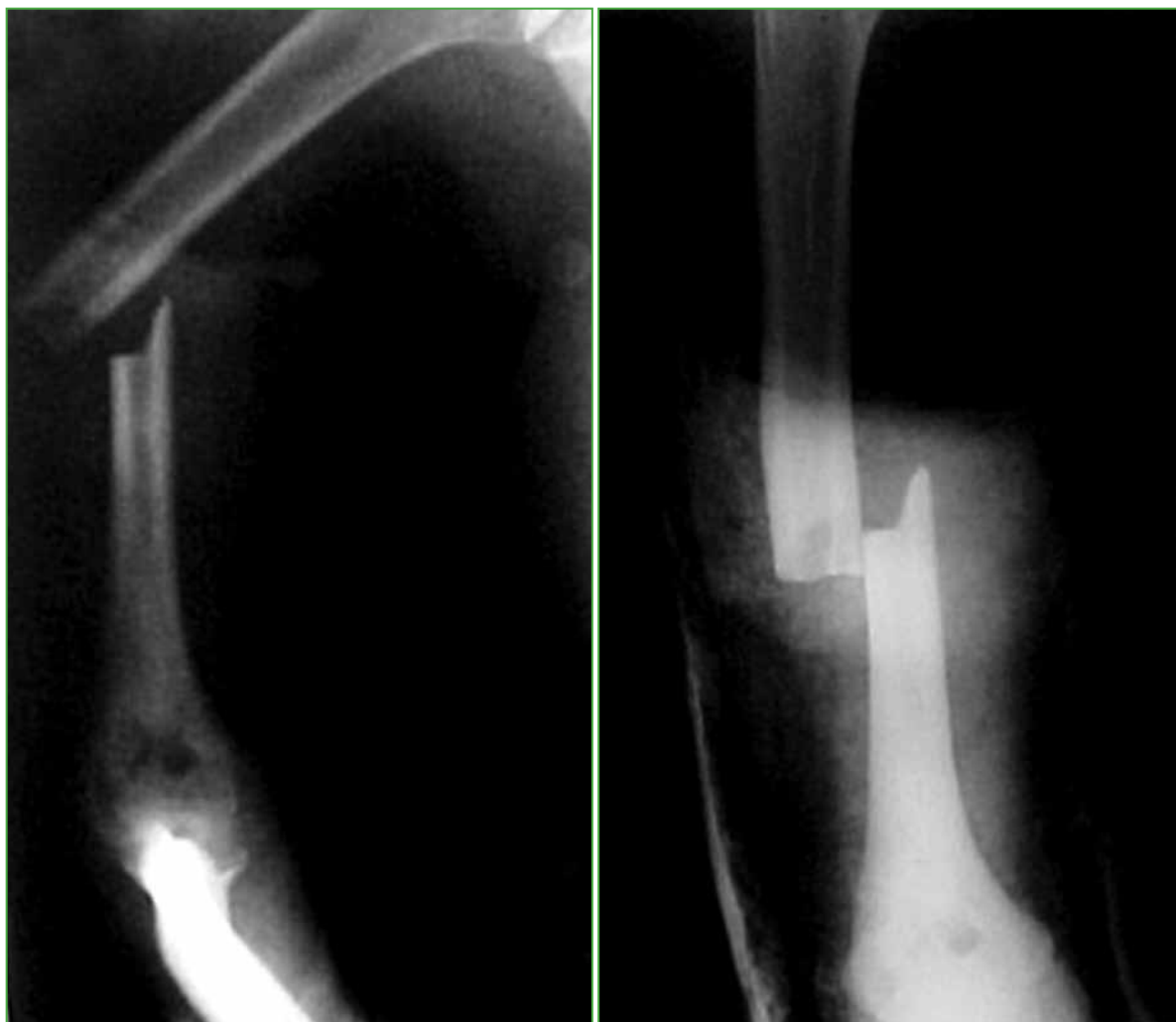

Figure 1. Right humeral shaft radiograph taken the day of the accident and showing a transverse fracture.

Osteopetrosis is suspected after attempting internal fixation, which could not be achieved due to cortical extreme hardness. Additionally, long bone medullary canal narrowing and cortical density and thickness increase were detected (Figure 2), and the skull radiographs revealed hyperdensity in the skull base bones (Figure 3). These findings, together with the anatomical pathology test results from specimens taken during the femur surgery, confirm the Osteopetrosis diagnosis. The patient was treated with a plaster cast covering the upper arm until radiographic bone healing was achieved (3 months) (Figures 4 and 5). Radiographic controls were performed at 1 week and 1, 3, 6, 9 and were 12 months. The UCLA shoulder score was 30, an excellent result. And the Mayo Clinic elbow score was 100, which revealed only a 5° extension loss.

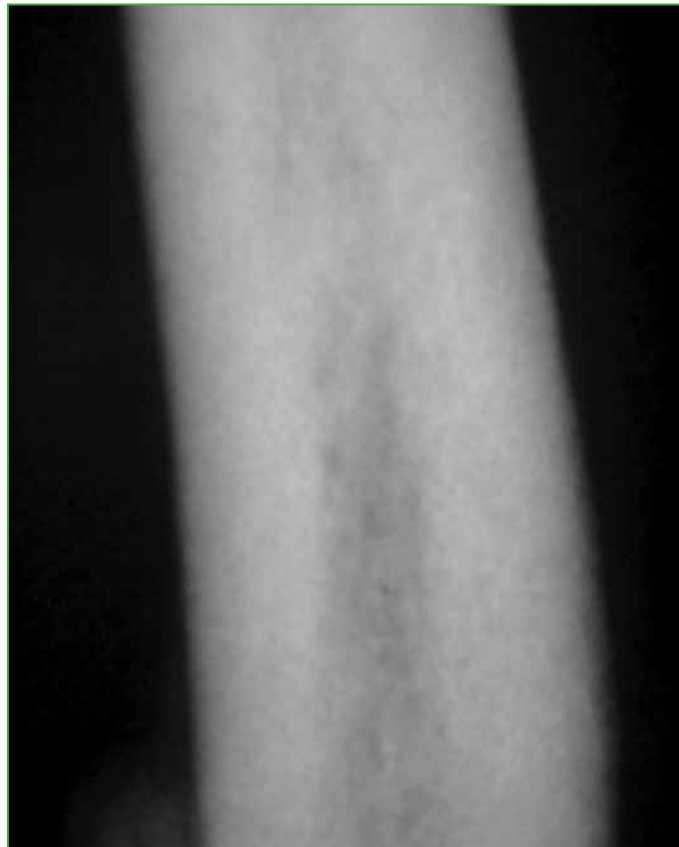


Figure 2. Right humeral shaft radiograph taken the day of the accident showing an increased cortical thickness.

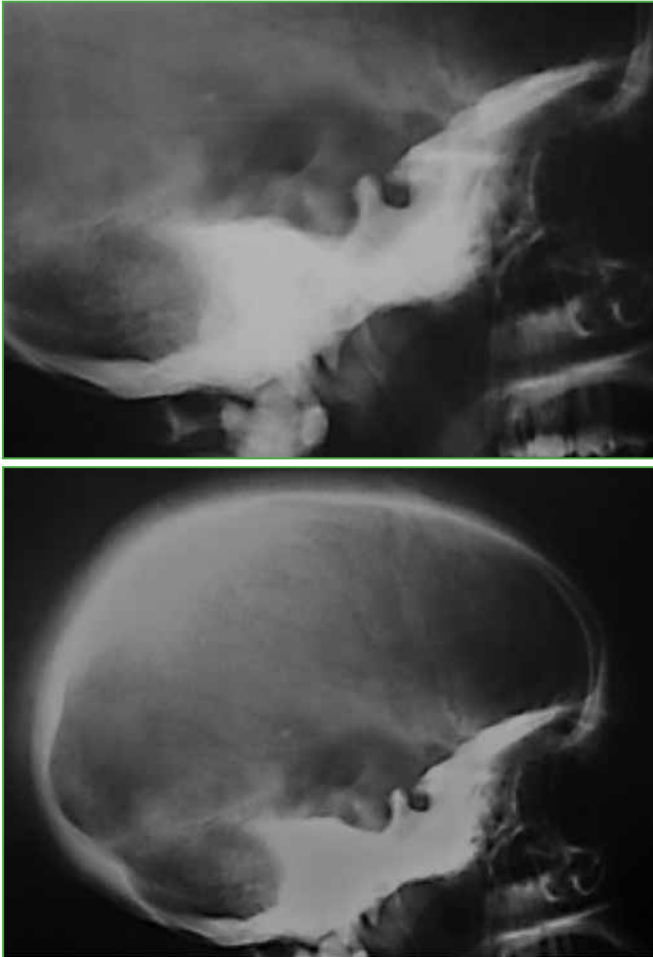

Figure 3. Lateral skull radiographs showing hyperdensity of skull base bones.

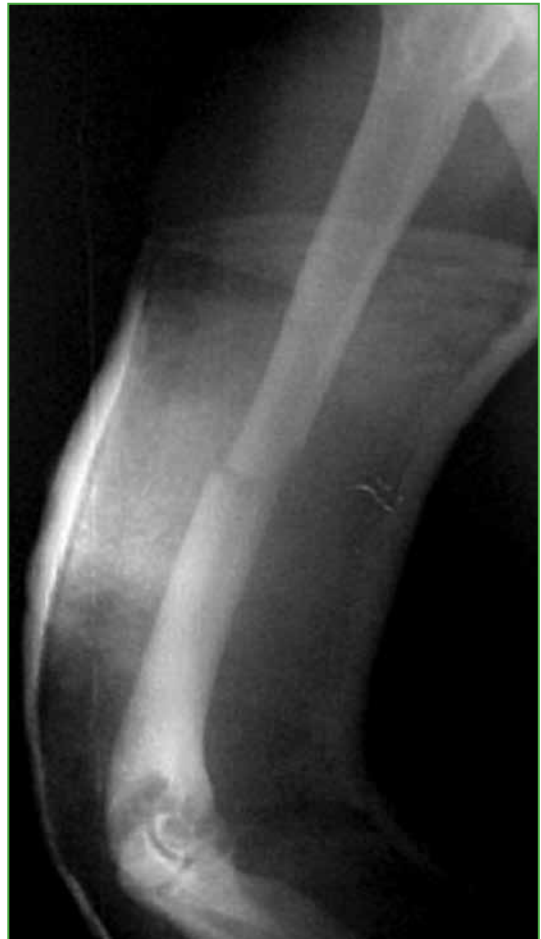

Figure 4. Right humeral shaft radiograph taken after fracture reduction.

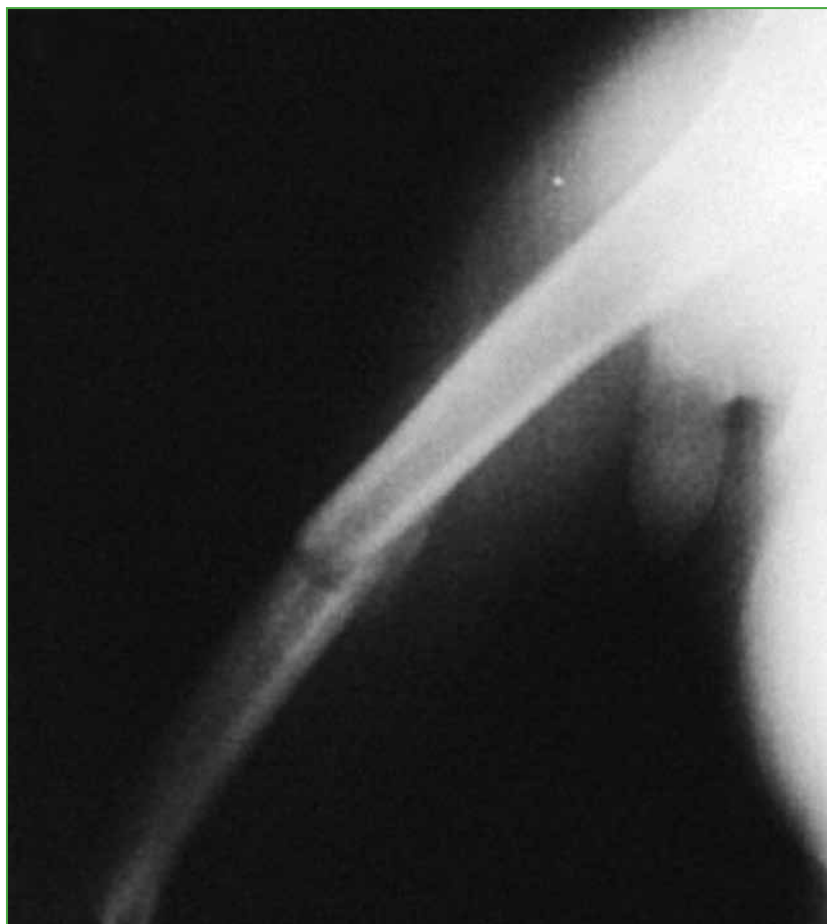


Figure 5. Right humeral shaft radiograph taken after bone union.

CLINICAL CASE 2

A 28-year-old male that sustained a fall injury when he fell on his arm while horse riding. Radiographic examination revealed medio-diaphyseal transverse fracture of the right humerus (Figure 6), with no associated neurovascular involvement. He was otherwise healthy and had no relevant family history. As in the other case, medullary canal narrowing and cortical density, skull base sclerosis, and the same radiological manifestations led to the clinical suspicion of Osteopetrosis. The patient obtained bone union with axial alignment at 3 months using a plaster cast (Figure 7) and returned to his daily activities. The follow-up was the same as in the other case. The UCLA score was 30, an excellent result. However, although the Mayo Clinic score was 100, the evaluation of this patient revealed a 10° extension loss.

DISCUSSION

The objectives of our paper are to share our experience in the management of these cases and to review the available literature.

The number of published case series devoted to the management of humeral fractures in patients with Osteopetrosis is limited and even lower for those which address its conservative treatment.

Since first described in 1904, few cases have been reported in the world literature (approximately 300 cases) and most of them are pediatric cases; however, few publications offer information on the management of these patients.

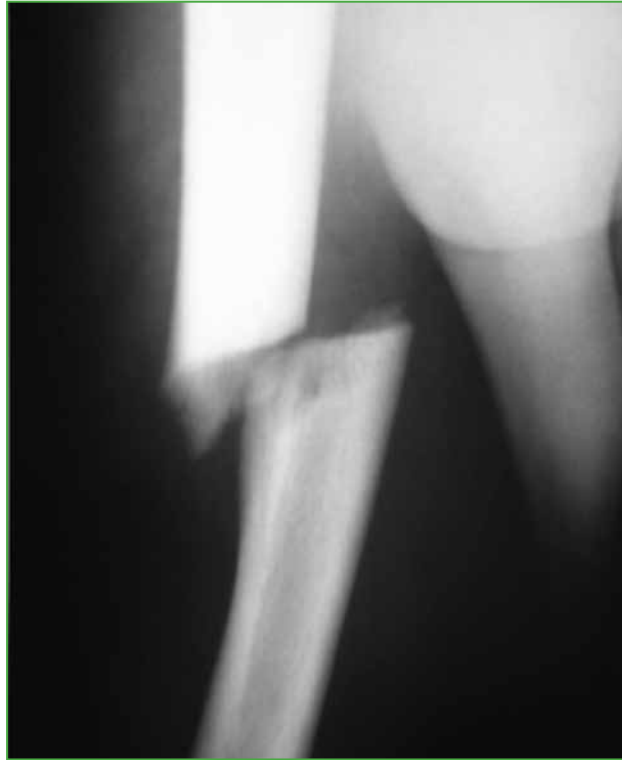


Figure 6. Right humeral shaft radiograph taken the day of the accident showing a transverse fracture.

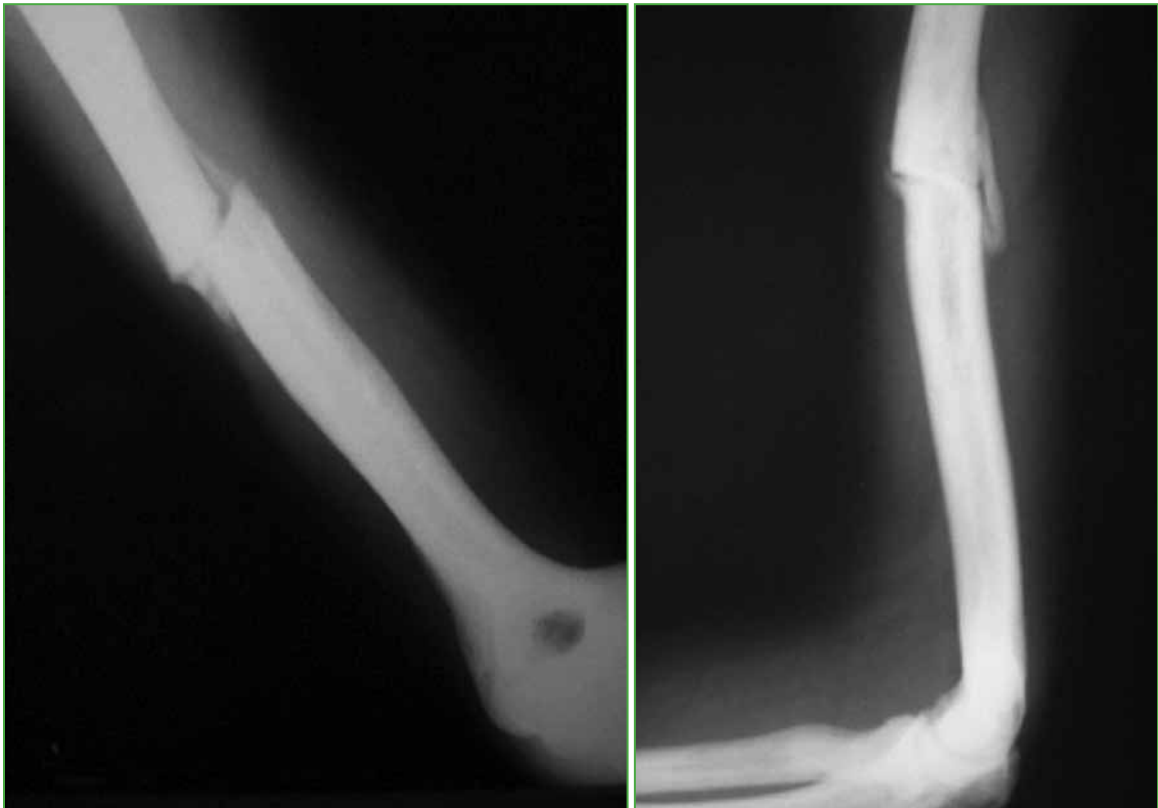


Figure 7. Radiographs taken at the end of the treatment period. Fracture healing was achieved.

The previously mentioned cases belong to the benign or autosomal dominant category which takes place in adulthood. These patients, unlike those suffering from the malignant autosomal recessive form, enjoy a normal life; their condition is diagnosed after sustaining a long bone fracture, usually transverse, as a result of minor trauma.

In their literature review, Armstrong *et al.*⁵ describe the management of three patients with four humerus fractures, three of which were non-operatively treated; although these were pediatric cases. Armstrong *et al.* multi-center study included 72 patients (age range from 6 weeks to 50 years) and had the following findings in relation to humerus fractures: a patient with Malignant Osteopetrosis had a delayed fracture healing despite being 6 weeks old; another patient with a bilateral fracture required open reduction and internal fixation of one humerus and obtained bone healing of the contralateral humerus after four months of orthopedic treatment; the third patient was a teenager with a pathologic fracture at the biopsy site, which healed with conservative management.

Some authors, such as Bhargava³, consider casting a current successful treatment for most upper extremity fractures in patients with Osteopetrosis.

In turn, Rafiq *et al.*⁴ published the case of a 48-year-old patient with a non-united fracture of the humerus which was initially managed conservatively for 3 months. The authors addressed this complication by using a rigid plate fixation (screw plate fixation) and bone healing was obtained after 3 months.

If it is decided to operate, screw plate fixation is a viable option, especially for adult patients; however, this is not the case for children in whom the use of an intramedullary nail is recommended due to their wider medullary canal diameter.^{3,5}

Operative fixations benefit from the change of drill bits and the cooling of the cortical bone while drilling, which helps to prevent bone necrosis and subsequent implant loosening and infection. Any use of mallet risks a secondary bone rupture, in which case intramedullary nailing remains the standard treatment.³

Conservative management provides the best outcome for humeral shaft fractures in patients with Osteopetrosis, given the very many related reports in the literature agree that bone quality in these patients hinders osteosynthesis. In addition, the use of implants may lead to complications such as infections, delayed fracture healing and pseudarthrosis, among others. Surgery should be reserved for certain patients, such as those with delayed fracture healing, pseudarthrosis, history of recurrent fractures, pre-existing fracture deformity, and those at risk of developing disabling deformities or that do not respond to conservative management.^{2,4}

Conflict of interest: Authors claim they do not have any conflict of interest.

J. M. Patiño ORCID ID: <http://orcid.org/0000-0002-9036-0442>

REFERENCES

1. Granados Sandoval E, Martínez Estrada JG, Zepeda Cianca R, Trejo Pimentel A, Sandoval González C, Barrón JC. Osteopetrosis (enfermedad de Albers-Schonberg): reporte de un caso y revisión clínica. *Med Int Mex* 2007;23(6):542-5. <https://www.medigraphic.com/cgi-bin/new/resumen>
2. Landa J, Di Cesare N. Orthopaedic management of the patient with osteopetrosis. *J Am Acad Orthop Surg* 2007;15:654-62. <https://doi.org/10.5435/00124635-200711000-00004>
3. Bhargava A, Vagela M, Lennox CME. Challenges in the management of fractures in osteopetrosis. Review of literature and technical tips learned from long-term management of seven patients. *Injury* 2009;40:1167-71. <https://doi.org/10.1016/j.injury.2009.02.009>
4. Rafiq I, Kapoor1 A, Burton DJC, Haines JF. A new modality of treatment for non-united fracture of the humerus in a patient with osteopetrosis: a case report. *J Med Case Reports* 2009;3:15. <https://doi.org/10.1186/1752-1947-3-15>
5. Armstrong DG, Newfield JT, Gillespie R. Orthopedic management of osteopetrosis: results of a survey and review of the literature. *J Pediatr Orthop* 1999;19(1):122-32. PMID: 9890301