

Total hip arthroplasty in a patient with ipsilateral transfemoral amputation

Edgar G. Wagner, Reynaldo Quiroga

Orthopedics Department, Hospital Regional de Comodoro Rivadavia (Chubut, Argentina)

ABSTRACT

Hip fractures in patients with ipsilateral limb amputations are uncommon injuries that pose a challenge for orthopedic surgeons. In this article, we present our experience in the treatment of a 63-year man with left transfemoral amputation, who suffered a left femoral neck fracture after a fall from standing height. Proper placement of the prosthesis is essential to achieve good postoperative clinical outcomes. A Steinmann pin was inserted into the greater trochanter to facilitate exposure and component placement. No clinical or radiological complications were detected in a 15-month follow-up. We believe that the correct placement of a Steinmann pin is a good alternative that provides adequate control over the extremity when performing an arthroplasty, thus reducing the risks for prosthesis displacement and shortening the surgical time.

Key words: Hip replacement; ipsilateral transfemoral amputation; total hip arthroplasty.

Level of Evidence: IV

Reemplazo total de cadera en un paciente con amputación supracondílea homolateral

RESUMEN

La fractura de cadera en pacientes con amputación del miembro homolateral son lesiones infrecuentes que representan un reto para el cirujano ortopédico. Presentamos el caso de un hombre de 63 años con amputación supracondílea izquierda, que sufre una fractura del cuello femoral izquierdo por caída de su propia altura. La colocación apropiada del implante es esencial para obtener buenos resultados clínicos posoperatorios. Para la exposición y la colocación del implante se utilizó un clavo de Steinmann en el trocánter mayor. No se observaron complicaciones clínicas ni radiográficas en un seguimiento de 15 meses. Creemos que el empleo del clavo de Steinmann colocado en correcta posición es una buena alternativa por considerar para poder controlar el miembro al realizar una artroplastia y así disminuir los riesgos de colocar la prótesis en mala posición y el tiempo quirúrgico.

Palabras clave: Artroplastia de cadera; amputación supracondílea homolateral; reemplazo total de cadera.

Nivel de Evidencia: IV


INTRODUCTION

Hip fractures are a common source of morbidity and mortality worldwide. Nevertheless, the discovery and development of hip arthroplasty have improved patients' prognosis, with a high survival rate, and satisfactory functional outcomes.¹⁻⁷

Although hip replacement in otherwise healthy patients has been well described in the literature, our literature review produced little information on hip replacement in patients with ipsilateral limb amputations.¹⁻⁷

With regard to patients with transfemoral amputations, the rate of ipsilateral hip fracture has risen due to reduced bone mineral density, especially in patients with artificial limbs.⁶

Hip fractures in patients with ipsilateral limb amputations are uncommon injuries that pose a challenge for orthopedic surgeons as a consequence of the patients' characteristics, technical difficulties concerning treatment, the surgical approach and the stump manipulation.^{2,4,7}

Received on February 16th, 2019. Accepted after evaluation on April 8th, 2019 • E. G. WAGNER, MD • edgar.gw@hotmail.com 

How to cite this paper: Wagner EG, Quiroga R. Total hip arthroplasty in a patient with ipsilateral transfemoral amputation. *Rev Asoc Argent Ortop Traumatol* 2020;85(2):151-156. <http://dx.doi.org/10.15417/issn.1852-7434.2020.85.2.964>

We report a peculiar case of femoral neck fracture in a patient with an ipsilateral transfemoral amputation and a 1-year evolution, who underwent total hip arthroplasty (THA) as a primary treatment.

CLINICAL CASE REPORT

A 63-year man, under treatment for diabetes and hypertension, with left transfemoral amputation and 1-year evolution, presented to the Hospital Emergency Room after sustaining a hip trauma from a standing-height fall. He was diagnosed with a grade II femoral neck fracture, according to Garden's classification ([Figure 1](#)).

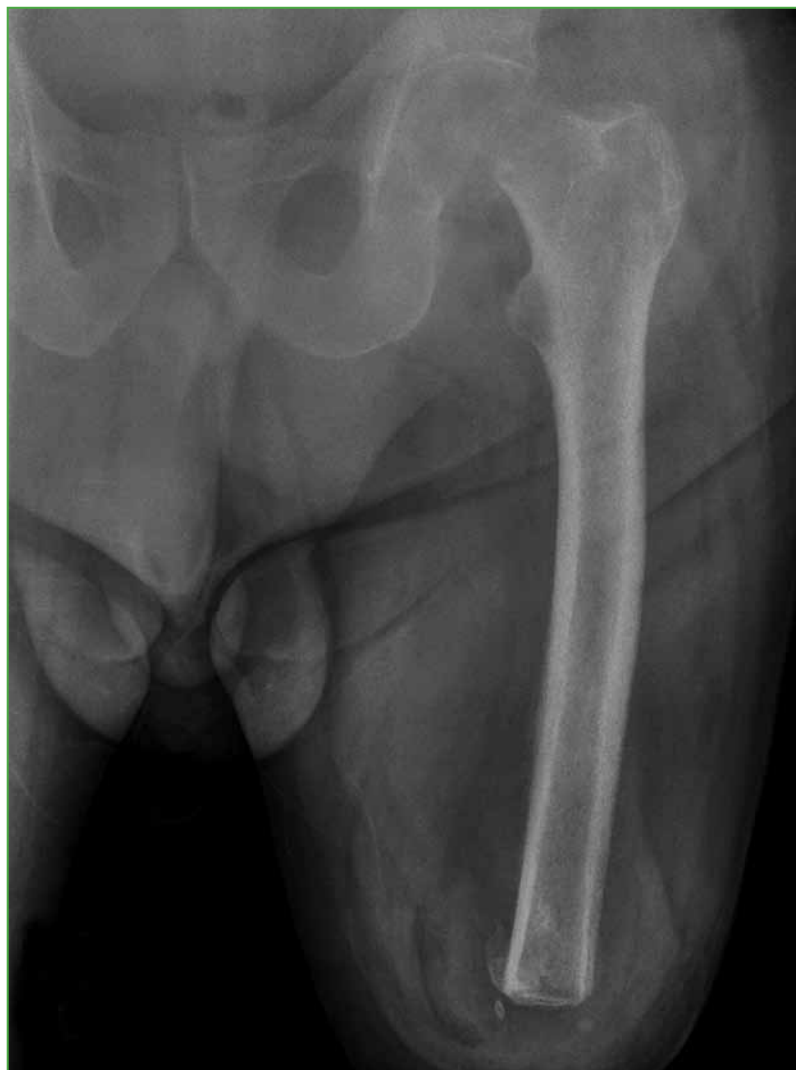

Figure 1. Preoperative left hip anteroposterior X-ray. Image reveals a non-displaced femoral neck fracture.

Under spinal anesthesia, the patient was placed in the right lateral decubitus position. The patient underwent a cemented THA with a modified Gibson approach. A Steinmann pin was inserted at the greater trochanter to facilitate dislocation/relocation and to control the stump rotation. THA included a Charnley-type femoral component with a 28mm head and a Muller acetabular cup (28mm × 42mm) (Figure 2). Postoperative management included antibiotic prophylaxis for 48 hours and antithrombotic therapy for 15 days to prevent thromboembolic and infectious complications.

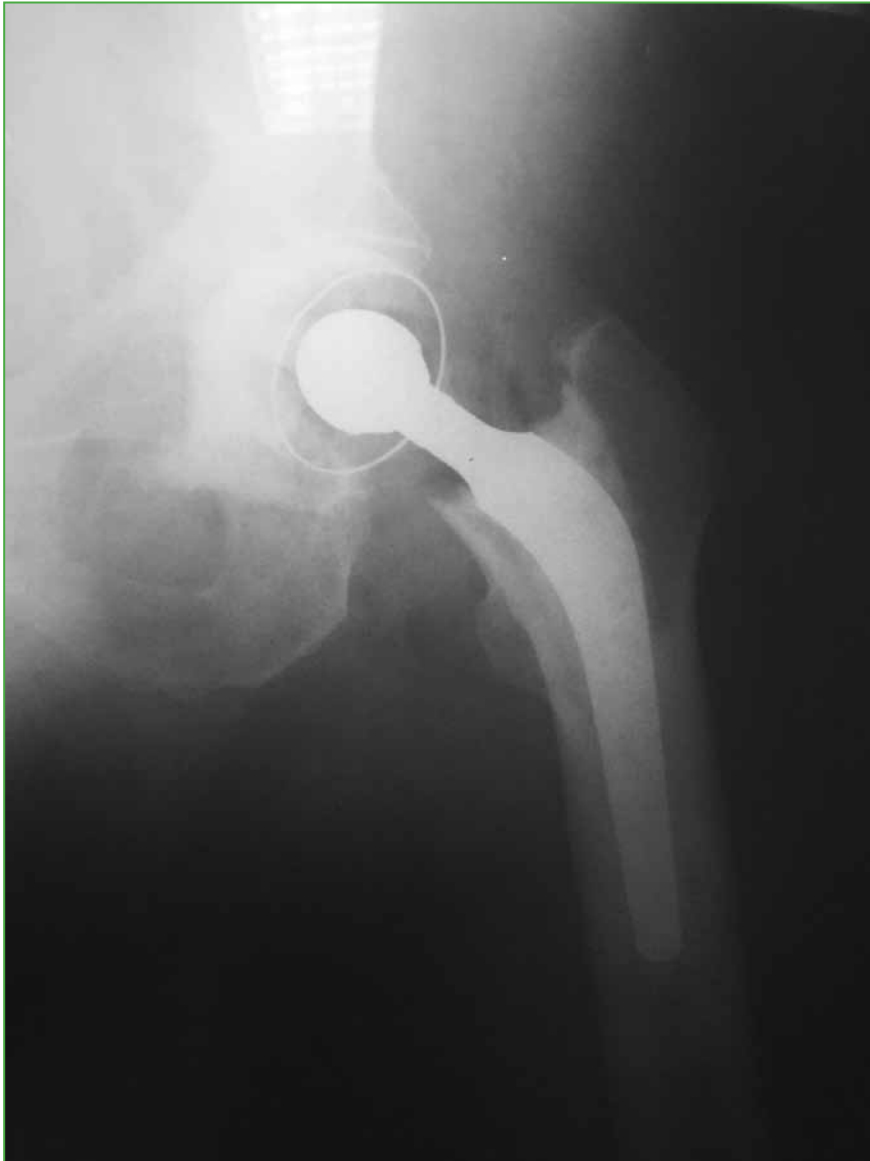

Figure 2. Postoperative anteroposterior X-ray revealing a satisfactory outcome.

The patient suffered no complications and was allowed weight-bearing using his artificial leg, and progressive ambulation with crutches on the third postoperative day.

A 15-month follow-up revealed no prosthesis dislocation or infectious complications. The surgical wound was completely healed and dry. The patient had a satisfactory hip range of motion: flexion was 85°, external and internal rotation was 30°, abduction was 40°, and adduction was 20°. The patient was painless, able to walk with a cane and to independently perform his activities of daily living, using his artificial leg (Figure 3).

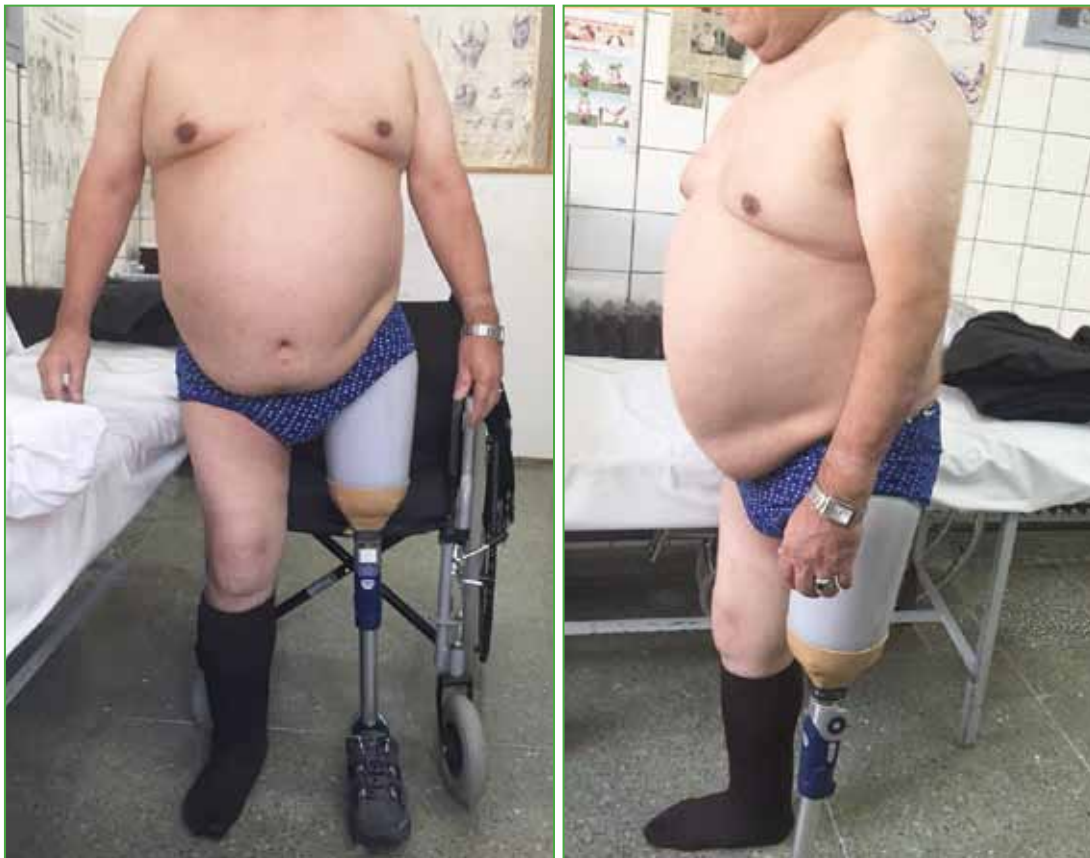

Figure 3. Patient at 15-month postoperative follow-up.

Hip anteroposterior X-ray did not revealed any signs of component migration or prosthesis loosening.

DISCUSSION

THA is the most frequently used procedure for femoral neck fractures, especially in the adult population. This condition has a high morbidity and mortality rate worldwide. However, arthroplasty has changed the prognosis of the femoral neck fracture.^{1,2}

Femoral neck fractures in lower extremities with transfemoral amputations are uncommon injuries and there are few publications regarding this condition.¹ THA after an ipsilateral amputation represents 0.067% of all THAs.⁴

Limb amputations may induce osteo-articular and muscular modifications both in the affected and in the contralateral limb.^{2,3}

- Increase in the femorotibial and the femoropatellar osteoarthritis on the un-amputated side.
- Increase in osteoporosis on the amputated side.
- Amyotrophy on both amputated and un-amputated side, resulting from the anatomical consequences of the surgical act and the loss of the muscle's insertions or their re-implantation into a non-physiological site.

Some studies have proved that lower extremity amputees have a higher risk of sustaining an ipsilateral hip fracture due to their higher rate of osteoporosis as well as the lever arm carried by the prosthesis.¹⁻⁴

Although there is little information on the treatment of these fractures in patients with ipsilateral transfemoral amputation and although THA yields good postoperative outcomes, fixation with three 7.5mm cannulated screws may also be a reasonable treatment option.⁶

Proper placement of the prosthesis is essential to achieve good postoperative clinical outcomes following a hip arthroplasty. Exposure and implant positioning can be challenging procedures in transfemoral amputees.^{3,4} Inserting a Steinmann pin into the greater trochanter is a good technique that allows for an adequate rotation control and the required stump traction to properly place the prosthesis.⁷

Some authors^{1,2,4,6} have described other useful techniques for the adequate manipulation of the stump, such as using a bone forceps, bone clamping, inserting a Schanz pin in the anteroposterior direction at the level of the lesser trochanter, and inserting a transfemoral Steinmann pin.

The surgical act posed a considerable challenge regarding patient positioning and stump manipulation. Certain factors were taken into consideration: surgical time, surgical approach allowing better exposure, and risk of fracture related to osteoporosis.¹ The modified Gibson approach was used as it allows for an easy and atraumatic dissection that shortens the surgical time and reduces blood loss, provides excellent exposure for the preparation and placement of both components, and enables soft tissue reconstruction, which optimizes rehabilitation.⁸ We chose a cemented arthroplasty because it involves a lower loosening risk in the osteoporotic bone.¹

CONCLUSIONS

The authors present this case because of the low rate of femoral neck fractures in patients with ipsilateral transfemoral amputations and the little information available on its management. This surgical approach combined with the insertion of a Steinmann pin for stump manipulation shortened the surgical time and achieved a good postoperative outcome allowing the patient to return to his daily activities.

We conclude that THA is an excellent treatment choice for this type of fractures because, unlike internal fixation, it allows for a better rehabilitation with full weight-bearing and early ambulation even for non-displaced fractures.

Conflict of interests: Authors claim they do not have any conflict of interests.

R. Quiroga ORCID ID: <https://orcid.org/0000-0001-8552-9445>

REFERENCES

1. Boussakri H, et al. Hip arthroplasty in a patient with transfemoral amputation: a new tip. *Case Rep Orthop* 2015; 2015: 593747. <https://doi.org/10.1015/2015/593747>
2. Masmoudi K, Rbai H, Fradj AB, Saâdena J, Boughattas A. Primary total hip replacement for a femoral neck fracture in a below-knee amputee. *J Orthop Case Rep* 2016;6(3):63-6. <https://doi.org/10.13107/jocr.2250-0685.510>
3. Pekmezci M, Nunley RM, Barrack RL. Technique for total hip arthroplasty in a patient with through-knee amputation. *J Arthroplasty* 2010;25(4):659.e1-3. <https://doi.org/10.1016/j.arth.2009.03.011>
4. Amanatullah DF, Trousdale RT, Sierra RH. Total hip arthroplasty after lower extremity amputation. *Orthopedics* 2015;38(5):e394-400. <https://doi.org/10.3928/01477447-20150504-56>
5. Nejat EJ, Meyer A, Sánchez PM, Schaefer SH, Westrich GH. Total hip arthroplasty and rehabilitation in ambulatory lower extremity amputees--a case series. *Iowa Orthop J* 2005;25:38-41. PMID: 16089069
6. Freitas A, Souto DRM, da Silva JF, Dantas BR, de Paula AP. Treatment of an acute fracture of the femoral neck in a young female adult with a transfemoral amputation: a case report. *JBJS Case Connect* 2015;5(3):e58. <https://doi.org/10.2106/JBJS.CC.N.00119>
7. Ma C, Lv Q, Yi C, Ma J, Zhu L. Ipsilateral total hip arthroplasty in patient with an above-knee amputee for femoral neck fracture: a case report. *Int J Clin Exp Med* 2015;8(2):2279-83. <https://doi.org/10.19001/IJCEM0004117>
8. Varela-Egocheaga JR, Suárez-Suárez MA, Álvarez-Vega MA, Álvarez-Rico ME, Ferrero-Manzanal F, Montero-Díaz M, et al. Abordaje posterior vs lateral en artroplastia total de cadera. Estudio prospectivo, aleatorio y ciego. *Revista Española de Cirugía Osteoarticular* 2005;40(223):126-33. http://www.cirugia-ostearticular.org/adaptingsystem/intercambio/revistas/articulos/161_126.pdf